This is a digital copy of a book that was preserved for generations on library shelves before it was carefully scanned by Google as part of a project to make the world's books discoverable online.

It has survived long enough for the copyright to expire and the book to enter the public domain. A public domain book is one that was never subject to copyright or whose legal copyright term has expired. Whether a book is in the public domain may vary country to country. Public domain books are our gateways to the past, representing a wealth of history, culture and knowledge that's often difficult to discover.

Marks, notations and other marginalia present in the original volume will appear in this file - a reminder of this book's long journey from the publisher to a library and finally to you.

Usage guidelines

Google is proud to partner with libraries to digitize public domain materials and make them widely accessible. Public domain books belong to the public and we are merely their custodians. Nevertheless, this work is expensive, so in order to keep providing this resource, we have taken steps to prevent abuse by commercial parties, including placing technical restrictions on automated querying.

We also ask that you:

+ *Make non-commercial use of the files* We designed Google Book Search for use by individuals, and we request that you use these files for personal, non-commercial purposes.

+ *Refrain from automated querying* Do not send automated queries of any sort to Google's system: If you are conducting research on machine translation, optical character recognition or other areas where access to a large amount of text is helpful, please contact us. We encourage the use of public domain materials for these purposes and may be able to help.

+ *Maintain attribution* The Google "watermark" you see on each file is essential for informing people about this project and helping them find additional materials through Google Book Search. Please do not remove it.

+ *Keep it legal* Whatever your use, remember that you are responsible for ensuring that what you are doing is legal. Do not assume that just because we believe a book is in the public domain for users in the United States, that the work is also in the public domain for users in other countries. Whether a book is still in copyright varies from country to country, and we can't offer guidance on whether any specific use of any specific book is allowed. Please do not assume that a book's appearance in Google Book Search means it can be used in any manner anywhere in the world. Copyright infringement liability can be quite severe.

About Google Book Search

Google's mission is to organize the world's information and to make it universally accessible and useful. Google Book Search helps readers discover the world's books while helping authors and publishers reach new audiences. You can search through the full text of this book on the web at `http://books.google.com/`

9.A.136.1

HARVARD UNIVERSITY MEDICAL SCHOOL.

LIBRARY

OF THE

PATHOLOGICAL LABORATORY.

The Gift of A. H. Fitz, M.D.

60/3B
8A

Digitized by Google

Digitized by Google

Digitized by Google

PROCEEDINGS

OF THE

PATHOLOGICAL SOCIETY

OF

PHILADELPHIA.

VOL. I.

PHILADELPHIA:
J. B. LIPPINCOTT & CO.
1860.

Digitized by Google

HARVARD UNIVERSITY
SCHOOL OF MEDICINE AND PUBLIC HEALTH
LIBRARY
8.A.1860.1

8.A.1860.1

Digitized by Google

A LIST

OF THE

MEMBERS OF THE PATHOLOGICAL SOCIETY

UP TO MAY 24, 1860.

RESIDENT MEMBERS.

D. H. Agnew.
C. S. Boker.
Jno. H. Brinton.
J. M. Da Costa.
Jno. T. Darby.
Jas. Darrach.
Emil Fischer.
Wm. S. Forbes.
S. D. Gross.
S. W. Gross.
A. D. Hall.
G. C. Harlan.
R. P. Harris.
Edward Hartshorne.
Henry Hartshorne.
Addinell Hewson.
H. Lenox Hodge.
Wm. D. Hoyt.
Geo. H. Humphreys.
Jas. Hutchinson.
John K. Kane.
Wm. V. Keating.
Wm. Keller.
René La Roche.
Jas. J. Levick.
Samuel Lewis.
E. Livezey.
J. F. Meigs.
S. W. Mitchell.
Geo. R. Morehouse.
T. G. Morton.
Wm. Moss.
Jno. H. Packard.
R. A. F. Penrose.
Th. B. Reed.
Albert H. Smith.
Francis G. Smith.
Alfred Stillé.
Elwood Wilson.
J. J. Woodward.

CORRESPONDING MEMBERS.

Alonzo Clark.....New York.
Jno. C. Dalton.....New York.
Austin Flint.....New Orleans.
Wm. A. Hammond.....Baltimore.
Charles E. Isaacs.....Brooklyn.
Wm. King.....U. S. N.
James E. Reeves.....Fairmount, Va.
T. G. Richardson.....New Orleans.
Jno. Watson.....New York.
Wilmer Worthington.....West Chester, Pa.

Digitized by Google

Digitized by Google

PROCEEDINGS

OF THE

PATHOLOGICAL SOCIETY

OF

PHILADELPHIA.

HOSPITAL BUILDING, Spruce Street, above Eighth.

THE Pathological Society of Philadelphia was organized on Wednesday evening, October 14th, 1857, by the adoption of a Constitution and election of the following officers:—

President,	DR. GROSS.
Vice-Presidents,	DRS. LA ROCHE AND STILLÉ.
Treasurer,	DR. ADDINELL HEWSON.
Secretary,	DR. DA COSTA.
Assistant-Secretary,	DR. T. G. MORTON.

The Society then proceeded to the exhibition of specimens.

Fatty Degeneration of the Liver.—DR. S. W. MITCHELL exhibited a liver in a state of fatty degeneration, removed from a child, aged five and a half years, born in Georgia. The father died of phthisis, the mother is now ill with it; the boy had had repeated attacks of diarrhœa. His final illness began with vomiting and purging, easily subdued by medicine, but recurring with typhoidal symptoms after six days. A slight convulsion preceded his death by a few hours. The chief point in regard to his constitution which seemed worthy of note, was the facility with which the slightest catarrh prostrated and reduced him. This was explained after death by the presence of disease of the lung.

Digitized by Google

Post-mortem Section.—External appearance very thin. Brain healthy. Lungs; the right at the apex presented two or three small tubercular masses of the size of large peas. The intestines were generally congested, but offered no evidence of inflammation. The glands of Peyer were healthy, as well as those of the mesentery. The stomach about the greater curve was altered by chronic inflammation. The kidneys were healthy except at the lower ends of the renal tubes, whose cavities were very generally filled up by masses of yellow matter, which tinted the divided cones of a golden color. The liver was more yellow throughout than is usual, and exhibited everywhere to the microscope the evidence of an unhealthy excess of fat. On the upper surface the fat presented itself in very distinct cresentic markings, which offered a very curious contrast to the hue of the more healthy tissue about them.

In this case fatty degeneration of the liver preceded the general development of pulmonory tubercle.

Dr. Mitchell was requested to report further on the nature of the yellow matter in the uriniferous tubes.

WEDNESDAY EVENING, Oct. 28th, 1857.

The President in the chair.

DR. MITCHELL submitted the following report regarding the kidneys presented at the last meeting:—

"The kidneys are healthy as to tissue, but the lower end of most of the tubes is filled with dark masses which tint the renal cones of a golden yellow. Under the microscope these masses are observed to be rounded, and acicularly crystallized, the needle-like composite crystals radiating from the centre of each mass. The arrangement is common to crystalline masses of certain urates, rarely to phosphate and oxalate of lime, and always to carbonate of lime. To my great surprise I found these masses to be the last-named substance,—a fact as to which I was so skeptical that I examined them repeatedly, and with great care. By scraping several cones with a knife, I collected enough for micro-chemical analysis. The acicular and radiated structure came out as they dissolved in acetic acid, which they did easily, with development of bubbles of gas. After complete dissolution, the addition of a drop of oxalic acid in solution produced a white precipitate. From these reactions several times observed, as well as from their general form, I therefore conclude the masses to be carbonate of lime. The smaller crystals higher up in the tubes were yellow and transparent, and were probably uric acid, although their amount was too small to admit of even micro-chemical research. The occurrence of carbonate of lime in human urine is very rare. It can only take place in a neutral or alkaline secretion. I have notes of a case from Wilmington, Del., which I saw two years ago. The

Digitized by Google

patient was a retired merchant, who suffered with dyspepsia of an irritative nature. The deposition of the carbonate was in the form of amorphous masses, and a few such crystalline radiated forms as are seen in the case before us. In another instance the urine of a hysterical woman was loaded with quantities of pulverized chalk, placed in it to deceive the attending physician."

In answer to a question whether the urine had been examined during life, Dr. Mitchell stated that it had, but that it had presented nothing remarkable.

Fistula of the Gall-bladder.—DR. MORTON exhibited a specimen of fistula of the gall-bladder, taken from a female aged sixty-five, who died from diarrhœa; she had been subject to attacks of jaundice, accompanied with great pain in the region of the liver for many months. In July, 1857, she noticed a tumor over the region of the liver, which continued to increase, and finally opened, in the month of August, and discharged a considerable quantity of fluid. The opening was near the twelfth rib, about four inches from the median line; the discharge continued from the fistulous orifice until her death.

Atrophy.—The liver was much increased in size, of a bright yellow color, and fatty. The gall-bladder was firmly attached to the walls of the abdomen; on opening it a fistulous orifice was found leading from the gall-bladder through the parietes of the abdomen, and opening at the point above mentioned. The walls of the bladder were much increased in thickness; numerous gall-stones completely blocked it up, obstructing also the cystic duct; no gall-stones were observed in the discharge which came from the fistulous opening. The body was much jaundiced.

DR. STILLÉ remarked that he was at a loss to understand why jaundice was present in the case, as only the cystic duct was closed; he did not consider the fatty degeneration as sufficient to account for it. With regard to the evidently fatty state of the liver, he wished to draw attention to the distinction between fatty deposit and fatty degeneration.

DR. KEATING alluded to several cases of fatty degeneration accompanied by jaundice.—A discussion took place about fatty degeneration and fatty deposit, as also whether a fatty state of liver might be produced by the administration of cod-liver oil.

DR. LEVICK did not understand how this could occur, as a fatty degeneration was always accompanied by a lowering of the system or part involved, which cod-liver oil would be more likely to remedy.

DR. DA COSTA remarked, that to tell whether oil-globules in the liver, deposited as they are in the secreting cells, were the result of a deposit or fatty degeneration, would be impossible. With regard to the fistula in

Digitized by Google

the gall-bladder in the specimen before them, he pointed to the fact that in nearly all the reported cases of fistula of the gall-bladder, numerous gall-stones, and generally large ones, had been found, and these were probably the cause of the perforation.

DR. MITCHELL stated that the gall-stones in this case consisted mainly of cholesterine.

DR. GROSS remarked that some time since he had attended a female from whom a number of gall-stones escaped externally. The fistulous opening was five inches from the median line, on a level with the umbilicus. She recovered without any unfavorable symptoms. She had not been jaundiced, nor did she complain of pain when a gall-stone was passing.

Gangrene of the Bladder following over-distension.—Dr. HALL exhibited a specimen of gangrene of the bladder taken from a Frenchman aged thirty-six, a stout, heavily-built man, who was brought into the Pennsylvania Hospital at 4 o'clock, on Monday afternoon, the 31st September, in an extremely prostrated condition.

There was no note or history of the case from the physician who had been in attendance, but, in answer to a hurried inquiry, Dr. Hall was informed that the patient had not passed his water for the last thirty-six hours. An attempt to relieve him by the introduction of the catheter proved ineffectual. The following particulars were afterward ascertained:—

The man was an industrious journeyman in a perfumery factory. On Saturday night he had been seen to enter his lodging-room, and was not thought of again until Monday morning at the work-hour, when, not appearing as was his wont, the foreman went to look for him, and found him locked in, and apparently very ill. A physician who was sent for at 8 A.M. found the man complaining of pain in his lower belly. On asking him if he had passed his water lately, and receiving an answer in the affirmative, he thought no more of his bladder, but prescribed a carminative to relieve the pain complained of. When summoned again at 2 P.M., in haste, the man appeared to be partially delirious, but could answer questions when aroused. But when seen in the afternoon, there was a great change for the worse. The man was comatose, and in the same extremely prostrated state as noticed when brought to the hospital.

In a subsequent interview with his employer, Dr. Hall further stated, I learned that the man had been laboring under symptoms of stricture of the urethra for a considerable time previously.

There was nothing in his room to show that he had taken an opiate, or a poison of any kind.

At the time of his admission into the hospital, he was comatose with sighing respiration, an uncertain, frequent pulse, intermitting in its beats.

Digitized by Google

His face was angulated, his eyes sunken, the face, neck, and chest bathed with a cold sweat; his belly was exceedingly tympanitic. Local dullness well marked over the hypogastric region, extending as high as the umbilicus.

The only evidence of sensation evinced by the patient was a slight impatient grunt, or rather growl, when any pressure was made upon the distended abdomen.

A temporary improvement seemed to follow his being placed in a hot bath. His pulse went down to 85 or 90, and became more developed. The surface showed by its coloration that it responded to the heat stimulus, and we thought that he could hear when we shouted close in his ears, but he gave no other evidence of sensation save an impatient plunge or two when an electric current was passed through the præcordium.

While in the bath he passed an inconsiderable quantity of urine, tinged with blood, which caused a slight diminution of percussion-dullness over the bladder.

Another attempt by Dr. Morton and myself to introduce a catheter failed.

By persevering attempts he was made to swallow stimulants. Still the coma remained as before, and the patient gradually sank into a stupor. He died at midnight.

Autopsy ten hours after death. — Head, nothing abnormal. Lungs, healthy. Liver, kidneys, spleen, ditto. There were some slate-colored patches on the peritoneum, in the hypogastric region, but there were no traces of recent peritonitis. Bladder very much dilated, and filled with decomposed, intensely alkaline urine, mixed with blood of a brown color. The fluid gave out a most pungent ammoniacal odor, and stung my fingers quite sharply in some places where there were abrasions. From the urine was deposited a soft, mealy sediment upon the posterior wall of the bladder. There were a few flakes of lymph floating about in the fluid.

The mucous membrane of the viscus was of an intensely dark-red color, more soft and spongy in its texture than normal, and covered with numerous enlarged capillaries filled with blood, ramifying all over its surface.

In the centre of one of the walls of the viscus were several striated eschars, and around these small depressions the membrane was of a greenish gray or bronzed color; interspersed with these, and illustrating beautifully the transition-stages of inflammation, were maculæ of ecchymosed blood, poured out from the over-burdened vessels. The muscular coat of the bladder also appeared to be hypertrophied.

The primary cause of the retention of urine in this case, and the obstacle to the introduction of the catheter, was seen to be a tight stricture just at the commencement of the membranous urethra. Behind the seat of stricture the membranous portion of the canal was dilated. The immediate

Digitized by Google

cause of death was a spasmodic constriction of the urethra at the part already nearly closed, produced perhaps by a debauch. This brought on the retention, and the fatal issue.

DR. STILLÉ did not think that the symptoms corresponded very closely with the lesions. They were certainly not such as might be expected in a case of gangrene of the bladder.

DR. GROSS remarked that the period of retention of urine was very short. He believed it possible that the patient may have suffered from retention prior to the time it was discovered. Lymph, he stated, effused from an inflamed bladder, might assume a greenish or dark color simply by coming in contact with the urine, and this appearance might simulate gangrene.

DR. HARTSHORNE commented on the rarity of death from distension of the bladder.

Encephaloid Tumor of the Thigh.—DR. WOODWARD exhibited a specimen of soft medullary carcinoma from the back of the right thigh, just above the popliteal region. A similar tumor had been removed from the same patient last June, but the morbid condition had been rapidly reproduced.

The mass was a little larger than a man's fist, soft and brain-like, and consisted almost exclusively of elongated, oval, oblong, or irregular nuclei, varying from 1-6000 to 1-2000 of an inch in diameter. Intermingled with these were a few cells containing similar nuclei, and presenting the ordinary appearances of the cancer-cells. The nuclei were thick-walled, granular, without distinguishable nucleoli, and presented no reaction with dilute acetic acid.

A moderately firm tunic of connective and elastic tissue, imbedded in which were many of the above-described nuclei, invested the tumor.

Primary Cancer of the Pancreas.—DR. DA COSTA called the attention of the Society to a specimen of primary cancer of the pancreas. The case had been successively under the care of Drs. Mitchell and J. F. Meigs, and it was from them ascertained that the patient, a man forty-five years of age, by occupation a servant, had commenced last spring to complain of symptoms of indigestion, which yielded, however, to a great extent, to astringents and tonics. A more troublesome symptom was jaundice. Uninfluenced by medicines, it increased until the man's eyes and skin became of a most intensely yellow color. No external swelling over the liver, or in its vicinity, was perceptible. The liver seemed somewhat enlarged, and palpation showed its lower border to be rather hard, and not as smooth as is usual. Slight pain across epigastrium. About the middle of September the man presented the following symptoms: He was deeply jaundiced, had passed a

Digitized by Google

blackish-yellow urine, containing bile. Bowels somewhat constipated; stools clay-colored, not observed to be fatty. Pain across epigastrium and hypochondrium, extending to back. Slight if any symptoms of indigestion. Occasional vomiting. He had emaciated somewhat, yet by no means strikingly so. His spirits were good. No ascites or anascara. No local tumor perceptible in the abdomen.

He continued in this state until the 12th of October, when he was suddenly seized with an attack of hemorrhage from the lung, which lasted for several days. The blood was red and frothy, mixed with saliva; was spat up in considerable quantity, and mostly after efforts of coughing. The attack weakened him extremely. He died ten days after its commencement, so that the immediate cause of his death was pulmonary hemorrhage.

Post-mortem examination.—Skin and cellular tissues extremely yellow. Head not examined. Lungs healthy; the seat of the hemorrhage could not be found; the lower lobes were enlarged; some yellowish serum effused in pleural cavities, especially on the left side. Heart normal. On opening abdomen no fluid. Stomach normal; here and there its mucous coat seemed thicker than usual. Spleen of normal size. Liver enlarged and dense; a few, but only very few, small hard whitish masses scattered throughout its structure. In parts the liver-structure on the surface seemed slightly granular, as if in the earlier stages of cirrhosis. The color of the liver was green and mottled, some parts being very dark, inclosing others of a lighter hue. No blood transuded at any portion from the sections made. Microscopically examined the dark spots just alluded to consisted of irregular and large pigment masses. A few of the hepatic cells were filled with pigment granules, but not many; on the whole they were perfectly healthy, and fully capable of performing their functions. The fibrous tissue in the liver was not increased. The few hard white masses showed distinct cancerous elements. Gall-bladder fully distended with a thick inky bile, a few gall-stones; cystic duct dilated; hepatic duct and the common choledoch duct much compressed by a large irregular hard mass which extended across the median line backward, and proved to be, on closer examination, the head of the pancreas. Intestines healthy; so the mesentery. Pancreas firm and enlarged; its head and a few of the surrounding glands converted into a hard tumor nearly the size of a man's fist; its left extremity also somewhat harder than normal; in the middle the gland seemed of a lighter color. Pancreatic duct pervious; it ran through the base of the tumor and emptied itself into the duodenum.

A microscopical examination of the affected organ proved the hard mass to be a scirrhous tumor. It contained a large quantity of fibrous tissue, and distinct nucleated cells, some with several, others with only one large

Digitized by Google

nucleus, of a round or oval shape. Some of these nuclei were free. The cells were like those met with in marked cancerous tumors. In the portion of the pancreas next to the diseased head a great deal of fat, in the shape of granules and oil-drops, was perceived; no structure, however, like that at its head; nor could gland-cells be discerned. At the splenic extremity of the pancreas gland-cells were observed, with only a trifling amount of fat, also fibrous tissue, but none of the cells or of the structure perceived at the diseased part. This portion was, therefore, although somewhat denser, not cancerous; the middle portion was in a state of fatty degeneration; the head cancerous.

DR. DA COSTA then spoke of the fact that cancer of the pancreas seemed most usually to select the head of the organ as its seat. A further report on this, as well as on the prominent symptoms of similar cases, was asked for by the Society.

DR. MOREHOUSE alluded to the hemorrhage in this case as interesting. He had seen several cases of internal cancer, with hemorrhage from the lungs occurring as the disease advanced, without the lungs being affected.

DR. HEWSON mentioned a case in which the appearance of malignant disease had been preceded by frequent attacks of hæmoptysis, without any physical signs of pulmonary disease being present.

DR. STILLÉ inquired particularly into the hemorrhage in the case just read. Might it not have been from the stomach?

DR. DA COSTA thought not. The blood was red, frothy, and voided after slight efforts of coughing.

Bony Tumor of the Scrotum.—DR. RICHARDSON exhibited for DR. KERR a bony tumor of the scrotum, taken from a Chinese. The mass closely resembled the two upper maxillary bones placed in apposition. In some portions it was not very firm, but in others as hard as any osseous tissue. A minute examination proved it to contain bone corpuscles.*

WEDNESDAY EVENING, Nov. 11th, 1857.

The President, DR. GROSS, and afterwards Vice-President STILLÉ, in the chair.

DR. KEATING submitted some heart-clots to the Society, which had been obtained from a man, aged sixty-three years, who was admitted at St. Joseph's Hospital in a decidedly typhoid state, and presented signs of consolidation of the right lung. The *post-mortem* examination showed in the right ventricle a firm whitish clot, of considerable size, involving the tricuspid valve, and quite closing up the mouth of the pulmonary artery: on the left a considerable clot existed, apparently obstructing the aortic

Digitized by Google

opening. Dr. K. believed the clots to have been formed before death, and suggested that they might have preceded, and tended to cause the pneumonia. He spoke of the rarity of clots on the right side of the heart.

DR. STILLÉ remarked that many years ago he had seen a case of consolidation of both lungs, in which sudden shortness of breath was followed by signs of cardiac disturbance. About thirty hours after the commencement of the symptoms the patient died. A large clot was found in the right side of the heart invested by a distinct serous-like membrane, delicate but firm. He thought that the clot was formed originally by the rapid movement of the valvular apparatus of the heart through the highly fibrinous blood.

DR. DA COSTA alluded to a case, attended by a medical friend, where, after a blowing sound had existed for some time in the heart, it suddenly disappeared, and the left lung became dull on percussion. Dr. Da Costa has had an opportunity of seeing, at intervals, this case for the last three years. The physical signs of consolidated tissue still exist.

A discussion on heart-clots and the signs of their organization ensued, in which Drs. Richardson, Gross, Levick, Keating, and Woodward participated.

Cancer of the Liver, and other Abdominal Viscera.—DR. KEATING exhibited several cancerous organs removed from the body of a man, aged forty years, a stone-mason by trade, who was admitted into the medical ward of St. Joseph's Hospital on the 13th of October, 1857. He complained then of loss of appetite, a constant dull pain in the lower part of the back, and general debility. He had been bedridden with the above symptoms during the previous three months; had not been subjected to any special treatment, but had applied to a physician for advice on account of costiveness, and was ordered to take a blue pill every night.

Upon entering the hospital his aspect was so strikingly peculiar as to attract attention, and together with the constant pain in the back, extreme emaciation, and other nephritic symptoms, to cause suspicion to rest upon the kidneys as the probable seat of the morbid process under which his system appeared to be so rapidly wasting.

Upon inquiring into the state of his urinary organs his urine was found to be scanty, quite high colored, and decidedly acid. Though carefully and repeatedly subjected to the ordinary tests for the presence of albumen, nothing more than a mere trace could be discovered. The test by the sulphate of copper also failed to give the characteristic precipitate indicating the presence of saccharine matter. His stools, at first dark and of a watery consistence, soon became of a clay color, showing that the liver did not perform its function properly; and also at the same time a tympanitic state of the abdomen was observed.

Digitized by Google

During his course of medication, a tonic and diuretic plan of treatment were tried, until within a week prior to his death, when the diarrhœa returning, and the character of the stools exciting suspicion that there might be ulceration of the bowels, the oil of turpentine, together with the tincture of opium in emulsion, was ordered, under which treatment he appeared to be improving; but during the night of the 4th inst. he complained for the first time of severe pain in the epigastric region, became delirious, and died about 7 A.M. the next day.

Upon making a *post-mortem* examination of this interesting case there was found ulceration of the intestines, together with perforation of the duodenum. The pancreas and mesenteric glands were greatly enlarged, and appeared to be completely transformed into a hard mass. Some, when cut into, allowed a whitish fluid to transude.

The concretions also extended along either side of the spinal column, from the lumbar region even up as high as the fifth dorsal vertebra. This diseased state had also slightly involved the right kidney, while the liver presented a peculiarly mottled appearance, and was filled with large, hard nodules. A mass of fibrine was found in the right ventricle of the heart, and masses like miliary tubercle could be distinctly felt, as well as seen, by cutting into the structure of the left lung.

Examined microscopically by DR. DA COSTA.—In the liver all the white spots were cancerous; they yielded a fluid on pressure, which contained large nuclei, with nucleoli, and a considerable amount of granules and oil-drops. In the harder portions many very distinct cells, with many nuclei, as also free nuclei, and a few oil-globules were present; no fibrous structure; epithelial cells, unaltered, in intervening parts. Mesenteric glands—nuclei, and small cells, much fat, and cells filled with oil-globules, obscuring nuclei; many granules, which abounded in soft portions. Clot in heart, fibrine, granular, and small cells nothing resembling cancerous formation. Lungs not examined.

In answer to a question of Dr. Stillé, whether the glands in the intestine were healthy, Dr. Keating replied that they were.

DR. WOODWARD stated that he had examined the miliary formations in the lung, and believed them to be tubercular.

They consisted microscopically of a transparent amorphous substance, in which were imbedded a few granules and a number of shrivelled, more or less angular, and collapsed nuclei.

A discussion arose as to the coexistence of cancer and tubercle. Several cases were mentioned by different members of the Society.

Softening of the Stomach.—DR. GROSS exhibited a specimen of softening of the stomach by the action of the gastric juice. A boy, aged two years

Digitized by Google

and a half, from whom, in June last, he extirpated the left eye on account of encephaloid, died on the 24th of October, from a relapse of that disease, in a state of great emaciation and anæmia.

Post-mortem twenty-eight hours after death.—The stomach was found to be nearly filled with weak coffee, of which the child had taken large quantities for some time past, as his almost exclusive sustenance. In handling the great cul-de-sac, the organ gave way at that point with a large rent, in consequence of the softening of its tunics from the action of its contents. The mucous membrane presented a gelatinous appearance, and the muscular fibres in the parts immediately around looked preternaturally pale, and were easily torn. The rest of the organ seemed to be healthy. Contents of stomach did not exhale any acid odor. A piece of small bowel, carefully cleaned and retained in contact by its mucous surface with the cul-de-sac of the organ for three days, did not appear to have undergone any material changes in its color or consistence.

Fungus of the Testicle.—DR. GROSS exhibited a fungus of the testicle, with fibroid degeneration of its tubular structure.

A. W. D., aged twenty-nine, of Montgomery County, Pa., nine years ago had a chancre and bubo, which continued two months. Four years after this he contracted another chancre on the head of the penis, which was cured in three weeks, but was followed by copper-colored scaly eruption of the integuments, by rheumatism, and nodes on the arm and tibia. Three years ago the right testicle became enlarged, hard, and painful, and four months ago a small pimple appeared on the right side of the scrotum, which gradually extended into an open sore, giving rise to a large fungus formation. This soon became the seat of an offensive, ill-looking, and profuse discharge. The organ, being almost completely degenerated, was removed a fortnight since. The wound is at present in a healing condition. There is still a slight eruption on the face, and an ulcer on the left tibia. The left testicle is also partly enlarged, but much less than the right On dissection, the affected organ was found to be almost completely deprived of its natural structure, the tubular matter being replaced by a fibroid tissue of a pale yellowish color and firm consistence. At the posterior part of the epididymis was an abscess about the volume of a small hickory-nut, occupied by a tough, yellowish, cheesy-looking substance, having a close resemblance to tubercular deposit. Dr. Gross alluded to a case of a similar kind which occurred in his practice a year ago, where the testicle had undergone the same fibroid degeneration. The man had labored for a long time under tertiary syphilis, and a large fungus existed upon the scrotum.

Digitized by Google

Obscure Injury of the Shoulder-joint.—DR. KEATING next exhibited a specimen of an obscure affection of the shoulder-joint. The patient, a man aged thirty-two, had died of phthisis. Eight months before his death he fell down a flight of stairs and injured his shoulder. He was treated for fracture. When first seen the arm was lengthened, and had the appearance of being dislocated.

On the head of the humerus, near its lower border, the cartilage was entirely absent in two spots. The bone at these points was hard and smooth. An irregular groove passed across the glenoid cavity of the scapula. The head of the humerus had evidently rested at these bare spots on the lower edge of this groove in the glenoid cavity.

DR. GROSS considered it a case of partial absorption of the cartilage of the head of the humerus and glenoid cavity. He did not see any evidence of fracture. It was simply a removal of the cartilage, and irregularity of the bone.

DR. HEWSON remarked that Dr. Robert Adams, of Dublin, had shown him specimens of chronic rheumatic arthritis, which closely resembled that on the table.

DR. HARTSHORNE spoke at some length about the fractures of the head of the humerus and of the glenoid cavity. He did not wish to say that this was a fracture, yet it had the appearance of one. A committee, consisting of Drs. Hartshorne, Gross, and Hewson, were appointed to examine into the exact nature of the specimen presented.

Ovary containing Bone.—DR. WOODWARD exhibited some pieces of bone from a large ovarian cyst. The ovary in this case contained an extensive deposit of encephaloid, and the cysts contained also hair and fat.

Digitized by Google

WEDNESDAY EVENING, Nov. 25th, 1857.

The President in the chair.

Eburnation of Bone.—DR. PACKARD called the attention of the Society to a specimen of disease of the hip and knee-joints, obtained in the University dissecting room several years ago, from a male subject about fifty years of age; no history of the case could be procured.

The right acetabulum is seen to be enlarged, and the surface of the neighboring bony tissue roughened by adventitious deposit. The upper part of its edge is irregularly absorbed to some extent; at the upper and back part of the cavity the surface is roughened, and of a worm-eaten appearance, to the extent of 1½ by 2 inches. Just at the edges of this patch the bone is eburnated, being very hard, white, and polished. The foveola is nearly filled with bony deposit.

The head of the femur has exactly the same characters as the acetabulum at precisely corresponding points, except at the part opposite the foveola, where it is unaltered. The *corona*, if it may be so called, and the entire cervix of the bone, are covered with a very thick and irregular adventitious deposit of bony matter. Both trochanters, the inter-trochanteric lines, and the linea aspera, are also thickened and roughened.

The left knee-joint seems healthy, except that on the articular face of the inner condyle of the femur is a patch 1¼ inch wide by 2⅜ inches long, which is very exquisitely polished, evidently by friction upon the corresponding surface of the tibia, where a similar patch is seen, differing only that it is 1½ inch wide by 1⅜ long. Around the articulating extremities of the femur, tibia, and fibula are irregular adventitious deposits of bony matter.

The other hip and knee-joints were diseased in the same way, but to a much less degree; they were not preserved.

This would seem to have been an instance of the affection described by R. W. Smith, in his work on *Fractures and Dislocations*, under the name of "Chronic Rheumatic Arthritis." Mr. Benjamin Bell calls it "Interstitial Absorption of the neck of the thigh-bone." Dr. Packard believed that it was rarely seen in the knee-joint so well characterized as in this specimen.

Cystic Tumors on the Nates, obstructing Delivery.—DR. KELLER exhibited two remarkable specimens of cysts taken from the nates of children, and which had presented a great obstacle to their delivery. The following histories of them were reported:—

CASE I.—Mrs. R., about twenty-five years old, had previously been delivered of two full-grown, healthy children. She was at the time in very

Digitized by Google

good health, and the prospects for a third easy delivery were very favorable, the child being found with the vertex presenting. After a few pains the head was born, and the trunk of the child followed easily up to the hips; here it stopped; and when the attending physician tried to extract it in the usual way, he found an obstacle which he could not overcome even by exerting all his force. Having called in some experienced colleagues, the blunthook was used, by which the child was soon delivered, alive, but unfortunately with the left thigh broken by the application of this dangerous instrument. Owing to this accident, and to a deformity on the back, the physicians declared the child could not live. Three days after the delivery of the woman, (on the 6th of December, 1855,) I was called to see the child in consultation, the mother being sick and the child in a desperate state, as the fractured leg had begun to mortify. When I examined the child I found a tumor, (see Fig. 1,) of the size of a man's head, attached to the nates, exactly behind the orificium ani, and containing a liquid. On the right side, at the base of the tumor, could be felt, by a careful examination and strong pressure through the liquid, another hard tumor, in form and size like an egg. The child not being expected to survive, had not received any nourishment excepting a little tea and water. In order to settle the question whether the child could live or not, it was proposed, on the eighth day, to empty the sac by a puncture. More than a quart of a brownish liquid escaped, which became of a bloody color as it continued to flow. The child died a few hours afterwards, from a hemorrhage into the sac. A post-mortem examination was performed the next day. The viscera were all found in a perfectly healthy state, and did not communicate with the tumor. The sac was shrivelled into folds, and contained a large clot of blood. It was a perfect cyst, the parietes of which were very dense, covered in some parts, particularly at its insertion into the nates, with soft conglomerations of blood-vessels. The smaller, hard tumor above mentioned, which was felt inside of the sac, was formed by cysts, having dense but transparent membranes, and containing a clear liquid. At no point did the cyst communicate with the spinal column.

FIG. 1.

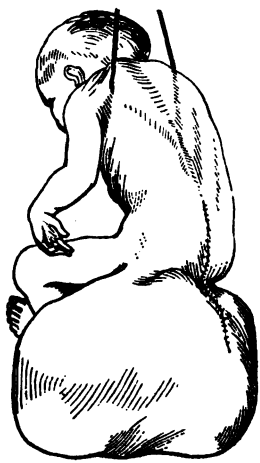

CASE II.—On the 21st of March, 1856, at 2 o'clock A.M., I was called to attend Mrs. T., in labor; I found the patient in a strange situation, as the child, having presented in a position of the vertex, had made its full exit, but could not be separated from the mother, being attached by a pedicle to

Digitized by Google

a large body remaining in the womb, which was supposed to be another child. Before examining, I suspected a cystic tumor, and in this opinion was fully confirmed by a close examination. I immediately punctured the tumor with a curved trochar, and after the evacuation of about a gallon of a brownish liquid the sac was emptied, and the child naturally expelled. It died about six hours after its delivery by a capillary hemorrhage into the sac. The liquid unfortunately could not be examined chemically, as it was thrown away in spite of my strict injunction. The sac showed externally the natural appearance of the skin; the walls were about one-sixth of an inch thick. The internal surface was covered on the upper part with a soft tissue, which showed under the microscope a rich network of capillary blood-vessels, very similar to the villi of the intestines. The lower part was covered with a reticulated fibrous tissue. The tumor was inserted between the orifice of the rectum and the point of the coccyx, as in the first case; not exactly in the centre, but about two inches to the right side. A careful examination proved that the tumor did not communicate with the vertebral canal.

Fœtal Monstrosity.—DR. HEWSON exhibited the head and neck of a fœtal calf, presenting four eyes, two jaws. The skulls are blended; there are four lobes of cerebrum and cerebellum, each distinct; the medulla is single; the tongue bifid; the larynx and trachea single; the decussation of the optic nerves obvious; articulation of the jaws blended, but movable; sclerotic of the contiguous eyes blended.

Fracture of Cervical Vertebræ.—DR. MORTON exhibited several fractured cervical vertebræ taken from a young man twenty-three years of age, who fell down the hold of a vessel and struck with violence the back of his neck. He lived eleven days, then died of suffocation. The body was paralyzed from the arms down; the patient could lift his arms, but could not flex or extend the fingers. A marked symptom was retention of urine, which lasted until within two days of death, when the urine passed involuntarily from him. The heat of surface two hours after the accident was 102° Fahr. On post-mortem examination the transverse process of the fifth vertebra was found to be broken, and pressing on the spinal cord. The spinous process of the sixth was broken off; also a considerable portion of the bony bridges which connect the spinous with the oblique processes were fractured and pressed downward, but did not touch the cord. The bodies of the sixth and seventh vertebræ were crushed one into the other.

Laceration and Severance of the Cervix Uteri.—DR. KELLER presented a specimen of ruptured neck of the uterus. When the patient was

Digitized by Google

examined by him, during labor, the lips of the uterus were much swelled and enlarged; the os tincæ admitted two fingers. The head presented; the womb was in a position of anterior obliquity. The head of the child pressed on the posterior wall and lip of the womb, which it finally ruptured. The child was still-born, after several hours' labor, and a tumor was then found protruding beyond the external parts. A ligature was applied around its base, and the tumor came away five days afterwards. It is now two months after the accident, and the patient is well. Indeed, at no time did she present any unfavorable symptoms. On examining the tumor carefully, it was found that it consisted of the healthy neck of the uterus, which had been severed and carried down by the child's head.

Deformity of the Neck of the Thigh-Bone, simulating Fracture with Ossific Union.—DR. RICHARDSON exhibited a specimen (see Fig. 2) of deformity of the neck and head of the femur, for the purpose of calling attention to the liability of mistaking such deformities for ossific union of fracture of the bone within the capsular ligament. The specimen was recently obtained from the body of a man, apparently about twenty-five or thirty years of age, and of good physical development, brought into the dissecting room of the Medical Department of Pennsylvania College; and upon first inspecting it Dr. Richardson supposed it possible that a fracture of the cervix, followed by bony union, might have taken place; but upon making an examination of the bone of the opposite side, a deformity of the same character, but much less in degree, was found there also.

FIG. 2.

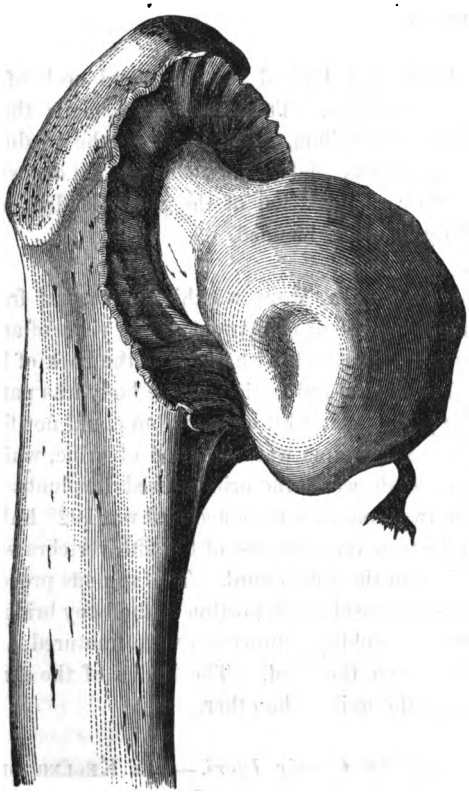

Digitized by Google

The neck of the specimen shown is depressed so as to form with the shaft below an angle of 45°, much shortened, and increased in its antero-posterior diameter. The head is somewhat enlarged, spread out, and rendered irregular at its junction with the neck by the deposit of little nodules of new bone. The acetabulum is flattened out in correspondence with the increased size and flattening out of the head.

Dr. Richardson supposed the deformity to be the result of rickets, although upon examining the remainder of the skeleton he could find no want of symmetry in the bones except in those connected with the coxo-femoral articulations.

DR. MORTON then read, for DR. R. P. HARRIS, of Philadelphia, a paper on a case of Fallopian Pregnancy, terminating in death.

WEDNESDAY EVENING, December 9th, 1857.

The President in the chair.

Apoplexy of the Lung, with Disease of the Mitral Valve.—DR. DA COSTA exhibited a specimen of apoplexy of the lung, accompanying a narrowing of the mitral orifice. T. B., the patient from whom the specimen was obtained, a man thirty-five years of age, came under his care eight months ago, complaining of palpitation of the heart and occasional attacks of bronchitis. A year ago he had suffered from metallic poisoning, which brought in its train a fearful attack of colic, and left him subject to obstinate constipation. Previously, he had had secondary syphilis. At what time he first noticed the irregularity of the heart's beat, he could not remember; he complained of it while being treated for syphilis, but it is very probable that it had at times annoyed him before this period. When first seen, he looked sallow, was troubled occasionally with shortness of breath and palpitation, but was otherwise enjoying tolerably good health. A physical examination of his heart showed the dullness over the precordial region to be increased. The impulse was rather strong, and extremely irregular. A blowing sound was perceptible near the apex; none over the aortic or tricuspid cartilages. The great irregularity and rapidity of the beat rendered it impossible to ascertain whether the blowing sound was synchronous with the systole or diastole; it certainly did not occur with both. The pulse was small, frequent, and intermittent.

He continued in this state until within the last three weeks. His heart beat very irregularly; occasional difficulty in breathing, although this was by no means at any time a very severe or permanent symptom; occasional bronchitis; no dropsy. The sounds over the heart became more and more difficult to analyze, the blowing sound being by no means distinct;

Digitized by Google

in fact, seeming to disappear altogether, while a peculiar clack took its place, or at any rate permitted it but rarely to be heard. This clack was best heard at the apex, faintly transmitted to other portions of the heart, yet sufficiently to obscure the normal sounds; it occurred with but one sound of the heart; with which, could not be determined.

Latterly, he had considerable cough, with frothy expectoration; dyspnœa at night; his face and feet had commenced to swell; diuretics had little influence over the watery effusion.

December 3d.—His symptoms grew much worse. His cough was very troublesome. Large and middling-sized moist râles were heard over his chest. He expectorated considerably. The sputum was not very thick.

During the night of December 6th he was seized with great difficulty of breathing, and pain in his chest. The pain was very severe and sharp on the right side, about the fourth rib. He expectorated a very small quantity of blood.

December 7th.—The pain had much lessened; there were no physical signs over its seat, except the moist râles, which were heard over the greater portion of the chest; the difficulty of breathing continued unabated to his death, December 8th.

Post-mortem examination.—The pleural membrane was perfectly healthy. The lungs were very vascular. In their upper lobes were several dense circumscribed spots, some of a dark, dull color, firm, and with signs of inflammation both in them and immediately around them. This was especially the case with the spot on the right side, corresponding to the seat of pain. Other spots, especially one on the left side, about an inch and a quarter in diameter, contained dark fluid blood, readily scraped away. The effusion seemed, to a great extent, to have taken place into the air-vesicles and minute bronchi.

The heart was enlarged; the cavities of the ventricles somewhat dilated; the walls increased, but not to a very marked extent, and more so on the left side than on the right; the auricle of the left side was considerably distended; its walls very slightly hypertrophied. The tricuspid and pulmonary valves were healthy; so were the aortic, save a trifling thickening, which, however, could not have impaired their function. The mitral valves were extremely diseased. They had been converted into a calcareo-osseous mass, which nearly closed the orifice, leaving an irregular and extremely narrow fissure for the blood to pass through, certainly not the twelfth of an inch in size.

DR. DA COSTA then spoke of the almost entire absence of external hemorrhage in this case.

DR. MOREHOUSE inquired whether the absence of hæmoptysis was not the rule in pulmonary apoplexy? He had seen several cases of pulmonary apo-

Digitized by Google

plexy with but trifling, if any, external hemorrhage. In one case, there was diffuse hemorrhage into the cellular tissue of the lung; in another, the effusion of blood into the lung was more circumscribed, and had taken place into the cells alone. Dr. Morehouse also directed attention to the evident signs of inflammation which two of the apoplectic lobules on the table exhibited, and suggested that these might have been the seat of an earlier apoplexy; those in which the blood was dark, and still half-fluid, being of later occurrence.

DR. DA COSTA stated, in reply, that he did not believe that pulmonary apoplexy was either of necessity produced, or connected with, external pulmonary hemorrhage. Indeed, he thought that even where this occurred, the quantity of blood expectorated was usually small. He was able to add another marked case to those mentioned by Dr. Morehouse. The patient, a laboring man, having an enlargement of the heart, was suddenly seized, after violent exertion, with palpitation of the heart, and great distress of breathing, caused, as was afterward ascertained, by nodular apoplexy of the lung. The sputum was merely very slightly tinged with blood. With regard to the signs of inflammation in the specimen before him, he remembered no means of ascertaining, as far as the symptoms went, if the hemorrhage into the lung had occurred at different times. He conceived the inflammation to have been produced by the blood acting as a foreign body.

DR. KEATING thought it a rare occurrence to have hemorrhage from the lung from mere congestion produced by disease of the heart. He mentioned several cases of supposed cardiac hæmoptysis, in which the lungs were found filled with tubercles, which had been the true cause of the hemorrhage, and inclined to the belief that these cases were more frequent than it was supposed.

DR. MOREHOUSE, and several other members of the Society, cited cases of hæmoptysis entirely unconnected with pulmonary disease, and evidently dependent upon the obstructed state of the circulation produced by cardiac disease.

Urinary Calculus.—DR. FORBES exhibited a specimen of urinary calculus, taken after death from the bladder of a man aged seventy. It weighs 726 grains. The bladder was sacciform, and much thickened; the calculus was of the mulberry variety, and of a dark color. The rectum presented a fistula in ano; the rest of the organs seemed healthy.

DR. MITCHELL remarked, with reference to the deep dark color of the calculus, that the oxalate of lime, when present in the urine, or in forming calculi, irritates and produces a bloody effusion which frequently tinges the stone, and causes it to contain much iron. Dr. Mitchell had found iron in a large number of urinary calculi—and indeed a little iron is always present

Digitized by Google

in healthy urine, which would be increased if blood were effused. He had examined stones with regard to other metals, especially copper, which he had found in biliary, but not in urinary calculi.

Cancerous Stricture of the Ileo-cæcal Valve.—DR. KELLER exhibited a cancerous stricture of the ileo-cæcal valve, removed from a man who had long been subject to obstinate constipation. The stools were clay-colored; only about one passage in ten days. This, with a gradual falling off in health, and latterly with severe pain in the right iliac fossa, and vomiting, were the prominent symptoms. The liver, on post-mortem examination, was found to be healthy; so were the other abdominal viscera. The fæces in the upper bowels were of a green color. The ileo-cæcal valve was converted into a hard cancerous stricture, which presented elements like those of cancer under the microscope. The muscular coat of the intestines was greatly hypertrophied.

DR. LA ROCHE inquired whether the patient had suffered from jaundice.

DR. KELLER stated that he had not. He believed the liver to have been performing its functions properly, and its ducts to have been pervious. The fæces must have lost their greenish color in descending the small, to reach the large intestine.

Apoplexy of the Brain, consequent upon the use of the Trephine for the Removal of a depressed portion of Bone.—DR. GROSS exhibited portions of brain and dura mater, removed from the body of a man aged thirty-three. The following was the history of the case:—

G. W. Mason, aged thirty-three, became a patient at the Clinic of the Jefferson Medical College, in November, 1857, on account of a depression of the skull, caused, when he was a boy eight years old, by a blow from a circus pole. The depression was situated on the left side of the head, over the upper portion of the parietal and frontal bones, and was nearly two inches in diameter, by upward of half an inch in depth at its centre. Upon recovering from the immediate effects of the injury, Mason's health remained good until the age of twenty-two, when he was seized with epileptic convulsions, which continued to recur with more or less frequency and severity up to the time of his death. Within the last few months they had assumed so aggravated a character as to disqualify him, in great measure, from following his occupation, which was that of a clerk, his memory having become much impaired, his articulation defective, and his general health much disordered. Under the judicious advice of Dr. Oliver, his family physician, he had made use of a mild alterative course of treatment and a regulated diet, but with no improvement whatever in his condition.

On Wednesday, Dec. 2d, Dr. Gross removed, in presence of the medical

Digitized by Google

class, two discs of bone at the site of the depression, the patient being under the influence of chloroform. The affected bone was remarkably thin, as well as very hard; and when the crown of the trephine had nearly cut its way through, it suddenly caved in, followed by a copious escape of serous fluid. One of the pieces had a long, narrow exostosis upon its inner surface, exhibiting some resemblance to the temporal bone of the fœtus. Corresponding to this projection was a slit-like opening, with well-defined edges, in the dura mater, large enough to admit the point of the index finger. After all the depressed bone was removed, it was ascertained that the dura mater had long been detached for some distance around, its surface having acquired a whitish polished aspect, and formed, along with the inner surface of the bone, a sort of reservoir for the lodgment of the serum which escaped so freely during the operation.

For the first forty-eight hours he appeared to be doing extremely well, although during the first night he had a slight convulsion. At the end of this period he became somewhat stupid, and answered foolishly, but was always able to protrude his tongue. On Saturday he had symptoms of drowsiness, which increased on the following day, when he had also a pretty severe convulsion. He now became soporose, and, although he could be roused, it was impossible to keep him awake longer than a few seconds at a time; he was still able to swallow. On Monday morning, December 7th, he was breathing stertorously, and was evidently in an apoplectic condition. Death occurred at eight o'clock A.M., nearly five days after the operation.

This case, which, so far as Dr. Gross is aware, is unique in its character, is of great interest in a physiological point of view, as showing the importance of the cerebro-spinal liquid in maintaining the functions of the brain, and, especially, the balance of the circulation. Had the membranes of the brain been free from any abnormal opening, permitting the escape of this fluid, it is difficult to conceive how so great an effusion of blood could have taken place after such an operation, as was found in the substance of the brain and its ventricles. Inflammation had certainly nothing to do with the fatal result, since there was no evidence of its existence, either during life or after death.

Thus it will be perceived that the immediate cause of death was apoplexy, occasioned by the removal of the pressure from the brain in consequence of the escape of the cephalo-spinal fluid, destroying the balance of the circulation, and rupturing the cerebral vessels just below the former site of the depression in the skull, where, as was previously stated, the cerebral substance had undergone chronic softening. How long the softening had existed must be a matter of conjecture; but the period must have been considerable, as is proved by the fact that there were old organized apoplectic depôts at the seat of the disease. The last and fatal attack of

Digitized by Google

apoplexy probably began on the third day after the operation, and gradually proceeded, until it rendered the patient completely insensible nearly twenty-four hours before death.

An examination of the body was made twenty-nine hours after death, with the assistance of Drs. Gibbons, Asch, and S. W. Gross. The edges of the wound had partially united. There was no blood or pus between the scalp and dura mater, except a small quantity of semi-organized blood on the membrane, which caused it to adhere pretty firmly to the scalp. The opening in the dura mater, which was opposite the exostosis on the second disc of bone, was well defined, and large enough to receive the end of the index finger. The opening extended also through the arachnoid and pia mater, which accounted for the escape of the cephalo-spinal fluid after the operation, as well as at the time of its performance. On the surface of the brain, below the site of the operation, there was a patch of lymph in the sub-arachnoid areolar tissue. The pia mater was exceedingly vascular. The inflammation of the arachnoid was in itself insufficient to have produced any serious consequences. There were old apoplectic depôts in the furrows of the hemisphere, just below the site of the depressed bone. Upon making a horizontal section of the left lateral lobe, an enormous effusion of black blood was found a short distance below the surface of the brain. This was partly fluid, but for the most part coagulated, and had, as its boundaries, softened cerebral substance, looking very much like spoiled lymph and pus. The cerebral substance in its neighborhood was, in some parts, soft; in others, hardened. The extravasation extended into the middle lobe, in which was also found an old apoplectic depôt, or a semi-organized clot, of a roundish shape and as large as a marble. The left lateral ventricle was filled with blood, a large solid mass extending into its posterior horn, as well as into the third ventricle.

DR. LA ROCHE did not feel satisfied that the apoplectic clot and softening were recent. The latter especially, he thought, must have existed prior to the operation. He inquired of Dr. Gross whether any symptoms of compression, or of paralysis, had been observed at any time before the operation.

DR. GROSS.—None.

Tubercle of Lung simulating Cancer.—DR. MORTON exhibited a specimen of tubercle of the lung, having the exact appearance of cancerous deposits. The lung was filled with hard, roundish masses of various size. When cut into, these did not show any fibrous arrangement, nor were they as hard at the centre as at the periphery.

DR. DA COSTA mentioned that, at the request of Dr. Morton, he had examined these little tumors with the microscope; and although, from their

Digitized by Google

appearance to the naked eye, he had expected to find in them the elements met with in fibroid or in cancerous tumors, yet such was at no portion the case. The round masses exhibited: lung structure much obscured by granules, and on a delicate basement, between the fibrous walls of the air-vesicles, granules, and non-nucleated cells, irregular in shape, small, but in close contact. The cells floating under the field of the microscope were epithelial cells, somewhat shrivelled, a few filled with small oil-drops; and irregular corpuscles, such as are usually designated as tubercle corpuscles.

DR. LEVICK stated that it was his opinion that the masses were tubercular. Several of them were softened in the centre. Dr. Levick spoke of the value of minute examination in similar cases. May not some of the reported cases of cancer of the lung and tubercle in other parts of the body be like this? Dr. Levick then commented on the rarity of primary cancer of the lung.

Enlarged Vermiform Appendix.—DR. MORTON next exhibited an enlarged vermiform appendix, nine inches in length, and filled with fæcal matter. It had not, during life, given rise to any symptoms.

WEDNESDAY EVENING, Dec. 23d, 1857.

The President in the chair.

Cancer of Several Organs.—DR. MORTON directed the attention of the Society to the cancerous viscera on the table. The history of the case is as follows:—

"Margaret Brown, aged thirty-five, a native of Ireland, was admitted into the Pennsylvania Hospital, November 25th, 1857, on account of a very painful tumor on the surface of the abdomen, at the base of the sternum; it had quite a carbuncular appearance. She stated that the tumor first showed itself about four months before her admittance, and that it came as a small, hard, round nodule, which gradually increased in size; it had a very hard base, and was softer toward the middle. She has always had a great deal of pain in it, more of late, and most during the night. She said her bowels had always been costive. She was nursing an infant, five months old, when she came into the hospital, but her milk failed her about two weeks before her death; her health had been very good until within a short time, and she had never any pains in other parts of her body. She was put upon a tonic treatment; and the tumor, which seemed as if it contained pus, was poulticed, and opened and discharged a thin watery matter. On the morning of the 20th of December she complained of a soreness in her neck; marked symptoms of tetanus set in, which terminated fatally at five P.M. the next day.

Digitized by Google

Post-mortem examination fourteen hours after death.—The tumor on the abdomen extended only through the parietes, and was attached to the cartilages of the ribs and sternum; when cut into, it presented a cancerous appearance. The lungs and heart were healthy. The kidneys were full of cancer-spots all over the surface; one cancerous mass was found in the cellular tissue, near the pelvis of the left kidney; a large cancerous tumor was found occupying the right side of the pelvis, over the sacro-iliac junction, as large as two fists; through it the iliac vessels and nerves passed, entirely surrounded by the tumor. A small mass was found in the left axilla, which had the same characteristics as the other tumors. Other organs healthy. Portions of each tumor were examined under the microscope, and exhibited cancer-cells.

DR. DARRACH suggested that the lesion of nerves which were involved in the tumor near the ileum might have been the cause of the tetanus.

Hairy Mole on the Cornea of an Ox.—DR. DARRACH exhibited a hairy mole on the cornea of an ox. The ox, during life, had not its sight affected by the mole, and could close the lids without difficulty. The surrounding cornea was healthy.

The mole was situated on the upper and outer portion of the cornea; was attached to the conjunctiva by a band of conjunctival tissue; it had a broad base, and was covered with hairs from six to eight lines in length. The mole at the base was about five and a half lines, and about five in height.

DR. HEWSON stated that a patient at Wills Hospital had been lately under his care who had a wart on the inner border of the cornea similar to the one exhibited. It was not, however, covered with hair.

Large Gall-stones; some impacted in Hepatic Ducts.—DR. PACKARD exhibited a gall-stone, oval, concentric, with rings of darker and lighter brown; 1 inch and $\frac{9}{16}$ in length, $\frac{5}{8}$ in width, (measuring the section;) it had completely distended the gall-bladder. The liver was natural in appearance, but in the left lobe the hepatic ducts were found distended to the size of the portal vein by gall-stones of various sizes, all soft and brown.

No other visceral disease existed. The patient was a sailor, who had fallen overboard from a vessel, fracturing his right thigh, and remaining in the water about an hour; the accident occurred about four days previous to his death, and no reaction took place in the interval.

DR. HALL exhibited the four extremities of a woman who died of idiopathic gangrene, while he was resident in the Episcopal Hospital. The case was, at the time, fully reported in the March number of the *Medical Examiner*, 1856.

Digitized by Google

Vesical Calculus.—DR. MITCHELL exhibited a mace-shaped calculus. This curious stone (Fig. 3.) was removed post-mortem, by Dr. Pancoast,

FIG. 3.

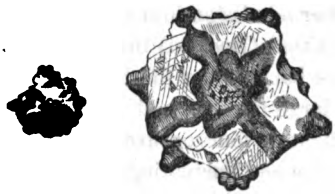

Outside.—Nat. Size. Section magnified 2½ or 3 diameters.

from the bladder of Mr. B. Its form is well enough illustrated by the plate, where the flat surface of the section is seen enlarged, the rough outside being drawn of the natural size. The dark portion is prolonged from the centre into ray-like projections, and is, like them, composed of oxalate of lime. The intervening white substance is phosphate of ammonia and magnesia, with phosphate of lime. Two calculi resembling this one are described in the *Amer. Journ. of Med. Sci.*, vol. iv. p. 333. The present specimen is certainly a pathological curiosity, for whose singular form we are quite at a loss to account.

DR. DARRACH, in commenting on the different forms assumed by urinary calculi, mentioned that an organic mould had been discovered to be the ground-work of many; the salts being deposited around. This mould had, at least on a small scale, been lately produced artificially.

DR. MITCHELL spoke on the same subject, and stated further, that it was the belief of some of the French observers that even separate crystals had an organic stroma.

Necrosis of Head and Upper Part of Os Femoris removed by an Operation of Excision.—DR. ADDINELL HEWSON exhibited a specimen of necrosis of the head, neck, and portion of the shaft of the left os femoris, which he had removed the week previous, by excision, from the hip of a girl aged thirteen years. The girl had suffered with disease in her hip for more than two years, but had had no care whatever bestowed upon her during that time. She had been living on a truck-farm, near the city, where her father was but a common day-laborer. She had lost her mother seven years before by phthisis. Soon after the first appearance of the lameness in the joint an abscess formed and slowly worked its way to the front of the thigh, where it opened, about three inches below the groin. This opening shortly closed, and the head of the bone became dislocated on the dorsum ilii, and she walked about by leaning forward and resting on

Digitized by Google

the ball of the foot. In the course of three or four months the matter re-accumulated and discharged itself through the old opening. About ten months since an abscess formed on the inside of the thigh; it grew but slowly, and was finally opened by the patient herself, with a needle, some three months before her admission into the Wills Hospital.

When she was admitted (Dec. 2d) this opening was still discharging a thin sanies, and on the back of her thigh, just at the lower border of the buttock, there was a large purulent collection. The integuments were here discolored to the extent of four or five inches in circumference, and the tumor beneath was large and fluctuating. The thigh was flexed almost at a right angle to the pelvis, and admitted of but little motion, although it was not firmly anchylosed. No crepitation or grating could be elicited. Her health had been failing her for the last five months; her belly was tumid, but her bowels were regular, and their dejections natural. She was excessively pale and emaciated, and suffering from hectic. Her pulse was 130, feeble and flickering. There were no signs of pulmonary or other organic disease. She had acquired great mobility in the lumbar vertebræ by her efforts to hold herself erect.

The abscess in the region of the buttock was opened a few days after her admission into the hospital, and from it there were discharged about two ounces of fetid pus. No direct communication to the head of the bone could be detected through this abscess, nor was there any dead or exposed bone detected by the probe. After the tumefaction, however, had subsided, the pus could be made to flow out of the opening by pressure above the head of the bone, showing clearly that this abscess was connected with the joint.

The operation of excision was performed December 16th, and the head, neck, and three and a half inches of the shaft (measuring from the point of the great trochanter) were removed through a T incision, made over the joint on its outer side. The head of the bone was found lying just above and behind the edge of the acetabulum, where it had formed a deep cup of bone for itself. Both the head of the bone and this new acetabulum were profoundly necrosed. The old cavity was partially filled up with organized lymph, and entirely free of disease. The head and neck of the bone, necrosed through their whole thickness, had partially undergone molecular exfoliation. They were much reduced in size. The portion of the shaft removed in the operation was entirely denuded of its periosteum, saving the great trochanter, on which this tissue was dense and firm, and somewhat thickened. No exfoliation had occurred in the shaft. Here the necrosis appeared to be recent, and to involve only the external lamella of bone. The periosteal covering of this portion was almost entire, although separated by purulent matter from the bone.

Digitized by Google

Dr. Hewson remarked that the specimen illustrated very admirably, he thought, the progress of *morbus coxarius* in its advanced stages, and how very ineffectual the unaided efforts of nature must sometimes be to cure the disease. Here had evidently been disease involving only the fibrous structures of the joint in the first instance, or, if the disease was more profound, it affected only the surface of the head of the thigh bone, but not the acetabulum also. Suppuration ensued, and the capsule of the joint giving way, the head of the bone became dislocated on to the dorsum ilii. Here nature attempted a cure—a new cavity was formed to receive the bone—but sufficient time was not allowed for the repair to be perfected. The little patient not being restrained, used the limb too soon and too much, and so re-established the destructive action, or, perhaps, rather excited that which was latent, or had nearly subsided. But now the morbid process extended beyond its original limits. It now not only involved the head of the bone, but had attacked the new cavity formed for its reception. Necrosis of both these parts was the result, and nature's efforts to get rid of the dead tissue only involved a further destruction of the thigh-bone; for the pus formed in the process of *insensible exfoliation* which ensued, burrowed down along the neck and shaft of the bone as along a director, denuding those parts, and consequently causing their ultimate death. To what extent this destruction would have gone, it is impossible to say; but it must be evident to all who have seen the patient, that she would have sunk under exhaustion long before nature could have effected the separation of such a mass of dead tissue, even if she could have done so without further expense to the living bone.

The patient is now doing well, and the cure in her case is steadily progressing.

Dr. HARTSHORNE, who was present at the operation, made some remarks on the state of the cavities in which the head of the bone had rested. The old was partially filled up; the new, it had appeared to him, communicated with this by means of a narrow passage.

Bright's Disease.—Dr. HUMPHREYS exhibited a specimen of Bright's kidney, small, granular, and hard. No history attached. The patient was admitted for an injury, into the Pennsylvania Hospital.

Dr. LEVICK alluded to the similarity of this kidney with the one described as the "gouty kidney."

Dr. DARRACH spoke of the different forms of chronic Bright's disease, and the resemblance between them and some morbid states of the liver.

About four or five years ago, while resident physician at the Pennsylvania Hospital, his attention was attracted to the analogy existing between the diseases of the kidney and the liver, by the observation, at post-mortem

Digitized by Google

examinations of these organs. Perhaps the best method to present the subject will be to briefly mention illustrative cases.

CASE I. was a granular kidney, small in size, consistence firm, much granulated, surface and outline very irregular, with thickening and solidification of the fibrous tissue about the hilus. Here we have an affection closely resembling in appearance that which has been termed cirrhosis of the liver, and although the fibrous tissue at the hilus of the kidney cannot be considered as analogous in function to that of the capsule of Glisson, yet in structure it is the same; and they are further alike that it is the fibrous tissue of the substance of the kidney which is the seat of inflammation and deposit in this form of kidney disease, causing thus shrinking and lobulation, or granulation. This, then, is the point to which Dr. Darrach would attract attention, that it is in this form of kidney affection we find the fibrous tissue of the organ much affected. This disease is quite distinct from the large white kidney, and not a more advanced stage of the same affection.

CASE II. The kidney was rather above normal size, consistence firm, smooth on the surface, and pale, and when it was laid open with the knife the cut surface appeared like wax (the demarcation between cortical and pyramidal portions barely discernible) of a uniform yellowish white color, smooth and polished.

This form certainly bears a close resemblance to the lardaceous (bacony) liver; the oily or fatty kidney is also an affection which is too notably allied to oily liver not to be here mentioned.

The more distinct forms of *chronic* kidney affection, commonly classed under the designation of Bright's disease, which have come under Dr. Darrach's observation, are—1st. The lobulated granular kidney, becoming in the last stage very small; met with in persons not especially addicted to drink, nor of a scrofulous nature. The case above referred to having occurred in a man who was a farmer, of good habits, but who had been much exposed to epidemic and endemic influences, having suffered from intermittent and remittent fever. The 2d forms are—*a*. Large yellowish-white kidney, with cortical and pyramidal portions sufficiently distinctly marked, often with yellowish deposits of granular matter in the neighborhood, or in the corpuscles, sometimes having the pyramidal portion reddened, while the interval is of a yellowish color, and again with both portions of much the same hue; *b*. The albuminous, waxy, homogenous kidney. 3d. The oily kidney, which Dr. Darrach has noticed more frequently than in the other cases, accompanied with a corresponding condition of liver.

DR. WOODWARD mentioned, regarding the fatty kidney, that he had frequently seen it unaccompanied by albumen in the urine. In twelve cases of fatty degeneration of the kidney, albumen was only twice or three times present.

Digitized by Google

WEDNESDAY EVENING, Jan. 13th, 1858.

The President, DR. GROSS, and afterward Vice-President, DR. LA ROCHE, in the chair.

Cicatrix and Chalky Formations in the Lungs.—DR. LEVICK exhibited a specimen of cicatrix and chalky formations in the lungs, obtained from a patient aged eighty-two, whom he saw, with Dr. Stroud, at the Widow's Asylum. It was not known that the patient had ever had phthisis. She was latterly very weak and much emaciated, and the impulse of her heart was not distinct; but she died without presenting any remarkable symptoms.

Post-mortem examination.—The heart was found to be very small; it resembled a case of concentric hypertrophy seen by Dr. Levick some time ago; its walls being somewhat thick compared with the size of the cavities. The valves were healthy, excepting the aortic valves, which were slightly thickened by a deposit. A calcareous and atheromatous deposit was observed along the aorta, but did not extend into the large vessels. The arch of the aorta seemed rather dilated. The spleen was very small, firm, and covered with a fibroid deposit. The lungs were of a dark color; at the upper portion of each several calcareous bodies were met with. At the apex of the left lung a distinct cicatrix existed. Dr. Levick had no doubt that the little masses were tubercles which had undergone a calcareous degeneration, and thus the patient recovered.

DR. LEVICK then exhibited a specimen of general melanosis, which had been presented at the last meeting of the College of Physicians. The patient died of cancer of the pylorus. Melanotic masses were found in the lung, bronchial glands, liver, kidney, stomach, lips of the womb, intestines, and gall-bladder.

Dr. Levick spoke of the general tendency to pigmentary deposit in this case.

DR. MITCHELL stated that he had examined a small portion with the microscope, and found cancerous elements and numerous pigment masses and granules.

A discussion arose as to the connection of cancer with melanosis, whether pigment masses might not be extensively deposited without cancer.

DR. WOODWARD believed that they might, although they usually occur associated with it.

DR. STILLÉ thought that the evidence here was strongly in favor of cancer, as there was cancer of the stomach, and as evidently the bulk of many of the masses was not made up of pure melanotic matter, but of a whitish, firm substance.

Urinary Calculus.—DR. DARRACH presented a specimen, belonging to

Digitized by Google

DR. PEPPER, of an oxalate of lime calculus, with projections, similar to the one exhibited at the last meeting, (see Fig. 4.) It was removed after death from a man, eighty years of age, along with several smaller ones. The drawing will give a better idea of its form than any written description can. The smaller calculi were of a yellowish-gray color, smooth, except at points; where there could be perceived, in some quite manifest, in others less so, the same disposition to become bossed as in the larger calculus. All the history which could be obtained of the case is, that the patient suffered very much, and a short time before death had a great deal of pain, which he thought was owing to retention of urine. The physicans were unable to introduce a catheter, and after death the bladder was found about the size of the fist, and its walls much thickened.

FIG. 4.

DR. DARRACH did not believe the calculus had been formed around a foreign body.

Cancer of Cicatrix.—DR. ADDINELL HEWSON exhibited a specimen of malignant fungus, which attacked the stump of a thigh amputated by him some seven months previous, for a large encephaloid tumor growing from the periostium of the lower portion of the os femoris.

The disease had occurred in a lady, aged thirty-eight years, of marked tubercular tendency, and in whose family cancer had never before made its appearance. Most of the immediate family, except her parents, had died of phthisis. Both of her parents lived to an advanced age, and died of diseases peculiarly incident to that period of life. She had early in life several attacks of hœmoptysis. On the first appearance of the disease the symptoms of its malignancy were exceedingly tardy in manifesting themselves; for although she complained of pain in the limb for nearly ten months before it was amputated, it was really not until within about ten days of the time of the operation that a positive diagnosis of the nature of the disease was arrived at. This arose from the previous history of the patient: her appearance and her uncomplaining disposition. She was, as before stated, of a phthisical tendency, but appeared in good health, with a bright, clear complexion. The pain with which she suffered she complained of only occasionally, although she afterward confessed that it had been very constant. This pain was aggravated at night, and increased by pressure, but not by jarring the limb. The thigh continued but little swollen for a long time after the first manifestation of the pain, and there was no venous enlargement or discoloration and glazing of the skin until within a short time of the operation. Her case was, therefore, viewed for a long time as one of idiopathic periostitis, and treated as such; but as it

Digitized by Google

progressed, as the limb became enlarged, the pain more vivid, and the general health impaired, in spite of the treatment resorted to for relief, the accuracy of the previous diagnosis became doubtful, and after several consultations and an exploration with a fine exploring trocar, the conclusion was arrived at that the disease was malignant. The use of the exploring needle really revealed nothing of itself, but greatly aggravated the disease. Previous to its use the tumor was increasing but slowly; after the exploration it grew so as to add half an inch in circumference to the limb in every twenty-four hours. Amputation was performed on the 2d of July, ten days after this exploration. The thigh was removed by the double flap operation, as high up as possible, with the tourniquet applied, and so loaded was the limb with adeps that a catlin nine inches long was just sufficient to transfix it; this was somewhat remarkable, as the patient was neither large nor fat in person. A large amount of blood was lost during the operation, owing to the compression by the tourniquet not being sufficient to arrest the circulation. The tumor proved to be an encephaloid mass the size of a large fist, attached to the periosteum; the bone had been denuded in one place by its pressure. The portion of the tumor which had been penetrated by the exploring needle was very vascular, and presented a marked contrast with the brain-like color and appearance of the rest. Although some erysipelas followed where the skin had been bruised in the efforts to make the tourniquet arrest the hemorrhage, everything did well for a time; the wound all healed up except a little point through which the femoral ligature had been discharged, and the patient was out and riding about, with a pulse between 80 and 90. So matters continued, until about three months after the amputation, when symptoms of a return of the disease showed themselves in the cicatrix. These became more prominent, and the whole scar became gradually involved in large fungus excrescences, which bled freely at times. The patient finally died, exhausted by the disease. Her suffering, however, was at no time after the operation ever so great as it was before.

The specimen exhibited the fungus disease involving the cicatrix through its whole depth. There were no signs of the disease having attacked the bone, which was exhibited with its edge well rounded off. It was, however, found, after sawing it through, to be very vascular. A remarkable circumstance noticed at the autopsy was that the adipose tissue of the stump was as thick as on the day of the operation, although the patient had become emaciated to an extreme degree before her death. This tissue was still two inches in thickness; the other tissues were all wasted away, so that the stump really seemed to consist merely of the bone, adipose tissue, skin, and malignant disease.

Digitized by Google

Exostosis of Scapula.—DR. GROSS exhibited, for DR. KERR, of China, a specimen of exostosis of the scapula, removed from a laboring man, aged sixty years, who was admitted into the Ophthalmic Hospital in Canton, in the summer of 1855, with a bony growth from the scapula, which projected about an inch and a half through the skin, giving rise to a constant discharge of pus. The tumor was attached to the inner border of the scapula, half way between the spine and the inferior angle. Its shape was irregularly cylindrical, three inches long, with a diameter of an inch and a half. One end extended half an inch below the under surface of the scapula, raising this bone that much above its ordinary level; under the end which rested on the ribs a bursa mucosa was developed. So little of the scapula was involved that it was only necessary to saw out a piece two and a half inches long by three-fourths of an inch wide. The patient sank from the effects of the operation, and died on the fifth or sixth day.

Enlargement and Induration of the Pancreas.—DR. STILLÉ exhibited an enlarged and hardened pancreas, taken from a patient aged sixty, whom he had seen in consultation, and who for two years had been suffering from dyspepsia, acid eructations, very dry mouth, deep-seated and dull pain at the epigastrium, vomiting of food, gradual loss of flesh, and during the last six months diarrhœa. No pain in lower part of abdomen. Urine free and appeared normal. During two months or more before death there was gradual emaciation and loss of strength; at one time purpura, which disappeared under the use of mineral acids and iron. Stools of the consistence and color of Indian-meal mush, slimy, and at times three or four a day in number; but generally, under the use of astringents, not more than two in three days. They presented no evidence of containing fat. No tumor of abdomen, nor tenderness of epigastrium, where deep pressure excited only a dull pain. No pulmonary symptoms of note. Some œdema of hands and feet in the last fortnight of life; death occurred by asthenia. Jaundice, it was stated, had at one time been present, but not as a marked symptom; while under Dr. Stillé's observation there was none.

Post-mortem examination.—No visible disease of exterior of bowels. Liver of normal color and size. No examination of viscera was made except of the pyloric end of stomach and of the pancreas; the former was healthy. Pancreas enlarged one-third in all dimensions; hardened. Under the microscope it showed a great increase of fibrous tissue, and in parts a considerable amount of fat.

DR. STILLÉ would not assert that the symptoms arose entirely from the pancreatic disease, particularly since Handfield Jones, after analyzing thirty cases of diseases of this viscus, renders it probable that "no symptoms give any intimation of the existence even of the most advanced pancreatic

Digitized by Google

degeneration," and a similar judgment has been expressed by Dr. Chambers. Dr. Stillé then read an extract from a case published in the *Lancet* of Nov. 10th, 1855, which resembled this in several points. He also alluded to one which he had examined a long time ago, in which acid vomiting, anæmia, with wasting away, were marked symptoms, and in which he thought it probable the symptoms were caused by a chronic disease of the pancreas. In conclusion, Dr. Stillé dwelt on the absence of satisfactory knowledge with regard to the symptoms of pancreatic diseases.

DR. MITCHELL alluded to the experiments of Bernard, who had found an affection of the intestinal villi to follow extirpation of the pancreas.

DR. HARTSHORNE referred to a case of pancreatic disease which had come under his observation many years ago. The symptoms, as far as he could distinctly remember them, were a constant pain in the neighborhood of the epigastrium, dyspepsia, loss of flesh, and vomiting. The man died suddenly, and on a post-mortem examination made with Dr. Van Buren, the pancreas was found enlarged and hardened. Its head was converted into a firm dense tumor.

Cysts from the Liver Coughed up through the Pulmonary Passages.—DR. RICHARDSON exhibited, at the request of DR. F. GURNEY SMITH, specimens of cysts from the liver, which had been given to Dr. Smith by a medical gentleman, who had also furnished a brief history of the case:—

Mrs. A., aged thirty-four; married ten years; without children. From girlhood has had symptoms of diseased liver, which, at intervals of one or two years, have produced acute paroxysms of pain and enlargement, that no treatment affected. Last winter was passed on the sea-board, near Boston, with general health good, but growing tenderness at the hypochondriac region; the side swollen even to distortion of the ribs; much pain, and two very tender spots, one in front, the other on the back, nearly opposite. Numbness in the arm and foot of the right side has been a constant symptom, with inability to lie upon that side. Febrile symptoms were occasional; the natural pulse being about 80, would rise to 95; respiration good.

Early in April last the symptoms of disease became more acute. The swelling of the side, pain, and soreness increased rapidly. Great pain in the top of the head, with acceleration of the pulse took place; for five nights she was sleepless, and rest was only finally procured on the sixth day.

Two days after this, without premonitory symptoms of any kind, there was a large discharge from the bowels of fetid, purulent, and bloody matter, which, continuing for two and a half hours, produced great exhaustion; so great that, for several days following reaction seemed doubtful. The stomach was too weak to retain more than a spoonful of even

Digitized by Google

fluid food, and without nausea rejected almost everything but ice-water. This condition continued for about ten days; extreme emaciation followed; numbness of the extremities of the right side; night-sweats and swollen feet. Cough set in, with expectoration of frothy saliva at first, afterward sputa, resembling those of pneumonia. The tongue had a thick, white coat; the pulse rose to 120, feeble and wiry; the stomach was less irritable. By very attentive nursing the patient commenced to improve, and continued to do so for the next two months, though the same symptoms more or less existed. The months of July and August were passed at Center Harbor, N. H., without much further amelioration, and she returned to the neighborhood of Boston by September 1st. About this time cysts were first coughed up, one, two, or three in a day, of the size of a filbert or less, to that of a pea, all much torn. They have been closely examined by more than one observer, but not a trace of parasite has been found. The discharge of cysts became gradually less frequent, but more numerous and more variable in size. Sometimes, after an interval of five days, twenty or thirty even would be thrown off at one paroxysm of coughing, that lasted two or three hours. More recently these paroxysms have occurred once in ten days, and the cysts are discharged during perhaps the whole of two days. Some have been so perfect as to have but one small aperture, and have been inflated by the blow-pipe; some smaller than a pea have come up unbroken, but soon after collapsed. Their contents are apparently purely serous, though the same thick expectoration accompanies them as at first. With few exceptions, the walls of which are translucent, the cysts are opaquely white, and under the microscope exhibit only occasional striæ.

The present condition of the patient is with much less pain and suffering than she had last winter, though with less strength and more difficult respiration. She is able to go out in good weather, and takes the usual exercise in the house. Some numbness of the limbs and considerable soreness of the chest remains. The sputa contain some clots of blood. The paroxysms of coughing are exhausting, violent, and spasmodic, resembling hooping-cough.

DR. HARTSHORNE, in reply to a remark from one of the members of the Society, who considered the symptoms as inconclusive by which the hepatic origin of the cysts was attempted to be proved, supplied, from his knowledge of the case, some facts not dwelt upon in the report, especially with regard to the purulent diarrhœa. He also stated that the patient had been, and was being, narrowly watched by several physicians in Boston, who were satisfied of the hepatic origin of the cysts, and would give to the profession the full particulars of this interesting case.

Digitized by Google

WEDNESDAY EVENING, Jan. 27th, 1858.

The President, DR. GROSS, in the chair.

Cyst Expectorated from the Lung.—DR. STILLÉ exhibited a cyst about three-fourths of an inch in length, pyriform in shape, and containing a fluid of a yellowish-red color. It was expectorated, not long before death, by a patient of Dr. Gilbert, a man whose main symptoms were great emaciation and cough, and who presented the physical signs of dulness on percussion, and a feeble respiratory murmur on the right side, at the apex of which gurgling also existed. Tubercle was thought to be present, but no post-mortem examination could be obtained, so as to permit the exact condition of the lungs to be stated.

DR. RICHARDSON had seen the cyst shortly after it was coughed up; it was then flat, and not filled with fluid. He considered it an acephalocyst.

Softening of the Gray Matter of the Cerebral Convolutions in a Child thirteen years of age.—DR. MITCHELL exhibited a specimen of chronic inflammation and softening of the gray matter of the cerebral convolutions in a child thirteen years of age. The subject from whom this specimen was taken was one of fifteen children, born within a period of sixteen years—the mother having twice had twins.

J. D., when five years of age, was a handsome, intelligent child. At this time he began to see dimly, and at last became entirely blind, from what was believed to be amaurosis. When nearly blind, he began to show a loss of power to fix his attention, and at length, within six years, became completely idiotic. One year ago he was attacked with epileptic fits, which succeeded one another at less and less intervals, until they destroyed his life. Paralysis of the left side, and violent convulsions of the right side, preceded his dissolution. During his idiocy he retained the power of singing, and sang several songs very well, even a few days before he died. He also retained the ability to learn new music, although he mumbled the accompanying words, and evidently attached to them no definite meaning. All other mental effort seemed impossible. His temper was peevish and sullen, and a more pitiable object can scarcely be conceived of.

On post-mortem dissection the following appearances were observed:—Head well developed; body and limbs thin; large ulcer (bed sore) on the sacrum. On opening the head, adhesions existed along the line of the great longitudinal sinus, closely glueing the membranes together; the deposits

Digitized by Google

were of comparatively recent origin. A large amount of serum was found within the membranes, and the brain, compressed and shrunken, did not fill the cranium. With this exception, the upper surface of the organ was healthy, although the membranes were more than usually vascular. Below the middle line of the brain, and principally in the middle and posterior cerebral lobes, were many spots where the surface was a little flattened. On cutting into these, the knife passed through a layer of gray cerebral matter which adhered to the membranes, and then entered a cavity whose walls were ill defined. This cavity was thus bounded on all sides by gray matter, and followed the irregular curves of the convolutions. It contained altered blood discs, brain cells, fragments of nerve tubercles, nuclei, compound granular masses, cholesterin plates, and quantities of granular matter, with occasional fragments of pigment. On careful inspection, the external gray matter of the cerebral convolutions offered, nearly everywhere, some stage of the process whose completed results we have just described. The first stage seemed to be a red line of inflammation just within the external limits of the vesicular neurine. In the later periods of change, this appearance was lost in the complete destruction of tissue which followed. No cause was seen to account for the early amaurosis, and an examination of the retina was denied. The child died, therefore, from chronic peripheral encephalitis with extensive serous effusion.

Ossification of Arteries in a case of Dry Gangrene.—DR. MORTON exhibited a specimen of partial ossification of the aorta, right iliac, femoral, and complete obstruction of anterior tibial artery, taken from a patient who died in the Pennsylvania Hospital, of dry gangrene of foot; the disease ran its course in about three months; the vessels of the left side were perfectly healthy.

Strangulated Hernia.—DR. MORTON also exhibited a specimen of strangulated hernia, and read the following history of the case:—George Hirst, aged twenty-six, married, was admitted into the Pennsylvania Hospital on January 22, 1858, with symptoms of strangulated hernia. He stated that he had been quite well until the Wednesday previous, when riding on horseback he felt sharp pains in his abdomen; he soon returned home, and after taking laudanum went to bed. The pains continued, and were soon followed by vomiting, which continued all Wednesday; on Thursday he was the same, but with cramps more violent; he then sent for a physician, who did not arrive until Friday morning, when he examined him, and advised his being brought to the hospital, where he arrived about 2 o'clock P.M. On examining the patient I found great tenderness of the abdomen, and a large scrotal hernia on the right side, which

Digitized by Google

was very painful when touched; he stated that his right testicle had always been larger than the left, and that his bowels had not been opened for six days, with the exception of a small passage on Thursday morning. He was placed in a bath, temperature 110°, and an attempt at reduction was made, but failed. Another attempt soon after succeeded better; for the tumor disappeared under the taxis, and seemed to be entirely reduced with the exception of a swelling about the size of an egg, which was no more than a collection of fluid in the sac; since by placing the fingers rather lightly just above the swelling, the fluid could be pressed into the superior portion of the sac. The finger passed up could now feel distinctly the edges of the internal ring; the patient, feeling himself much relieved, was carried into bed, and an injection given. This soon came away, followed shortly afterward by an evacuation of at least a quart and a half of dark-colored fæces. He now felt so much relieved that he fell asleep, and had but occasional vomiting until 10 o'clock P.M., when it again become more frequent.

DR. PEACE saw him at 7 o'clock, P.M., and ordered him a dose of oil, which he vomited, and warm fomentations on the belly; he considered him in a favorable condition, and did not think there was any gut in the ring, but left directions that if symptoms of strangulation became marked, to call a consultation of the surgeons of the Institution early in the morning. At 6 o'clock A.M., the next day, the patient commenced vomiting much more frequently, and soon fecal matter was thrown off; he was soon seen by the surgeon of the house, who, not feeling any obstruction in the ring, thought that the symptoms were caused by an aggravation of the inflammation, or by an internal stricture. At 10 o'clock A. M., the man's skin was cold; belly somewhat tympanitic and tender; scrotum had diminished in size since yesterday. An operation was not thought advisable. He continued to vomit the same way all Saturday, gradually becoming weaker; had voided only about 4℥ of urine since his admission; on Sunday he was delirious; died at 1 o'clock P.M.

Post-mortem Examination.—The intestines were found much inflamed and dark colored, with patches of effused blood here and there, but no lymph, nor any effusion in cavity. On opening the scrotum about two ounces of a thick fluid escaped, of a dark color. The scrotal sac was very large, and seemed as if it had been distended; on running the finger up the cord, a knuckel of intestine was unexpectedly discovered at the internal ring; the intestine was perfectly empty, and quite flabby, and the finger could also be passed around the edges of the ring: the intestine sliding under, and before the finger, gave the impression that no gut existed there; the protuding portion was a piece of the ileum, not far from the cæcum; one side of the gut was attached by bands to the edge of the ring, while

Digitized by Google

the other was quite free, and could be drawn within and without the ring. The probability is that it was an old congenital hernia, capable of partial reduction. The hernia, which was scrotal at the time of his admission, was reduced, with the exception of the small attached portion at the internal ring, which probably had always remained outside, without giving any trouble. The alleviation of his symptoms for the time, and the free evacuation, would be still accounted for; the inflammation continuing, the strangulation finally became more marked.

Aneurism of Arch of the Aorta.—DR. GROSS exhibited a specimen of aneurism of the arch of the aorta. The patient, a man aged thirty-seven, had always been in ill health, yet the disease appeared to be only of six months' duration, as far as it had attracted attention. Latterly the marked symptoms were great prominence of the upper portion of the chest; a pulsating tumor; immense difficulty in breathing; an anxious countenance; and great emaciation. About six weeks before death an abscess pointed near the median line, and in three days after it burst and discharged sanious matter; but the immediate cause of death was the opening of the tumor into the pleural cavity.

Autopsy.—The right lung was adherent to the tumor and hepatized; the pleura was thickened, and contained at least a quart and a pint of coagulated blood; the pericardium was adherent to the heart; left lung adherent, and some effusion in left pleural cavity; there was extensive degeneration of the tunics of the tumor; valves of the heart were normal; the orifice of aorta somewhat dilated. The aneurismal pouch was one and a half inches above valves, and contained fibrinous concretions partially organized. The sternum at one place was absorbed, and several ribs had given way; the arteries at the root seemed healthy; innominate artery somewhat dilated; the trachea was not compressed.

DR. HEWSON had seen a case of aneurism of aorta which terminated favorably. The tumor, which could be perceived to pulsate across a room, had eaten its way through the sternum; an abscess, which resulted from caries of the sternum, opened, bone was discharged, and the aneurismal tumor then gradually disappeared. He saw the man two years afterwards, and he was quite well. The case was probably familiar to the members of the Society.

Erectile Tumor from the Orifice of the Urethra.—DR. PACKARD exhibited a microscopical drawing of a portion of a tumor, removed by him from the orifice of the urethra. The patient, a married woman, aged fifty-two, mother of eleven children, the youngest being now eleven years old, has had hysterical symptoms, headache, debility, &c., for two years, with

Digitized by Google

great pain in urinating. On an examination of the external genital organs, a very florid growth about the size of a lima bean, compressed laterally, and finely lobulated, was found springing from the opening of the urethra, within which its pedicle was attached. It was extremely sensitive, very soft and compressible, but the mucous membrane covering it was tough, so as not to be torn when the tumor was seized with forceps. A ligature was applied to the pedicle, with the effect of cutting directly through it; free bleeding ensued, which was, however, soon checked by dry lint. After soaking in water for hours, the tumor became blanched, and its lobuli less apparent. Examined by reflected light, with a magnifying power of forty diam., it showed an arterial twig ramifying near the surface. In making a section of it, the slice obtained broke down by pressure on the thin glass cover, and the following elements were observed with a power of 360 diameters:—

1. A few squamous epithelial cells.

2. A great many caudate, elongated, granular cells, with large nuclei, sometimes two in one cell, and one or two nucleoli in each nucleus.

3. A great many cells, like those represented by Vogel as seen in "recurring fibroid" tumors.

4. Several wavy masses, somewhat like involuntary muscular fibres, apparently composed of bundles of longitudinal fibrillæ, with here and there a very faint semblance of a nucleus; little change induced by acetic acid.

Dr. S. W. Mitchell, who had examined a portion of the tumor, saw the same elements, also a few nerve tubules. These growths are interesting, from the fact of their frequent occurrence and excessive sensibility, neither of which are accounted for by authors. In the present case there seemed to be no reason to suspect any gonorrhœal or syphilitic affection.

As to their nature, Vogel and Gross place them among the erectile tumors; Rokitansky calls them fibroid, describes them as formed of lax cellular tissue, derived from submucous, and evidently ranks them among polypous formations. The analogy of some cells in this tumor to the confessedly malignant "recurring fibroid," with the known tendency of these sensitive tumors to reappear, together with their alliance with polypus tumors of the nose and antrum, which so often assume a malignant character, would seem, perhaps, to establish something like a chain between simple and malignant growths.

DR. DARRACH examined two erectile tumors some time since, and could find no nerve fibres, although they were exceedingly sensitive.

DR. WOODWARD remarked, in relation to the drawings of the cells of Dr. Packard's case, that the cells resembled those seen in new forming connective tissue. They look like the cells about to multiply by division, seen in new growths of the connective tissue.

Digitized by Google

Aneurism of the Innominata.—DR. HUMPHREYS submitted the following:—John Sweeny, aged thirty-eight, was admitted into the Pennsylvania Hospital Nov. 24th, complaining of a cough which had lasted three or four months, accompanied by a puruloid sputum. He was rapidly losing flesh; suffered from hectic; had occasional attacks of dyspnœa, together with other rational signs of phthisis. The physical signs were not so satisfactory. There was no marked dulness upon percussion anywhere. The respiration was exceedingly roughened throughout the chest, and at the apex of the right lung, bronchial and almost cavernous. The pulse was about natural on the left side, but was wanting on the right. The patient was placed upon the usual treatment for phthisis. About Dec. 20th he began to complain of increasing difficulty in respiration. On the evening of the 23d the dyspnœa increased alarmingly, and about 12 P.M. the patient died suddenly, while sitting upon the close stool.

Autopsy.—The lungs were sparsely scattered with tubercles, a few of which were softened. The bronchi, trachea, and larynx were completely filled with pus, which, during the removal of the lung, was also ejected from the mouth. The heart seemed natural, as did also the aorta, but at the junction of the innominata an aneurism, of about the size of a goose egg, arose, involving the whole of that artery. The whole of the aneurismal sac was filled by dense concentric layers of clot, so as completely to obstruct the flow of blood into the axillary and carotid arteries of the right side. Posteriorly the sac was adherent to the trachea, and at this point, between the trachea and the solidified aneurism, the remains of an abscess were found, capable of holding some two or three ounces of pus, and which had discharged itself through a small opening in the anterior wall of the trachea, thus filling this and the bronchi with pus, and producing suffocation and death. There had been no hæmoptysis, nor any discharge of blood whatever, so that the death of the patient must be entirely attributed to the suffocation produced by the effusion of pus into the air passages, and not directly to the aneurism, as at first might have been supposed.

Calcareous Deposits in Pleura.—DR. DARRACH presented a specimen of calcareous deposits in subserous tissue of the pulmonary pleura at the apices of both lungs, with history attached.

DR. DARRACH also exhibited a pneumonic lung:—Mrs. ——, aged thirty-three years, sick ten days, got out of bed some time after retiring, and went down stairs; when she returned to bed she was seized with a chill, and afterwards had great pain in the side, with cough. This occurred on Friday, Jan. 15th. I saw her, for the first time, on Saturday, Jan. 23d.

Symptoms.—Anxious expression of face, purplish lips, panting respi-

Digitized by Google

ration—44 in a minute; pulse almost imperceptible, intermitting, irregular, and very frequent; excessive pain in the right side.

Physical signs.—Flatness anteriorly on the right side, blowing respiration, prolonged expiration under clavicle; posteriorly very dull, voice hard, no aegophony, no blowing respiration. Left side very resonant, purile respiration, slight mucous rale posteriorly low down.

Treatment.—Antimony, calomel, blister.

Jan. 24th. Breathing freer, pain greatly relieved, pulse unembarrassed—160 beats to the minute, feels stronger. There was not much change after this, excepting that the percussion became clearer, the respiratory murmur increased, and the blowing respiration ceased over the middle anterior region on the right side. The left side remained clear up to my visit on Tuesday, Jan. 26th, with exception of slight dullness very low down posteriorly; hands clammy, anxious. Died at 2½ A.M. on the 27th.

Sectio cadaveris.—Effusion into both sides of chest and into pericardium; left lung had no adhesions, congested, shriveled-looking, probably from compression of the fluid. Right lung adherent anteriorly by a thick yellowish false membrane, slight adhesions laterally and posteriorly, gray hepatization of most of the upper lobe anteriorly; posteriorly the whole lung was very much congested, lower part anteriorly œdematous.

Microscopical examination of the gray hepatization.—Fibrous tissue of lung appeared healthy; the field of the microscope was covered with cells filled with oil, consisting, likely, of both lymph corpuscles and lung cells.

WEDNESDAY EVENING, Feb. 10th, 1858.

The President, DR. GROSS, in the chair.

Cancer of the Great Omentum, of the Smaller Curvature of the Stomach and of the Pylorus.—DR. DARRACH exhibited a cancer of the great omentum, cancer of the smaller curvature of the stomach and of the pylorus, atrophy of the gall bladder, fatty liver, oily degeneration of muscular tissue of the heart, atheromatous deposits in aorta, on mitral valves, and in splenic artery, peritonitis, hypertrophy of the uterus, yellow nodules on ovaries, (probably cancerous,) all obtained from the same patient, a Mrs. ——, aged sixty-six years, born in England, a widow. She was a woman of ruddy complexion, a good liver, indulged in malt liquors; she was of full habit, had been in ill-health for a number of months, and came under the care of Dr. Beesley eight days before death. The symptoms then were frequent vomiting of all she swallowed, (never retaining food for more than three hours, and frequently only for one hour;) pain in region of stomach, which subsided under treatment; abdomen was not tender to touch; laid straight in bed, no evidence of tumour or internal

Digitized by Google

hardening; walked about until three days before her death; insensible for the last twenty-four hours of her life; still vomiting, lost all strength, great nausea, burning pain in stomach, thirst. The treatment consisted in tinct. aconiti, rad. gtt. ij, which relieved the pain, given four times daily; bowels were not opened for eight days previous to death.

Sectio cadaveris.—General appearances: skin clear, ruddy-looking, no rigor mortis. Thorax—heart flabby, fat concealing muscular structure of right ventricle; aorta and pulmonary artery somewhat dilated; muscular tissue of left ventricle pale; slight atheromatous deposits in aorta and on mitral valves. Lungs extremely congested, posteriorly and inferiorly, especially the left, (looked like apoplexy.) Abdomen—peritoneum, over bowels and abdominal walls, much injected; no effusion of lymph. Stomach enlarged, a few tubercular-looking deposits along the greater curvature, near the pyloric end, and on the peritoneal coat; lesser curvature puckered up, and closely and firmly attached to under-surface of the liver at the transverse fissure and the fissure for the gall bladder; cancerous deposit at the lesser curvature, near the cardiac end of stomach, and also at pylorus, the latter causing stricture of that orifice; the little finger could just pass through. The deposit at the pylorus was at the upper part, the situation of both deposits being between the muscular and mucous coats; the muscular coat was much thickened, the mucous coat moderately rugous, and covered with small points of ecchymosis. Great omentum was contracted and thickened from its attachment to transverse colon downward; edges thick and rounded; surface covered with nodular tumors, from the size of a pin's head to a small cherry, and of a yellow color; veins of omentum much congested and contorted; fine capillary congestion between the yellow nodules, giving it a very beautiful appearance. Liver; brownish-yellow color—gall bladder about the size of the little finger, with a cavity which would scarcely admit a crow-quill; this atrophy of the gall bladder no doubt was produced by compression, caused by the lymph which was deposited between the liver and stomach, and bound the stomach closely and firmly to its lower surface. Spleen healthy, arteries atheromatous. Kidneys large, pale; supra renal capsules large, softer than normal. Bowels dark-looking, mucous membrane much congested. Mesenteric glands unaffected, as far as examined. Uterus hypertrophied; cavity of cervix filled with a tenacious gelatinous substance; follicles much enlarged, and filled with the same glairy substance. Ovaries full size; each had a small nodule of yellow matter on its surface, of a cancerous nature. Veins of all the organs were filled to a marked degree with black fluid blood; so was the right side of the heart.

A microscopical examination of the deposit in the omentum and stomach exhibited marked cancer cells.

DR. LEVICK inquired whether the splenic artery was not particularly

Digitized by Google

liable to deposits in, and degenerations of its coats. He had seen the splenic and brachial, and the splenic artery and aorta, diseased in cases, in which the other arteries in the body had been perfectly healthy.

DR. GROSS remarked that the splenic artery is more frequently ossified than any other visceral artery. The hepatic and spermatic arteries are seldom or never thus affected.

Encephaloid of the Right Testicle.—DR. DARRACH also exhibited an encephaloid cancer of the right testicle, removed from "Mr. ——, aged thirty-five years, single, a farmer, strong, muscular, free from the most remote hereditary taint, of perfectly regular life and habits. To his certain knowledge there has not been cancer in the family for five generations; has noticed, as long as eight years ago, that the right testicle was larger and harder than the left; it has slowly and steadily grown; was painless even on pressure, till within the last few months, when it has had at times a dull aching pain in it, and a feeling of dragging, though a supporter had been worn. From the first the testicle has been equally enlarged, though perhaps the body was rather in advance of the epididymus; surface has been regular, not tuberculated, firm, and latterly almost long in feel over the upper part of the epididymus. Within a few months, a spot on the upper and anterior part of the tumor fluctuated. The cord had always been somewhat enlarged, but was apparently perfectly healthy. On cutting down to it, some fluid escaped from a small unobliterated portion of the tunica vaginalis sac, (which had caused the fluctuation,) leaving the tumor solid." The testicle or tumor was oval, flattened somewhat from side to side, did not cry under the knife; the cut surface marked by fibrous-looking bands, studded with yellow substance, and when cut deeply into, the section presented is of a mottled-red, white, and yellow color. On microscopical examination no trace of the seminal tubes could be found. By pressure, an abundant creamy juice could be obtained, which consisted almost entirely of large characteristic cancer cells. The yellow matter was mostly composed of large cancer nuclei, and cells undergoing oily degeneration, with crystals of cholesterin.

Enlarged Liver and Spleen.—DR. STILLÉ exhibited an enlarged spleen and part of a liver, obtained from a post-mortem examination at which he was present. The person, he was informed, a man fifty years of age, and of intemperate habits, was attacked with abdominal pain some months ago, which was followed by dropsical effusion in the extremities and abdomen. Percussion showed the spleen to be enlarged. The urine did not contain albumen, but it was stated by the patient that some time previous to his last illness he had been treated by a physician for diabetes,

Digitized by Google

and recovered. He had never suffered from intermittent fever. The impulse of the heart was augmented. The dropsy increased, and the patient gradually sank.

Post-mortem examination.—The feet and legs were enormously distended. Three gallons of fluid were found in the abdominal cavity. The *liver* was enlarged, and cirrhosed on its under surface. The *spleen* was large and firm; its capsule was dense and opaque, and on it were two white spots the size of a dollar, and of cartilaginous consistence. The *heart* was in a state of dilated hypertrophy; its walls fatty; its valves healthy. One kidney was perfectly healthy, the other was not examined.

DR. FISHER commented on the fact of the diabetes having disappeared. He had observed a case in which the patient had suffered from diabetes, but entirely recovered, and which now exhibited, as in the case just presented, signs of hepatic disease.

DR. DARRACH believed that diabetes occurring at an advanced age, was frequently quite tractable to treatment; sometimes the sugar disappears from the urine to reappear. He spoke of a paper by Jones on the Intermitting Diabetes of the Aged. He had now a case under treatment, in which, for two weeks, no sugar had appeared in the urine.

DR. LEVICK remarked that the liver before them was interesting, in being a case of enlargement, with marked cirrhosis. Dr. L. had seen several cases of marked granular liver, accompanied by enlargement of the organ.

WEDNESDAY EVENING, Feb. 24th, 1858.

The President, DR. GROSS, in the chair.

Atheromatous Deposit in Arteries; Calcareous Deposit at Apex of the Lung; Degeneration of the Pancreas.—DR. R. P. HARRIS exhibited a specimen of atheroma of the aorta, disease of the pancreas, and calcareous deposit at the apex of the lung, taken from the body of Mr. K., aged fifty-two, of medium height, and sanguine temperament, who was attacked in July, 1857, with what he supposed to be dyspepsia, which was accompanied by nausea and occasional vomiting. He had no fever; did not lose much flesh, and had no symptoms indicatory of inflammatory action. After a sojourn of several weeks at the sea-shore without benefit, he returned to Philadelphia, and placed himself in the hands of his family physician, who subsequently called in the aid of one of his medical brethren in consultation.

At the time he applied for medical aid, he had, together with the nausea before mentioned, hurried respiration, pain in the region of the diaphragm, an inability to inflate the lungs without the production of a short, dry cough, attendant with pain in the epigastrium, an accelerated pulse, and

Digitized by Google

a spasmodic cough. The sounds of the heart were natural, and pressure upon any part of the abdomen gave no immediate pain, unless force enough was used to create pressure upon the diaphragm.

As the disease progressed, the physical signs showed the existence of dropsy in the chest, but nothing special was detected at any time in the lungs themselves, which probably became affected subsequent to the effusion into the cavity of the pleura. The dyspeptic symptoms increased; vomiting became more frequent; effusion into the abdominal cavity occurred, and the legs became anasarcous. The urine, upon examination, was darker colored than natural, (sp. gr. 1012,) and yielded a considerable amount of albumen when boiled and subjected to the action of nitric acid.

Finally the state of the patient became more alarming, from occasional attacks of violent dyspnœa, vomiting, expectoration of bloody sputa, continued difficulty of breathing, drowsiness, prostration, &c. Death took place very gradually, the patient being moribund for two or three days. Respiration became more and more labored; no food was taken; cough ceased (ten days before death;) anasarca diminished slightly; and patient was very drowsy, though not comatose.

From the anasarca, albumen urea, vomiting, and epigastric pain, the disease before death was supposed to be granular kidneys, with perhaps cirrhosis of the liver.

Autopsy, Feb. 16th, thirty hours after death.—Cartilages of ribs ossified, except those of first and second. Pericardium contained about f℥ij. of brownish serum. Heart somewhat enlarged; coronary veins distended, but not ossified. Auricles healthy; secondary pouch in right auricle with very thin walls. Ventricles hypertrophied; left ventricle contained one columna cornea of very large size. Tricuspid valve healthy. Mitral valve slightly thickened with a small cyst upon the opposing surface of the right flap. Both sets of semilunar valves healthy; pulmonary artery the same. Aorta dilated and irregularly studded with atheromatous deposit; primitive, external, and internal iliacs the same. Right lung about half its natural size, strongly adherent to the diaphragm, of a blackish color, covered with deposits of greenish-black disorganized lymph. This lung was entirely hepatized. Left lung hepatized, except at the upper and anterior portion, where it was crepitant, and of a lighter color than the remainder. This lung was much larger than the left. At the upper surface, beneath the clavicle, there was a strong adhesion, in separating which a calcareous deposit was felt, and found upon examination to be imbedded in the substance of the lung, and to extend also into the adhesive band. Pleura contained a considerable amount of dark bloody serum. Liver healthy. Spleen small; marbled light and dark green; lobulated upon the surface; appeared healthy upon incision. Under the microscope,

Digitized by Google

presented no very remarkable appearance; a preponderance of white corpuscles. Right kidney larger than the left; both somewhat congested; cones of the left more pointed than natural. Supra renal capsules healthy. Pancreas smaller than natural; dark colored; almost cartilaginous under the knife; presented fat globules under the microscope.

Enormous Fibro-Fatty Tumor of the Abdomen.—DR. GROSS exhibited a portion of a tumor removed, post-mortem, from the abdomen of a man about forty-six years of age. The weight of the entire mass was 74½ lbs. It had been gradually growing for five years, and did not prevent the patient—a superintendent of a foundry in the northern part of the State of New York—from attending to his business, until four weeks before death. The mass, microscopically examined by Dr. Leidy, to whom Dr. Gross was indebted for the specimen, was found to consist of adipose tissue, with fibrous tissue, yellow fibro-elastic tissue, and some bone.

Tubercle of the Kidney.—DR. GROSS exhibited a specimen sent to him by Dr. R. J. Levis, of tubercle of the kidney. The patient, Mrs. L., aged twenty-two years, had complained, since a recent pregnancy, of various symptoms not referable to any particular organ, such as debility, slight œdema, neuralgic pains, and nervous irritability. There was slight cough, with profuse mucous expectoration, and the patient finally died, exhausted by a diarrhœa, which attacked her occasionally a short time previous to her death. Her attending physicians, Drs. Jewell and Spencer, state that there had not at any time existed any symptoms of renal disease. The urine, although not minutely examined, presented at no time anything to lead to its particular investigation.

Autopsy.—Body much emaciated, without any œdematous appearance. Right lung tuberculous, with some softened tubercles, and one suppurating cavity. Left lung free from tubercular deposit, and healthy. Heart normal in appearance, but there were about five ounces of fluid in the pericardium. Liver healthy, without any tubercular deposit. Large intestine extensively studded with granular tubercles, and its mucous surface much ulcerated in small patches throughout its whole course. The right kidney was larger than usual, but free from tubercles, and generally healthy. The left kidney was enormously large, and abnormal in its position, being elevated and prominent toward the front of the abdomen. Within its cavity was about a pint of clear serous-looking fluid, without urinous color or odor, distending the pelvis and calices of the organ. The ureter was impervious near its cystic extremity. Masses of tubercular matter varying in size, one nearly an inch in diameter, were scattered through the kidney. The bladder was sound.

Digitized by Google

Fracture of Cervical Vertebræ.—DR. MORTON presented several fractured cervical vertebræ. The patient, a young man, aged nineteen, was admitted into the Pennsylvania Hospital in the month of January, 1858, for an injury to the head and neck, occasioned, as in a case previously shown, (see *Proceedings*, Nov. 25th, 1857,) by falling into the hold of a vessel and striking the back part of his head and neck. On admission he had symptoms of concussion, great pain in the back of neck, priapism, entire loss of sensation and motion from his arms down. His neck had the appearance of being dislocated; it seemed shortened, and the head thrown forward. His water was drawn from him for the first thirty-six hours, after which his fæces and urine passed from him involuntarily until his death, which took place on the tenth day. He remained perfectly conscious until a short time before his death.

On post-mortem examination, the bridge which connects the spinous and oblique processes of the fourth cervical vertebra was broken through; its body was also split. The bridge of the fifth was broken in the same way as the fourth, and its body split through and through. The right side of the vertebra was dislocated anteriorly, the oblique process had slipped forward and over that of the sixth. The body of the sixth was split entirely through and through. The spinal cord was pressed upon in several places, and large clots of blood could be drawn from the canal.

DR. HEWSON drew attention to the fact of the patient having lived nearly eleven days after the occurrence of the fracture. He had seen a patient who received an injury to the back, which caused the fracture of his fourth, fifth, and sixth dorsal vertebræ. This patient lived three months after the accident. There was an angular projection and displacement at the seat of fracture The fifth or sixth dorsal vertebræ were found to be pressed downward, obliterating the spinal canal. A bony growth had been thrown around the seat of fracture.

Suppuration and Enlargement of the Kidney.—DR. HALL called the attention of the Society to a specimen of abscess of the kidney.

The patient was a thin, ill-looking, anemic young woman, twenty years of age, a shop-girl by occupation. She was admitted, March 17, 1857, into the Pennsylvania Hospital, under the care of Dr. Pepper, for "vaginitis." She stated that she had been sick eight weeks with "pain in her privates," and a scalding when she made water. A fall from a chair was the cause assigned by her for the discharge and pain. The discharge from the vagina, with concomitant circumstances, was such as to warrant at least a *suspicion* of its specific origin. The girl herself, who was single, was either by nature exceedingly slow of intellect, or else by design kept to herself any information that she might have to communicate.

Digitized by Google

She never spoke unless spoken to, and then replied briefly and petulantly, which may be mentioned to account for the meagre history of the case. She was placed upon a tonic and specific treatment, with a nutritious diet.

March 27th. Fever, hot skin, flushed cheeks, accelerated pulse passed off in three days, under appropriate treatment.

April 10th. The vaginal discharge had ceased. She was terribly emaciated. Ol. morrhuæ was ordered, in hopes of fattening her, and used for three months without benefit, then discontinued from the nausea caused by it. Auscultation and percussion revealed no disease of the lungs. The urine, on standing a little while, let fall a thick, creamy, yellowish opaque deposit to the bottom of the vial. This deposit, under the microscope, presented the appearance of pus granules, and the addition of liquor potassæ produced its peculiar action. The amount of urine passed in the day was normal; the specific gravity also. No albumen could be discovered in it from time to time; no hæmaturia while under observation. To remove all doubt as to the source of the pus, a specimen of urine, drawn by catheter from the bladder, was subjected to examination. This produced the same results. The pus was thought to come from the kidney. A circumscribed tumor, dull on percussion, in the left hypochondriac space, could be felt on relaxing the muscles of the thigh and abdomen. Posteriorly, the tumor presented a slight bulging externally. It was painful upon firm pressure being made on it. As symptoms of exhaustion began to show themselves, milk-punch and wine were added to the treatment.

July 16th. The patient at this time presented typhoid symptoms which, however, seemed readily amenable to treatment, temporarily at least. The tumor remained as at last notice, neither diminishing nor showing any signs of marked increase.

July 24th. So far the patient has been remarkably taciturn, but fretful when moved in bed. Now, she seems more indifferent to matters around her. Sleeps most of the day and night. Has involuntary discharges from the bowels and bladder. She now most plainly begins to sink. There were frequent spells of vomiting, the matter ejected being of a glairy, brownish nature, at times nearly of a chocolate color. The patient continued to sink, and died August 17th.

Autopsy ten hours after death.—Body more emaciated than Dr. Hall had ever beheld before—the thighs could be spanned by the thumb and forefinger. Cadaveric rigidity not well marked. Head—there was from f℥iv. to f℥v. of serum in the sac of the membranes, and in the lateral ventricles. There were no changes in the brain substance. Thorax,

Digitized by Google

heart, and great vessels perfectly healthy. Lungs perfectly healthy, but exceedingly pallid, floating like a cork in water. Liver merely pallid. Spleen normal, if anything rather small. Right kidney smaller than usual, somewhat congested; right ureter healthy. Left kidney very much enlarged, looking like a large oblong tumor, as it laid in the left lumbar region; it was raised with difficulty from its bed, being bound down firmly to the surrounding textures. The capsule of the kidney was firm and dense, cutting like cartilage, produced, it was thought, by chronic inflammation. In removing the organ, an accidental cut was made across the ureter, close to where it emerges from the kidney; a few drops of curdy pus protruded from the orifice. The kidney measured seven and a half inches in length, and weighed fifteen ounces—nearly three times its natural size and weight. On making a section of the organ, it at first appeared to be one mass of pus; but on washing away some of this, its structure did not appear to be entirely destroyed. The cortical portion was that most affected; in it were several abscesses of different size, the largest probably as big as a walnut. The cavities of these abscesses were ragged and sloughy; the tissue a little beyond and around them was condensed and hardened. The tubular portion of the kidney appeared to be comparatively little involved. The left ureter was enlarged to twice the size of its fellow, and its coats were thickened; it was pervious throughout its course. The urinary bladder presented spots of injection on its mucous membrane. Uterus presented nothing peculiar. The left ovary contained a large cyst. Vagina—traces of inflammation, deep-red injection, especially near the os uteri; there was no hymen.

This case presents many points of interest. In the first place, the possibility of the communication of the inflammation from the vagina to the bladder, thence by the ureter to the kidney, thus producing the mischief that resulted in death. Secondly. The absence of albumen in the urine, as examined from time to time; the normal specific gravity always exhibited; the natural quantity of urine passed in the day. Thirdly. The absence of œdema, or dropsy of the lower extremities. Also the absence of constitutional irritation in proportion to the amount of disease present. Also, the form and character of pain were not such as the gravity of the lesion would seem to warrant.

A point that should further not be overlooked, was the small size of the right kidney, considering the double service that it had to perform, the left kidney being totally useless as an excreting organ. That it, the right kidney, was not hypertrophied is a matter of great surprise.

DR. LEVICK stated that he remembered the urine in the case just reported by Dr. Hall to have contained pus. Toward the close of her

Digitized by Google

illness, a swelling was observable over the region of the kidney. The specimen he had believed, when he examined it, to have been a scrofulous or tuberculous kidney.

DR. GROSS thought the kidney had more the appearance of encephaloid, than either of suppurative nephritis or of tubercle. Simple suppuration would not present the organ so much increased; for tubercle, also, the kidney is too voluminous, and the absence of tubercle in other organs is against its being such. Dr. Gross then inquired if any members of the Society had observed tubercle of the kidney unassociated with that of the lung. He had seen a case of this kind, in which the left kidney alone was the seat of the disease. There was a psoas abscess, and five ulcers were found in the urinary bladder.

DR. LEVICK also mentioned a case affecting only the left kidney.

DR. DARRACH had had two cases of tubercle of the kidney come under his notice, in one of which no tubercle at all existed in any other organ of the body, while in the other there were some scattered miliary tubercles in the lung. In the first case, one kidney only was found to be affected. The urine contained a heavy deposit, which, when examined with the microscope, showed corpuscles like those of tubercle, and having the same reaction with acetic acid. In the second case, there was extreme diuresis, and no evidence of tubercle in the urine.

Dilatation of the Heart; Insufficiency of the Tricuspid Valve.—DR. PACKARD made the following remarks on the pathological appearance of a case of extensive dilatation of the heart, accompanying disease of the tricuspid valve:—

A boy, aged sixteen, had been troubled with a slight cough for several years; according to the account given by his friends, he never had suffered from rheumatism; he had, however, always been somewhat weakly. Owing to circumstances, I had only the opportunity of making an autopsy, without having examined him during life; and these notes are presented simply because the lesions described therein have seemed to me difficult to explain.

Autopsy twenty-six hours after death.—Rigor mortis well pronounced. Body small and ill-developed, and much emaciated; some œdema of the extremities. On cutting through the sterno-costal cartilages, a considerable quantity of clear, yellow, somewhat ropy serum escaped. The two layers of pericardium were almost universally adherent, the exception being over a portion of the right ventricle and auricle, and over the commencement of the pulmonary artery; here a good deal of clear, yellow, jelly-like lymph had been thrown out, evidently very recently, so as at once to make and to occupy an interspace; I presume the yellow liquid, before

Digitized by Google

alluded to, was the thinner portion of this lymph. The heart was about eight inches in length; its walls did not seem much thickened, except those of the right ventricle, which were so to a considerable degree. All four of the chambers were of increased capacity, especially the left auricle, which would have contained about six fluidounces; just above its auricular appendage was a secondary pouch formed in the anterior wall of the sinus venosus, like a sacculated aneurismal dilatation; it was about one inch in length, formed mainly of endocardium, and would readily admit the point of the fore-finger. On the right side, the auriculo-ventricular valve had but two flaps, one of which was so closely adherent to the septum ventriculorum as scarcely to admit of the insertion of the finger or knife-handle beneath it; the closure of the orifice was decidedly insufficient. The corresponding valve on the left side was somewhat thickened and insufficient; its chordæ tendineæ and columnæ carneæ were of more than normal volume. Both sets of semilunar valves were healthy, as were also the great vessels, as far as traced. No signs of endocarditis presented themselves. The lungs were healthy; but there were calcareous deposits in some of the bronchial glands. Liver, kidneys, supra-renal capsules, and spleen normal.

The pericarditis was here evidently the latest lesion; but I am completely at fault to explain the rationale or the order of sequence of the other abnormal conditions. On the left side, where the insufficiency of the auriculo-ventricular valve was less marked than on the right, and where consequently there must have been less regurgitation, the auricle was hypertrophied to a far greater degree. The adherent flap of the right auriculo-ventricular valve I presume to have been rendered so by some former attack of endocarditis; but such adhesions, I believe, are very rare; nor are cases of non-rheumatic peri or endocarditis frequently met with.

WEDNESDAY EVENING, March 10th, 1858.

The President, DR. GROSS, in the chair.

Malformation of the Heart, Communication between the two Ventricles, and between the Auricles; Cyanosis.—DR. DARRACH exhibited a malformed heart, taken from an infant, aged eight weeks, of German parents: child was blue from birth; cried with much strength; tongue blue.

Sectio cadaveris twenty hours after death.—Head not examined. Thorax —lungs somewhat collapsed, no adhesions, of a florid hue, easily inflated with air from a pipe introduced into the trachea. Heart—small amount of fluid in pericardial sac, pericardium healthy; heart of a modena hue, coronary arteries empty, veins full; organ of a roundish form, looking, as was remarked, like a fish's heart. The aorta was situated to the right side, and much larger than normal. The pulmonary artery, instead of

Digitized by Google

occupying its usual position in front of the aorta, was situated at the left side of it, and about one-fifth or less of its usual size. On opening the heart, the aorta was found to arise from the right ventricle, and an opening, *about large enough to admit a large quill*, semilunar in form, existed at the upper portion of the septum ventriculorum. There was an entire obliteration of the pulmonary artery at its junction with the heart; but from this point upward it was pervious to the lungs, communicating with the aorta through the open ductus arteriosus. The walls of the two ventricles were nearly of the same thickness, the left a little thicker than the right; the auricular ventricular valves were healthy; the semilunar valves were also normal. There was an entire want of the septum auriculorum. Abdomen—the viscera were all healthy. There was an anomaly in the vena cava, which should be noticed It divided soon after leaving its fissure in the liver, into the two iliacs; the renal veins thus being given off by the iliacs.

At first glance there appeared in this case nothing but disorder, or an entire pathological condition; but, on more careful and thoughtful examination, we can perceive, as in all disease, the workings of a "protective" as well as a "destructive principle." The grand fault of nature in this case was no doubt the closure of the pulmonary artery, thus preventing the exit of the blood from the right ventricle; and unless some substitute for the pulmonary artery could be made, all circulation must have ceased. This was accomplished by shifting the aorta to the right side; and that the left ventricle might not be neglected, an opening was made, acting as a communication between the two ventricles; and so that the blood could reach the lungs, the ductus arteriosus was left open. We had, then, functionally, but one ventricle, and on this we are able to explain the want of septum of the auricle; for, having but one ventricle, we needed but one auricle, making thus a batrachian heart.

Ovarian Cyst in an Infant eight weeks old.—On removing the uterus of the above infant, a cyst was found, developed from the left ovary, about the size of a small marble.

DR. KEATING inquired whether there had been atelectasis at birth.

DR. DARRACH.—None; the child screamed lustily as soon as extruded.

DR. DARRACH exhibited another specimen of open foramen ovale. The heart was obtained from an adult man.

DR. KEATING spoke of several cases of open foramen ovale which had come under his notice, in which the persons had not suffered any inconvenience. In one case the sixtieth year was attained without there being any cardiac, pulmonic, or other disturbance. Dr. Keating, in reviewing the opinion held with regard to the open foramen ovale being the essential

Digitized by Google

cause of cyanosis, expressed his dissent from this view. Obstruction of the pulmonary artery he believed to be a more active cause. But he had seen want of expansion of the lung at birth, unconnected with either of the above-mentioned states, give rise to the blue appearance, which had disappeared under appropriate treatment.

DR. DARRACH inclined to the belief that obstruction of the pulmonary artery was mainly concerned in the production of cyanosis. He alluded to the statement of some authors, that the foramen ovale was kept open by nature, on account of the obliterated pulmonary artery, so as to act as a safety-valve.

DR. MITCHELL suggested as the reason why an open foramen ovale might exist during life without occasioning any disturbance, that in reality no venous blood would mix or circulate with the arterial, owing to the left auricle being stronger than the right. Its more powerful muscular fibres would send arterial blood to the right side of the heart, which, of course, going to the lung, would come back to the left auricle; but no venous blood, owing to the feebler contraction of the right auricle, could get into the left side of the heart, and from there into the general circulation.

DR. DARRACH thought Dr. Mitchell's theory to explain the absence of cyanosis, where an open foramen ovale existed, was open to objections, and mainly on account of its anatomy. It had appeared to him in dissection of the heart, that no difference between the auricles occurred. If any, the right was the most powerful.

Encephaloid of the Kidney.—DR. DARRACH next exhibited a specimen of fungoid cancer of the kidney, with accompanying microscopic drawings. The history was given as follows:—Mr. B., aged fifty-three, German, married; large; generally enjoyed good health; steady drinker of brandy. The attending physician stated that four years ago he fell heavily upon his back, and from that time had felt almost constant pain in the right lumbar region. About a year before his death he passed a large amount of blood by the penis, and had had several hemorrhages since, up to his death. I examined his urine several times, a short time before death, but found nothing abnormal, with the exception of blood, and bile coloring matter. The urea was in normal quantity. The patient suffered very much from the pain in the lumbar region, during the latter part of his sickness. A marked amount of effusion accumulated in the abdomen at one time, which accumulation, together with a yellow hue of skin, and bilious urine, led to the diagnosis of cirrhosis of the liver. A few days before death, our attention was attracted to the right lumbar region, from his complaining of pains, when a nodular lump was felt, and on percussion marked flatness was perceived. At first, the liver was thought

Digitized by Google

to be enlarged, and extending into the lumbar region; but as the fingers could be passed between the lower edge of the liver, and this nodular mass, by a process of exclusion, and taking into consideration the history of the case, and the bloody urine, we came to the conclusion that he had a cancerous kidney as well as cirrhosis of the liver.

Sectio cadaveris.—The head and chest were not examined.

Abdomen—there was considerable effusion in the peritoneal sac. The organs all appeared healthy, with the exception of the liver and the kidneys. The liver was enlarged and granulated, especially on the under surface, and of a brownish-yellow hue. The right kidney was about three times as large as normal, very much misshapen and nodulated, the size of the nodules varying from that of a small to a large walnut, some of them of a dark-black color, the rest of them, with the other portions of the organ, being of a light-yellow and red hue; the surface was much marked by brightly injected vessels, many of them having a stellate arrangement. On opening the kidney the nodules were found to be cysts; the dark-black ones filled with coagulated blood, while the others contained matter having a mottled-white, yellow, and red appearance, not unlike a well-marked nutmeg liver; this, on examination with the microscope, was shown to consist of oil globules in abundance, granular matter, and cells, which had the appearance of ordinary kidney-cells, many of them entirely filled with oil globules, others partially so, and exhibiting their nuclei. The left kidney was much hypertrophied, but to the eye, and under microscopical examination, there appeared nothing abnormal.

DR. WOODWARD showed a heart-clot, taken from the right side of the heart. It had probably formed before death, and consisted of white masses of unorganized fibrillated fibrine. The man—a sufferer from valvular disease of the heart—died suddenly. The aortic valves were much diseased. Dr. Woodward brought forward this specimen to disprove the opinion that heart-clots can only be formed during a protracted agony. This had formed in a case in which death was not protracted.

DR. FORBES, who had examined the heart from which this clot was taken, when recent, stated that in addition to the extreme ossification of the aortic valves, the valves on the right side of the heart had been diseased. Those of the tricuspid were thickened, those of the pulmonary artery rigid from a deposit. The left auricle was extremely thin and dilated.

Hepatic Abscess discharging through the Lung.—DR. MOREHOUSE called the attention of the Society to a large hepatic abscess. The patient from whom the specimen was taken suffered with repeated attacks of dysentery from early in September last until late in December, the date when disease of the liver became manifest. The attacks were frequent, al-

Digitized by Google

most running one into another, but so mild as scarcely at any time to confine him to the house. On the 25th of December he felt chilliness, loss of appetite, with slight fever at night, but attributed them to a cold, and was content to take such measures for their relief as his own judgment dictated. He continued to go out, in spite of his increased sickness, until the 1st of January, when he was suddenly bent double with pain in the right side, and in that condition brought home cold and prostrate from the intensity of his suffering. This pain continued, with slight remissions, until he died, on the 27th of February. During the progress of the abscess there was occasional nausea, and in the latter weeks, pain in the right shoulder. The dysentery disappeared entirely, as also the tenderness of the abdomen, except over the liver. The right side enlarged, with dulness on percussion over the epigastric and right iliac regions. The sixth and seventh ribs were widely separated, and in the intercostal space obscure fluctuation could be detected. Such was the condition until a few days before his death, when he was seized with a suffocative paroxysm, followed by the expectoration of a pint or more of "dirty red, puriform matter," considered by some as pathognomonic of abscess perforating the lung. At the end of two days the purulent expectoration had nearly ceased, although a constant hacking cough, with oppressed breathing, still remained. The enlargement of the side was not apparently reduced by the discharge, but the pain was very decidedly relieved. Five days after the opening of the abscess he died.

Post-mortem examination.—The body was emaciated, but not in the least discolored; the right side was very prominent, and fluctuation was evident between the sixth and seventh ribs and along their lower border as far forward as the epigastrium. On opening the abdomen, the liver was found attached firmly to its walls, from the ensiform cartilage to the lower border of the iliac region. The right lobe, in which alone disease existed, was converted into an immense cyst, from which was taken six pints of pus, similar in color and consistence to that expectorated a few days previous. There were, however, shreds of tissue, and a layer of white pus adhering to the disintegrating surface of the liver, which contrasted strongly with the prevailing color of the mass. The diaphragm formed the upper wall of the abscess, and at one point presented the appearance of having been perforated, but was now entirely closed. The left lobe was natural in size and structure. The gall-bladder contained about half a gill of thick bile, which was so inspissated and hardened at the neck as to be readily discerned from the outside. In the large intestine were three cicatrices of ulcers, two in the cæcum and one in the descending colon, probably the most recent. The lower lobe of the right lung was infiltrated with colored pus, and adherent by its base to the diaphragm to an extent not exceeding two inches

Digitized by Google

in diameter. In the apex of each lung were tubercles, some of them undergoing calcareous transformation. Throughout this case there was not the slightest jaundice, nor could bile be detected in the urine by its color, or by the reaction of sulphuric acid. This is most remarkable, considering the extensive disorganization of the liver, and the consequent suppression of two-thirds, at least, of its secreting power. It cannot be supposed that the remaining left lobe, which was not enlarged in mass, and did not indicate under the microscope an increased number of secreting cells, could assume the functions of the entire organ. Moreover, this conclusion is disproved by the occurrence of jaundice in cases of obstruction of the right hepatic duct, when the same amount of secretive tissue, as in this specimen, remains unimpeded in function. The evidence of this case, therefore, would seem to conflict with the theory that bile exists as such in the blood, and that deficiency of its elimination is the proximate cause of jaundice. Most of the cases of hepatic abscess of the right lobe that have been recorded, corroborate this view. Out of those given by Annesley, in his work entitled *Researches on the Diseases of India, and of Warm Climates*, among which are several where the function of the liver was more completely destroyed than in the case above cited, there is not one mentioned where jaundice occurs as a symptom. Andral, in his *Medical Clinic*, records one case with jaundice, but then the abscess was on the lower surface of the right lobe, and very liable to compress the hepatic ducts, which converge toward that part of the liver.

DR. GROSS did not feel quite satisfied that the matter expectorated came from the hepatic abscess. No seat of perforation was visible, and the abundant secretion might have come from the inflamed bronchial tubes and parenchymatous structure of lung.

DR. MITCHELL suggested that inflammation might have so closed up the opening into the lung as to prevent this from being discovered.

Fibrous Tumor of the Uterus removed during Labor.—DR. KEATING exhibited a specimen of fibrous tumor of the uterus, and accompanied it by these remarks:—

I was called to attend Mrs. W., of Vine Street, in her fourth confinement, at 3 A.M. on Monday the 14th of February.

Mrs. W. enjoyed excellent health during the whole period of gestation; but her enormous size had caused her to believe that she was pregnant with twins. About eighteen months previous I had delivered Mrs. W. of a still-born female child, presenting in the second position of the breech. The child seemed to have died some hours before the access of labor; and as the delivery was rapid, and in every respect natural, I was at a loss to account for its death, all attempts at resuscitation proving useless.

Digitized by Google

Upon entering the room on the morning of the day mentioned, I was informed by the nurse that the membranes had ruptured, and that a large amount of liquor amnii had been discharged. Upon making a vaginal examination, my finger came in contact with a large fleshy mass, which at first I considered a placenta prævia; but as the hemorrhage was inconsiderable, and a second examination did not confirm my suspicions, and especially as the os uteri was not dilated beyond the circumference of a half dollar, I concluded to await further dilatations of the os uteri previous to deciding as to the presentation. The labor-pains were slight and irregular, producing but little effect; the os remained firm and undilatable, but a portion of it seemed to be included within the presenting body, so that I could not with certainty define the posterior lip of the os uteri.

At 6 A.M., finding that the labor seemed obstructed, and that the contractions of the fundus uteri had but little effect upon the os, and not being able as yet to ascertain the presentation, I resolved on dilating with my finger the anterior lip of the os uteri. I succeeded partially, but met with great difficulty, from the size and resistance of the presenting body, which seemed completely to fill up the opening of the uterus. My examination, however, was sufficient to convince me that I had not to deal with a case of placenta prævia. From this I surmised that the body in question might be one of those cystic tumors of the nates, two cases of which have been presented to the Society by my friend Dr. Keller.

Finding at 6½ A.M. that the labor made no progress, and being still uncertain as to the nature of the case, I requested a consultation with Dr. Keller. In his first examination, he was also inclined to adopt the idea of a placenta prævia, but repeated examinations, attended with some violent expulsive efforts on the part of the patient, causing a sudden and partial protrusion of the presenting body, convinced us that it was a large fibrous tumor. Subsequent labor-pains, and further dilatations of the os uteri, enabled us to detect the right shoulder of a fœtus resting upon the tumor, with the umbilical cord prolapsed and pulsating. Fully satisfied as to the nature of the case, and convinced that no delivery of the fœtus could take place without the previous removal of the tumor, we requested the assistance of Dr. Addinell Hewson, who, after careful examination, fully coinciding in our views, immediately proceeded to enucleate the tumor, preferring this method of removal to that of excision, as a matter of prudence in case of threatening hemorrhage. The pedicle of this tumor measured at least three inches in diameter, and consisted of a dense fibro-areolar membrane of the same character as that which invested the whole tumor. It was this dense and unyielding character which caused me at first to suspect that the presenting body was not placental. The enucleation was rapidly and successfully performed by Dr. Hewson, and was

Digitized by Google

attended with little pain and slight hemorrhage. The tumor, upon extraction, weighed 2¾ pounds, and measured twenty inches in circumference. It was fibroid in its character, and was firmly attached to the posterior portion of the os and cervix uteri, entirely obliterating that lip of the os; its pedicle extended half an inch within the os internum, and after the removal of the tumor a sort of auricle was left, which might be considered as the undeveloped portion of the cervix uteri, the anterior portion having obeyed the usual law of pregnancy, and entirely disappeared.

From 8 to 10 A.M., the uterus remained in complete inertia, and the patient seemed exhausted. The anterior lip of the os had again contracted, and it was impossible to resort to version. A drachm of powdered ergot was administered in divided doses, and frictions applied externally over the abdomen. Subsequently we commenced dilating the os with our fingers, and succeeded in arousing some uterine contractions; version by the head was then accomplished, and the forceps applied to the head of the child as soon as it engaged in the pelvis, inasmuch as the patient was in a complete state of prostration, and made no expulsive efforts. Notwithstanding all our efforts for a rapid delivery, and our subsequent attempts by means of Marshall Hall's ready method of resuscitation, all proved useless; the child was dead. It weighed 9½ pounds.

An alarming flooding supervened after the birth of the child, which was checked by an artificial delivery of the placenta, the introduction of ice into the vagina, and by stimulating the uterus to contraction by the introduction of the hand. The patient remained in a favorable condition until the following Wednesday morning, when violent symptoms of puerperal fever set in, of a phlebitic character; in spite of all our exertions to save her, she died on the following Monday night. No post-mortem examination was allowed.

The peculiarity of this case consists in the existence and attachment of such a tumor to the os and cervix uteri without producing any morbid symptoms, and without provoking abortion in the early stages of pregnancy. Her menstrual periods had been regular as to time and as to quantity; she had never felt any inconvenience from the presence of this tumor, but I strongly suspect that its existence, though not as much developed, had caused the death of the fœtus in her previous confinement.

It is evident that such cases as these give the *coup de grâce* to the theory which makes the os and cervix uteri the guardian of pregnancy, and which claims an antagonism as existing between the fundus and cervix from the earliest months of pregnancy. Were such views correct, it is evident that the os and cervix, with such a tumor attached to their posterior parietes, would be in no condition to struggle against the supposed continued contractions of the fundus. Under such odds the early defeat of

Digitized by Google

the enfeebled cervix must have inevitably resulted. Some astonishment has been manifested in reference to conception taking place under such circumstances; but a moment's consideration would suggest the response that the anormally patulous condition of the os and cervix uteri would rather favor than oppose such a result.

Report of Committee appointed to examine the Kidney presented by Dr. Hall.—The microscope exhibited what were supposed to be epithelial cells, and a large number of corpuscles, which, from their size, shape, appearance and reaction with acetic acid, resembled tubercle. Some cells in regard to size and form might be considered as pus-cells; but the reaction of acetic acid did not develope any nuclei. No cells were found which in the slightest degree resembled cancer-cells. The Committee, from a careful examination of the specimen, are disposed to believe that it is tubercular.

Signed DRS. DARRACH, PACKARD, MORTON.

WEDNESDAY EVENING, March 24th, 1858.

The President, DR. GROSS, in the chair.

Deposit in Spleen, and Fatty Degeneration of Supra-renal Capsule.—DR. HEWSON exhibited a spleen filled with deposits, a supra-renal capsule in a state of degeneration, and a gall-stone, removed at the autopsy of R. S., aged seventy-seven years, a patient of Dr. ——. Mrs. S. had been under Dr. ——'s care about seven weeks previous to her death. When first called to her, Dr. —— found her suffering with great dyspnœa at night, and complaining of pain in the left hypochondriac region. She was much icterode, and her stomach was excessively irritable. There were no signs of cardiac disease, but in the right hypochondriac region he felt some nodular masses, and supposed them at this time to be cancerous masses in the liver; and in this opinion he was confirmed by Dr. ——, who saw her shortly after with the physician first called to the case. Tongue had been furred, dry, and cracked across; thirst was never great until a week before her death, when she showed great avidity for everything to drink. There was never any great heat of skin; pulse generally about 85. Her bowels were costive, defective in bile, and she always obtained considerable relief from their evacuation.

Autopsy fifty-six hours after death.—Body not much emaciated, legs œdematous. Abdomen—liver small; its envelope in places covered with fat; organ in a state of decided fatty degeneration; gall-bladder distended, with thin fluid bile, and contained a large gall-stone, (82 grs. weight,) beautifully bright and glistening, of an orange hue, and quite translucent. Stomach not at all distended, but presenting, at its pyloric orifice, well-marked signs of long-continued gastritis. Its mucous membrane was mot-

Digitized by Google

tled, with patches of deep dark-red, exceedingly soft and pulpy, and with spaces of beautiful arborescence. The mucous membrane of the duodenum was in the same state. There were no obstructions in the ductus choledochus or hepatic duct; pancreas was perfectly healthy. Spleen small, natural in appearance, but had on its surface two white patches of probably fibroid deposit, one the size of a pea, the other over half an inch, and extending fully that depth into the substance of the gland. Right kidney perfectly healthy; left kidney had a cyst on its surface, near the upper end of the gland; the supra-renal capsule was in a state of fatty degeneration. Bladder much distended, but healthy. Uterus small, and smooth on its external surface; was studded with melanotic deposit on its mucous surface, and there was some ulceration at the os tincæ. Thorax; heart—no great quantity of fluid in the pericardium; surface of heart covered, to some extent, with fat, organ of full size, and remarkably healthy in every respect, no paleness of structure or atheromatous deposit; aorta had a number of such deposits along its whole course. Lungs were of a dark-blue color, adherent in a number of places by old pleuretic adhesions; no signs of tubercle or congestion; both lungs were rather emphysematous throughout.

Atheroma of Aorta.—DR. HEWSON also exhibited a specimen of atheroma of the aorta, taken from a man, aged 44 years, a butcher, who died suddenly of an attack of gout affecting the heart. He had eaten a hearty supper of fish the evening before his death. The heart was much enlarged and gorged with blood, but contained no heart-clot; there was no pulmonary congestion.

Fibroid Degeneration of Liver and Kidney; Spiculated Exostosis on Tibia and Fibula.—DR. MORTON exhibited a specimen of spiculated exostosis on the tibia and fibula, from a patient whose leg was amputated on account of an indolent ulcer; also, the kidneys and liver from the same case, showing fibroid degeneration. The patient, Margaret Glenn, from whom the specimens were taken, was admitted into the Pennsylvania Hospital in January, 1858, on account of an indolent ulcer of the leg of thirty years' standing, which occupied nearly the entire circumference of the limb. She stated that at first it was small, but that repeated attacks of erysipelas left the ulcer larger and larger. Some of the veins of her leg were in a varicose condition; her health had been quite bad at times. She came into the Hospital for the purpose of having her limb amputated. She was about fifty-eight years of age, and in feeble health, with a good deal of gastric irritation, and irregularity of her bowels. Under tonics she improved much: her limb was removed by Dr. Peace. For some days after the operation her health and spirits seemed much better; but her appe-

Digitized by Google

tite soon failed her, her bowels became quite loose, and she gradually sank, and died eleven days after the operation.

The tibia and fibula showed well the effects of a chronic ulcer, in producing a spiculated exostosis.

Autopsy.—All the organs were healthy with the exception of the kidneys and liver. The kidneys—the fibrous tunic was firmly attached to the organ, and when peeled off, brought some of the tissue with it; the kidneys were much lobulated, but the lobules quite small; on cutting the organ through, it gave the impression that it was fatty, from its striking resemblance to that degeneration, and was so pronounced, but its texture was more firm than is seen in that condition of the kidney. A microscopic examination showed an extensive fibrous deposit without any fat. The liver was very considerably increased in size, and presented also the fibrous deposit.

The attention of the Society was called to the occurrence of the fibroid deposit in the kidneys and liver, in connection with indolent ulcers. Gay ("on Indolent Ulcers") remarks that, "when a constitutional ulcer becomes indolent, there is much reason to apprehend some very serious lesion of an important organ, most frequently of the kidneys or of the liver." In the above case such was the condition.

DR. DARRACH, who had also examined a portion of the kidney with the microscope, stated that although the kidney presented the external appearance of oily degeneration, yet only a few oil globules were observed, but many fusiform cells; it was not easy to obtain a uriniferous tubule. When seen, they were perfectly or partially denuded of epithelium; their membrana propria seemed thickened; the liver presented a large excess of fibrous tissue. The case was interesting, as occurring in a person not addicted to drinking.

DR. WOODWARD alluded to the fact that enlargement of the bone, under chronic ulcers, had been noticed, and especially by Paget. The spiculæ in this case might have arisen as part of the hypertrophy, or from periostitis.

Ossific Deposit projecting into Auricle.—DR. FORBES exhibited a diseased heart, without any history, as it was obtained from the dissecting table. Its walls were thin, and its cavities enlarged. At the seat of the foramina of Thebesius were extensive ossific deposits, which projected into the right auricle.

Aneurism of the Aorta bursting into a Bronchus.—DR. FORBES next directed the attention of the Society to an aneurism which had ruptured into a bronchus. The patient had been attended by Dr. Turnbull, who gave the following account of the case:—I was called to see Nicholas Harris on the evening of the 20th March, 1858. He is a cutter for a large tailoring

Digitized by Google

establishment in this city. He gave his age as thirty-two years; said he had been frequently sick, with pain and cough for more than a year; he had been a soldier during the Mexican war, when he contracted severe rheumatism, and had suffered since that time from intermittent fever. For the last six weeks he had been troubled with a severe influenza, and was much depressed on account of want of occupation; but a few days since he had been very much engaged cutting out clothing, causing him to stand and to stoop, and from the excessive fatigue he had fainted, and was brought home in a carriage. I found his skin warm and dry, his tongue coated and white, pulse feeble and rapid. He complained of pain in the upper part of the sternum, with a feeling of oppression.

Physical examination.—There was dulness on percussion over the whole of the left side of the chest, with bronchial respiration. On the right side percussion was morbidly clear, and auscultation discovered the inspiratory murmur quite feeble, with the expiratory murmur labored and wheezing. The action of the heart was rather loud. He complained of being feeble; could not sleep at night; would frequently get up on his hands and knees in bed to relieve his oppression. He had been taking a cough mixture made by his mother, which was exchanged for 10 grs. of Dover's powder, to be taken at bedtime.

On Saturday morning he felt better; had slept part of the night. Sunday morning, 9 o'clock, thirty-six hours after the first visit, he appeared languid; his skin was sallow; the pain in the front part of the chest had gone to the back. While half-reclining on a high settee, and resting on pillows, and speaking of his symptoms, he gave a deep moist cough, and raised his head to expectorate in a spittoon on the floor, and while in the act of turning, there came from his mouth and nose a series of gushes of blood, giving him no time to speak, or swallow, or breathe. He raised himself from the settee, and being unable to stand, the blood continuing to flow, he was placed on the floor on his side, when he gave a convulsive movement, and was found drowned in his own blood.

FIG. 5.

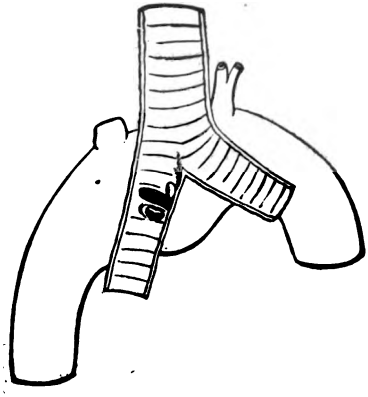

Post-mortem examination.—The body was natural, the heart normal; the aorta was much dilated at its arch, its coats thickened; an ulcer existed in them. The seat of perforation into the bronchial tube must have been small and then enlarged; the spot of perforation was eliptical, (see Fig. 5,) and partly closed by a new formation. The whole lung was filled with blood.

Digitized by Google

DR. LA ROCHE inquired into the state of the mucous membrane.

DR. FORBES stated that it was but little altered; a membrane seemed to stretch across the opening into the bronchial tube. With regard to the exact amount of dyspnœa latterly present, he did not know whether it had been a constant, or merely an occasionally violent symptom.

DR. STILLÉ remarked that the physical conditions were such, that, if any cause had disturbed the circulation in the part, difficulty of breathing by pressure on the membrane in the bronchial tube would have resulted.

Fatty Liver.—DR. HUMPHREYS exhibited a fatty liver, weighing nine and a half pounds, taken from a patient who died in the Pennsylvania Hospital, of effusion in the brain, consequent upon mania-a-potû. The kidneys were much enlarged.

Kidneys and Brain of a Diabetic Person.—DR. HUMPHREYS exhibited the kidneys and other organs of a case of diabetes. Pat. Dorken, aged forty-six, Irish, admitted into the Pennsylvania Hospital March 8th, with diabetes in an advanced stage. Had known of the existence of the disease for more than two years. He was much emaciated and exceedingly feeble, with great thirst, dry skin; passed daily from seven to ten pints of urine, of an average specific gravity of 1035. There were also well-marked symptoms of phthisis. About the 25th March a slight erysipelatous blush appeared upon the face and neck, accompanied with great prostration. The patient gradually sank, and expired March 28th.

Autopsy.—Right lung almost solidified, with small tortuous cavities at its top. Left lung healthy. Liver in a state of cirrhosis. Kidneys somewhat engorged, but otherwise healthy. Brain—membranes somewhat injected; dura mater somewhat adherent at the top.

Colloid Cancer of the Omentum.—DR. GROSS exhibited a specimen of colloid tumor, for which he expressed his obligations to Dr. Van Wyck, of this city, who had removed it a short time previously from a man, aged fifty-four years, a tailor by occupation, of spare make, and temperate habits. The morbid growth had been first observed about two years before death, having commenced in the left iliac region, from which it gradually extended in different directions until it filled the whole abdomen. Dr. Van Wyck had attended the man for about twelve months, when the tumor was nearly as large as at the post-mortem examination. The principal symptom was an extreme sense of weight and oppression in the abdomen, attended with considerable dyspnœa, especially when he suffered from constipation, to which he was very subject. He was but little emaciated, and there was hardly any œdema of the extremities. On dissection, it was found that the whole peritoneal cavity was occupied by an enormous colloid mass, reaching from the pelvis up to the diaphragm, which it had

Digitized by Google

pushed high up into the chest, covering completely the abdominal viscera, and effacing all trace of the serous cavity. It weighed upward of twenty pounds, and was fully two inches and a half in thickness, whitish in its appearance, and composed of numerous characteristic cysts, from the volume of a mustard-seed to that of a small hickory-nut. All the abdominal, pelvic, and thoracic viscera were sound. A microscopic examination by Dr. Da Costa, showed small cells, indistinctly nucleated, fibres, and an amorphous basement substance.

DR. GROSS stated that he himself had seen two similar examples, which are briefly described in the new edition of his *Pathological Anatomy*. The subject of the first case had been a man, forty-nine years old, who had an enormous colloid tumor, which extended from the liver to the pelvis, and involved the colon and greater part of the stomach, the abdominal viscera being greatly compressed and almost hidden behind the morbid mass. In weight it was found to be about twenty-five pounds, in thickness from two and a half to three inches, and measured in length nearly one foot, and in breadth over eight inches. In structure it was made up of innumerable masses, varying in size from a mustard-seed to a hickory-nut, and its appearances were denotive of its having been developed in the peritoneum or great omentum, the latter of which was effaced. The liver was diminished in volume, from the pressure of the tumor, but was otherwise healthy, and the thoracic and abdominal viscera were perfectly normal.

The second case occurred in a gentleman, forty-five years of age, who died in a state of complete exhaustion, after the disease had existed for about two years. The whole peritoneal cavity, with the exception of a small portion over the right lobe of the liver, was obliterated and occupied by an immense tumor, extending from the neck of the bladder to the diaphragm, which was pushed high up in the chest. All the pelvic and abdominal viscera were inclosed in the mass, but were free from colloid disease. The colloid structure was well marked, being composed of cells, the largest of which were about the size of a hazel-nut, and filled with a pale greenish jelly-like substance.

DR. HEWSON inquired if dropsy had been present.

DR. GROSS. None.

DR. HEWSON had had three cases of colloid of the peritoneum come under his notice. Two occurred in one family. Both had marked dropsy, and died within one year of each other. In both cases the surface of the peritoneum was studded with colloid. In a third case, the colloid deposit was most marked on the under surface of the liver, and on the surface of the uterus and ovaries. A large cyst in the ovary was filled with colloid. This case was tapped during life, and a serous fluid evacuated, which gelatinized on standing.

Digitized by Google

WEDNESDAY EVENING, April 14th, 1858.

The President, DR. GROSS, in the chair.

Abscess of the Ovary Communicating with the Sigmoid Flexure of the Colon.—DR. STILLÉ exhibited a specimen of ovarian abscess, for which he was indebted to Dr. Bell. The abscess had evidently discharged into the colon; an opening was found on the side of the ovary, and a corresponding opening in the sigmoid flexure. The communication was fistulous, and appeared to be of long standing. The peritoneum showed signs of inflammation; the liver was rather larger than normal, and fatty; there was no tubercular disease of the mesenteric glands; the bronchial glands were enlarged, and apparently filled with a deposit. No history of the case could be procured.

DR. GROSS spoke of the comparative rarity of ovarian abscesses. He also mentioned that a physician of this city had reported a case of an abscess of the ovary containing a gallon of pus.

DR. HARRIS had seen a case of supposed ovarian dropsy tapped, in which, doubtlessly, an abscess of the ovary had existed. About two gallons of an extremely offensive pus were drawn off.

DR. DARRACH believed that ovarian cysts might contain an extremely offensive fluid resembling pus, yet it would be hardly right to call such formations abscesses. He cited two cases to prove his assertion. In one, the ovarian cyst filled the whole abdomen, and was mistaken for ascites, on account of the existence of a tympanitic sound above the line of effusion, resulting from the elimination of gases within the cyst; the fluid evacuated was extremely offensive. In the second case, the cyst also contained a purulent fluid. In both, the walls were lined by a dense, flaky layer of lymph.

DR. AGNEW accounted for the fact that the abscess communicated with the intestine at the sigmoid flexure, by supposing that the latter must have been displaced by fæces, which it often is in women. He had frequently, in the dissecting room, met with ovarian cysts, but never with abscesses.

DR. STILLÉ would not positively affirm that the specimen before the Society was an abscess. The walls were rough, and the appearances were those of an abscess; yet it might have been a cyst.

Digitized by Google

Isolated Fibrous Tumor from the Mammary Gland.—DR. PACKARD, in presenting this specimen, made the following remarks:—This tumor was given to me by my friend Dr. Turnbull, who removed it about two weeks ago from the breast of an unmarried lady, aged twenty-one. It had been growing a little over three years, was freely movable, and projected somewhat above the level of the skin at the upper part of the gland. The patient thought she could trace it to an injury. Her menstrual functions were very slightly, if at all deranged. When the mass was removed, a small pedicle was observed connecting it with the adjoining gland-tissue.

Under the microscope there were seen a vast number of free nuclei, some oval, and others very much elongated and even curved. Many well-characterized fibro-plastic cells were also present, and very delicate fibrous tissue in large quantity. Acetic acid had little or no effect on these structures.

The diagnosis, before the removal of this tumor, was, that it belonged to the class described by Velpeau as *adenoid.* Sir Astley Cooper's *chronic mammary* tumors, and Cruveilhier's *fibrous*, are identical with these; Nélaton follows Lebert, whom he quotes freely, in calling them *partial hypertrophies* of the gland. Lebert's account of their structure is very full: he says they present no other elements than those of the gland, and they may affect either the fibrous tissue or the proper gland-structure. In the former case, he states, they have a fibro-gelatinous appearance, and are the only kind of fibrous tumor to which the breast is liable. He also mentions that they have a cellular envelope, and are easily enucleated, but that their independence of the surrounding tissues is only apparent; a pedicle being generally traceable. The existence of this pedicle is denied by Velpeau.

The cells of the present growth had, to my eye, very much the appearance of ordinary fibro-plastic cells, while the conversion of nuclei into fibres was traceable with admirable distinctness.

Meningitis of the Convex Surface of the Brain; Tubercular Deposit in the Lungs.—DR. MORTON exhibited a brain removed from T. D——, aged thirty, who was admitted into the Pennsylvania Hospital on the 3d of April, 1858. He was dull and stupid when he came into the hospital, but stated that he had been sick for two weeks with constant headache, and had bled much from the nose. He presented no marked symptoms, except dullness of mind, trifling cough, and a slight amount of paralysis of the lower limbs. He was, however, very weak. His condition remained the same, with the exception of his mind becoming duller, until the 9th, when he had a violent chill, followed by a convulsion which lasted

Digitized by Google

about an hour, and left him perfectly comatose. His pulse now rose; his urine passed involuntarily from him; difficulty in swallowing became a marked symptom, and he continued to sink until the 11th, when he died. The treatment consisted in cold water to the head, blisters and dry cups to the neck, purging, small doses of mercury, varied with stimulants and supporting remedies.

Post-mortem examination.—The lungs were somewhat congested, and contained patches of infiltrated tubercle. In the heart were large fibrinous clots, the largest occupied the left auricle and ventricle. The stomach and intestines were congested; the cœcum was especially so; the liver, kidneys, and spleen were healthy; the brain showed evidences of recent inflammation; large patches of lymph were deposited on its superior and its anterior surfaces. The same patches were found in the fissure of Sylvius. Under the dura mater, in the course of the longitudinal sinus, at the upper and posterior portion of the brain, some degenerate lymph and pus were met with. The dura mater itself was, here and there, along the course of the longitudinal sinus, firmly attached by the recent inflammation; bands could be distinctly seen when the membrane was lifted up. Some slight softening existed here, but none at other portions of the brain.

DR. STILLÉ commented on the interest of the case, which arose mainly from its being one of simple, non-tubercular meningitis, associated with tubercle of the lung. This is certainly rare, although by no means unprecedented. In what way the tubercular diathesis predisposes to meningitis it is difficult to say; yet that it does so appeared to him unquestionable. But in these cases we find, for the most part, small, granular, tubercular deposits along the base of the brain. No deposits of this nature, we are positively assured, could be found here by the most careful examination. We are, therefore, obliged to assume it to have been simple meningitis. Even some of the symptoms, such as the depression resembling that of typhoid fever, would seem to point to tubercular meningitis, yet the anatomical characters were not those of this affection.

DR. DA COSTA inquired if any effusion in the ventricles had been observed?

DR. MORTON. None.

DR. DA COSTA believed that this would tend to confirm the fact of its not being a case of tubercular meningitis. In this affection post-mortem examination almost invariably shows the presence of fluid in the ventricles, and, for the most part, in large quantities. The fluid is usually transparent and thin, but sometimes thick and creamy. It distends the

Digitized by Google

ventricles and leads to softening of the surrounding tissue. Hence the softening in such cases is merely that from imbibition. The microscope bears this out; it reveals no evidences of inflammatory action.

Case of Syphilitic Retinitis.—DR. ADDINELL HEWSON read the history of a case of retinitis which he had considered syphilitic in its character, from its history and from the resemblance of the exudation on the retina to the condylomata of syphilitic iritis. He thought the case of some interest at the time he first saw it, and was not then aware of the fact of any similar ones having been observed. Recently, however, some cases of this very disease have been quoted in the various journals, as observed by Mr. Critchett, at the Royal Ophthalmic Hospital, Moorfield, London. As these have attracted a good deal of interest by showing the important *rôle* the ophthalmoscope is likely to assume in diagnosis, Dr. Hewson thought some details of the case which had come under his notice might be acceptable to the Society, and therefore read the following memoranda taken at the time, November 20th, 1858:—

Wm. M. Smith, aged thirty-one years, born in this country, a stout, hearty-looking man, with light hair and beard, and blue eyes, now weighs 190 lbs., but between two and three years ago his weight was as much as 234 lbs. At that time he contracted *primary syphilis*, for which he took some internal remedies, but does not know of what nature. Since then he has lost flesh, and his appetite has failed him. At one time his hair fell out in great quantities, and recently (within the last six months) he has had some sores on his skin, and has once in a while suffered with pains in his back and loins. He now complains of marked dimness of vision in the left eye, and says the right eye has also begun to fail him. He does not think there is any difference in his sight at any particular time of the day. He first discovered the defect in the vision of his left eye eighteen months ago. This discovery was made accidentally by his getting some dust in the right eye. He remembers, however, having had violent pain in his left temple some time previous to this accident. After this casualty he sought advice for his left eye, and was treated with blue mass, but this was not continued sufficiently long to affect his gums. The sight did not improve under this treatment. It now seems worse at times, and is perceptibly influenced by the condition of his digestive organs.

He first noticed his right eye being affected two weeks ago; since then he has had constant pain in the right temple. His appetite is now good, and he has recovered from his baldness. There is no apparent disease in either eye—no signs of his ever having had iritis, or any form of ophthalmia. With the ophthalmoscope, the lens and vitreous humor of the left

Digitized by Google

eye are seen to be perfectly clear; the retina, however, appears to have a dirty tint, and to be defective in translucency; its surface is sprinkled all over with little points of a white, or a yellowish-white substance, and this effused substance in many places has quite a globular form, and resembles, in a very marked degree, the condylomata of syphilitic iritis; some of these masses have a reddish tint. The optic nerve in this eye has a dirty-red hue; the vessels of the retina are somewhat varicose. In the right eye the retina is seen to be more acutely inflamed; the optic nerve redder than natural, and the vessels of the retina, as they emerge from the nerve, abnormally large and tortuous; the tint of the retina is more dusky than is usually seen in acute retinitis.

I pronounced this case one of syphilitic retinitis, which had become chronic in the left eye; ordered Hyd. protiod, gr. ¼ t.d.; milk diet; rest; local depletion and counter-irritation. He improved for a time under this treatment, and was placed on the iodide of potassium. He was considerably benefited by this drug, which he took alternately with the protiodide of mercury. Whenever the gums and breath became affected by the mercury it was discontinued, and the potash taken in its stead.

Early in March his right eye appeared perfectly well, but no improvement was manifest in the left. About this time he exposed himself, when in the interior of the State, attending to some business, and became rapidly worse—almost blind in the better eye. The mercury was resumed, and, as soon as the acute symptoms had subsided, he again visited the city and consulted me. This was on the 19th of March, and I made the following note of this case at that time:—

March 19.—Wm. Smith visited me to-day; has improved much in health and appearance; says he weighed, two weeks ago, 200 lbs., but has lost since then; weighs now 195; has been suffering for two weeks with pain in both temples; sight is the same as when here on New Year's, but has been seeing, during the last two weeks, white stars,—these only occasionally; no external appearance of disease in the eyes; pupils natural; iris of right eye perhaps lighter in color; has been taking medicine up to the last two weeks; has had no flashes of light as he experienced after he was first attacked.

Dr. H. then ordered him the Zittmann's decoction; dysentery, however, supervened on the use of this, and his physician in the country was obliged to go back to the first plan of treatment. When Dr. H. last heard of this patient he was better, but not well.

Report of Committee.—The Committee appointed to examine the brain removed from a diabetic patient would respectfully report, that they care-

Digitized by Google

fully examined the organ, but found no portion which might fairly be considered as diseased. There appeared to be some softening in the immediate neighborhood of the fornix, yet this was a mere appearance, not borne out by a microscopical examination. The brain was very much engorged, and its tunics injected.

Signed DRS. PACKARD, HUMPHREYS, DA COSTA.

WEDNESDAY EVENING, April 28th, 1858.

The President, DR. GROSS, in the Chair.

Cirrhosis of the Liver; Diabetes.—DR. MORTON exhibited a specimen of cirrhosis of the liver, which was taken from a man aged thirty-eight, of short stature, thin, and dark-haired, who was admitted into the Pennsylvania Hospital on March 22d, 1858, for diabetes.

The account he gave of himself was, that with the exception of six or eight attacks of erysipelas of the right leg, he had been perfectly well until eight weeks before he entered the Hospital. At that time he was seized with another attack of erysipelas, and a severe cold followed; since which he had been confined to his bed. He stated that for a long time he had frequent calls to pass his water, and that he was obliged to rise five or six times during the night; his bowels were generally constipated; his tongue and skin, he had noticed, were always quite dry. For a long period he had been in the habit of carrying sugar in his pockets, and eating it while at work, so great was his desire for it; this habit had increased upon him of late. At the time of his admission he passed from seven to eight pints of urine daily, loaded with sugar, high-colored, and of a specific gravity averaging about 1038. His belly commenced to swell eight or ten days before he was admitted into the Hospital. The swelling had lately much increased, and he presented considerable œdema of the limbs and ascites, measuring thirty-eight inches around the belly. He became exceedingly debilitated and anæmic, and although he was placed upon a tonic plan of treatment, with rennet and nutritive diet, he improved but for a short period; he soon relapsed into his former weak condition, and his skin and tongue became again very dry. About the 12th of March he was seized with another attack of erysipelas in the leg, accompanied by diarrhœa; drowsiness supervened, followed by complete coma, and he died with symptoms of effusion in the brain, on April 16th, twenty-four days after admission, and eleven weeks after he first complained of being sick.

Post-mortem examination.—The lungs and heart were healthy; the liver cirrhosed, but of normal size; spleen, normal; kidneys, large, congested, and flabby; brain, pale; about two ounces of effusion were met with under the arachnoid. The abdominal cavity contained about 2½ gal-

Digitized by Google

lons of serum, which, when tested for sugar, gave evidence of the presence of a considerable quantity of this substance. The brain was examined for sugar, but not a trace of it could be detected. The blood from the ascending vena cava was also tested for sugar, but none was found.

DR. DA COSTA made some remarks with reference to the different organs which evince signs of disease in diabetes. The kidneys are sometims normal, but he had in several post-mortem examinations observed them to be larger than in health, and containing a much greater quantity of fat. The cells lining the tubules are filled with this substance, and the walls of the Malpighian corpuscles are full of oil-granules. Dr. Da Costa also directed attention to the circumstance that in most of the cases of diabetes presented to the Society, disease of the liver had existed.

DR. FORBES had met with disease of the liver in three post-mortem examinations made on diabetic patients. He also spoke of an interesting case of diabetes, which followed an injury. A patient, a negro, was brought into the Pennsylvania Hospital with a compound fracture of the leg. Diabetes made its appearance within a week, and he died of the disease in the thirteenth week after his admission.

Tubercle in the Lungs and in the Mesenteric Glands.—DR. MOREHOUSE exhibited two specimens of tubercle, one affecting lymphatic glands, the other the pulmonary tissue. In the first case disease had existed for more than three years. The glands of the neck had inflamed, softened, and opened, as is ordinarily seen in scrofula. This was followed by gradual emaciation, enlargement of the liver, and repeated discharges of blood from the bowels, which continued during the last ten months of the child's life. After death the mesenteric glands were found to be enlarged; so were the bronchial glands. The lungs were not the seat of deposit. The lower lobe of one of the lungs was in a state of inflammation. The heart was filled with firm heart clots, surrounded by a soft gelatinous mass soluble in water. The liver was greatly enlarged, and studding its surface were numerous subperitoneal deposits. Similar deposits were found on the spleen and pancreas, and on the inner surface of the abdominal walls. The microscopical appearances of the deposit in the different glands were those of yellow tubercle with a preponderance of granular matter.

In the second case the lungs were infiltrated with gray tubercle. A cavity had formed in one of them. The child, aged eleven months, died in convulsions. The ventricles were filled with fluid; their lining membrane was softened.

Dr. Morehouse believed that the first form, or yellow tubercle, affected more especially the lymphatic glands, and might be considered as a separate variety and as associated with the scrofulous diathesis.

Digitized by Google

DR. STILLÉ would not deny that tubercular matter was frequently deposited in lymphatic glands, but he did not think that this could be viewed as a separate form of tubercle. Nor could he regard it as identical with scrofula. For this disease, although chemically and in its minute structure not different from tubercle, was yet very dissimilar in its exact clinical and pathological bearings, and a distinction, therefore, between the two is being now more generally admitted.

Several other members maintained similar views and spoke against Dr. Morehouse's proposition.

Cyst over the Nasal Bones containing Gelatinous Matter.—DR. GROSS exhibited a cyst removed from Albert B. M., aged eighteen years, who presented himself at the Jefferson College Clinic, on account of a tumor which had existed for sixteen years over the nasal bones between the inner canthus of the left eye and the glabella. Upon removal, the tumor, which was about the size of a marble, was found to contain a small quantity of softened sebaceous matter, and about one drachm of a greasy, light, amber-colored fluid, resembling in every respect fine olive-oil. This, upon standing a few moments, became of the consistence of lard. The cyst was opaque and thickened, and granular on its inner surface. Microscopically, the fluid was found to consist of fat globules and numerous non-nucleated corpuscles, such as are seen in the gelatinous matter taken from the thyroid gland.

Astragalus discharged through an opening in the Foot.—DR. HUTCHINSON presented, through the Secretary, an astragalus removed from the left foot of Josiah Morgan, aged eleven years, of Butler, Luzerne County, in this State, by Dr. Peace, at the Pennsylvania Hospital, on the 17th of March.

The patient states that, about the middle of last August, he was thrown from a hay-mow by another boy, but not feeling much hurt he continued to use his foot for some days afterwards. During this time he caught his foot in a rut and twisted it slightly; he is unable to say positively to which accident he owes his present condition. A few days after the latter occurrence his foot became too painful to be used. There was no external wound at this period; an opening formed, however, a short time subsequently. Several small pieces of bone were discharged before his admission into the Pennsylvania Hospital, and the remainder, constituting the entire astragalus, was removed without difficulty.

When the case was first seen, a short time after admission, there existed in front of the external malleolus a large opening into which the little finger could readily be passed. This has now healed, leaving only a

Digitized by Google

small orifice, through which carious bone may be felt. Another and similar orifice existed lower down, over the os calcis.

The principal shortening took place in the length of the foot, it being now three-quarters of an inch shorter than the other; not more than one-quarter of an inch difference can be detected in the length of the legs.

The foot had a tendency to turn inward, which has been corrected by a pasteboard splint moulded to the part. The foot is very nearly at the proper angle with the leg, and some motion exists at the joint.

WEDNESDAY EVENING, May 12th, 1858.

The President, DR. GROSS, in the chair.

Cases of Chronic Rheumatic Arthritis.—DR. BRINTON exhibited two shoulder joints which had been removed from a subject in his dissecting room. These specimens presented appearances such as would lead to the belief that, during life, the individual had suffered from chronic rheumatic arthritis.

Examination of left shoulder.—The upper and outer portion of the capsular ligament had been entirely destroyed. The tendon of the biceps muscle had been absorbed; the tendons of the supra and infra-spinatus, and also that of the teres minor, had become separated from their attachments to the tuberosities of the humerus; and that of the last-named muscle was completely torn into shreds. The synovial membrane of the interior of the joint was thickened and presented a villous fimbriated appearance. In consequence of the destruction of that portion of the capsular ligament which arises from the upper part of the glenoid cavity of the scapula, a spontaneous luxation of the humerus directly upwards had occurred; the head of the bone resting against the under surface of the coraco-acromial arch. The articular cartilage of the humerus in some points appeared thin and soft; at others, and especially upon the outer and upper portion, eburnation had commenced, as also upon the under surface of the acromion process.

Right shoulder.—In this preparation, which had been cleaned, the same appearances of eburnation were presented, and destruction of the capsule and upward dislocation had also occurred. Dr. Brinton stated that some time since an opportunity had been afforded him of examining upon the living patient the interior of a shoulder-joint similarly affected. The patient, aged twenty-three, had suffered from repeated attacks of chronic rheumatism. Some months subsequent to his last attack a tumor developed itself slowly in the region of the supra-spinatus fossa of the left shoulder, producing pain, and interfering with the utility of the limb.

Under the impression that the tumor was of a fatty nature, an incision

Digitized by Google

was made over it; when about two ounces of dark, thick, oleaginous fluid escaped. The supra-spinatus muscle was found completely destroyed, having undergone fatty degeneration; its tendon was separated from its belly, and had formed attachments to the bone. The finger could be carried under the acromial arch into the cavity of the articulation, where the capsule appeared to be destroyed externally and superiorly, and the head of the humerus seemed rugged and uneven. The degenerated supra-spinatus muscle was scraped away with the handle of a knife, and the wound closed by sutures. Union by first intention ensued except at one point, where a synovial fistula existed for some weeks, but eventually healed up.

The patient recovered the use of his arm and was able to resume his work, but died of a cardiac affection some months afterwards. Dr. Brinton stated that he regarded this case also as a well-marked instance of the rheumatic arthritis so ably described by Mr. Smith and Dr. Adams, of Dublin.

Dr. Brinton also directed the attention of the Society to a specimen of remarkable *disease of the knee-joint.* The patient was a negro wood-sawyer of advanced age, but the exact history of the case could not be obtained. The joint exhibited presented the following appearances:— The crucial ligaments had been destroyed, as also the semilunar cartilages and coronary ligaments. The external condyle of the tibia had been absorbed and a new articulating surface formed at the expense of the side of the tibia and the head of the fibula; this latter was flattened out and incrusted with bony deposits. The adventitious cavity thus formed, as well as the condyle of the femur, had become completely eburnated, and presented surfaces of extreme polish and hardness. In the new condyloid cavity was found a large mass of bone attached by a ligamentous pedicle to the external ligaments. This mass was about an inch and a quarter in diameter, of rough and irregular shape, although at certain points polished by attrition. As long as this body rested beneath the external condyle of the femur, and between it and the bottom of the new articulating cavity, it was evident that the patient could walk with the leg nearly in its normal relative position to the thigh. When, however, the mass of bone slipped away from beneath the femur, as frequently had happened during life, a spontaneous dislocation of both bones of the leg occurred, the leg then forming with the thigh an angle of about 135°. Two or three free cartilages, or rather osseous masses, were found loose in the joint. The synovial membrane had been entirely destroyed. The external ligaments had lost their distinctive character; the whole articulation being surrounded by a species of dense capsular ligament. Fracture of the patella had also occurred; the upper fragment had been displaced

Digitized by Google

laterally, and the union was imperfect. As to the origin of this strange condition of the joint, Dr. Brinton could not speak with certainty; but he was inclined to look upon it as the result of chronic inflammation, perhaps following injury.

DR. HEWSON was able to add some facts concerning the history of this patient. The man had earned at times his living by cutting grass, and had been thus occasionally employed by Dr. Hewson's father. Dr. Hewson could state positively that he had suffered much from chronic articular rheumatism. He also remembers distinctly that fourteen or fifteen years ago he met with an accident to his leg, probably a fracture, after which his lameness was much increased, and that at times this man walked more erect than at others.

Constriction of the Mitral Valve; Single Kidney.—DR. MORTON exhibited a diseased heart and a fused kidney removed from a patient who was admitted into the Pennsylvania Hospital on May 3d, 1858, about 6½ P.M. The only account which could be gained of the case was that the man was found in an insensible condition in one of our small streets. On examining him, it was soon perceived that he was in a violent convulsion,—skin cold, eyes staring, great muscular rigidity, and the pulse scarcely perceptible. He was immediately placed in a hot bath, 110° F., and carbonate of ammonia and brandy were given to him and were readily swallowed. Thinking that possibly some poison had been taken, the stomach-pump was introduced and the viscus washed out; but there was no evidence of any foreign substance. He continued to sink, his pulse sometimes rising and then falling, until 1½ A.M., May 4th, when he died, exactly seven hours after admission.

Post-mortem examination twelve hours after death.

Lungs, healthy. Heart, valves healthy, with the exception of the mitral, which was much thickened, and so contracted that it would not admit the little finger; large fibrinous clots occupied all the cavities. Liver, large and fatty. Kidneys, presented the following anomaly: the two kidneys were merged into one, which was placed near the third lumbar vertebra, and so situated, in relation to the spine, that about four-fifths of the organ were on the left side, and the remaining portion on the right. That part of the kidney which lapped over the bodies of the vertebræ was much thinner than the main body. The organ has an irregular kidney shape; on the back surface of the gland the parenchyma is deficient in two places, one near the right, the other near its left extremity.

The cavity at the left, which is connected with the main body of the

Digitized by Google

kidney, measures about an inch and a quarter in length, and three-fourths of an inch in breadth; the right cavity is about three times the size of the left, and is of an irregular, quadrilateral shape, and much more superficial than the other. These two cavities contain the pelves of the kidney. The right portion of the kidney sends six calices to the pelves; the left pelvis is pyriform in shape; there is no communication between the two pelves. One artery supplied the organ, sending two branches to the left and one to the right side. The kidney measures six and three quarters of an inch in length, four and a quarter in breadth, two and three-quarters above the contracted portion. The left ureter is twelve and a half inches, and the right ten inches long. On leaving the kidney, they pass down on the right side of the spine, and enter the bladder at the usual places. The organ weighs nine and a half ounces; in consistence it is healthy.

The Brain weighed sixty-three ounces. It was quite soft, and easily broken down when pressed with the finger. In many places it presented the appearance of chronic congestion, particularly on the right side, and nearest the cerebellum. The membranes (arachnoid and pia mater) were much thickened, opaque, and filled with serum; about eight ounces of which escaped when the brain was removed.

In the falx cerebri, about a quarter of an inch from the lower boundary, and two inches from the anterior edge, was found an irregularly spiculated piece of bone, sharp and pointed; several other much smaller pieces were seen at some distance from it. The arteries of the brain contained large, firm, fibrinous clots, which could be drawn out continuously for some inches.

When the calvarium was removed, a depression in the brain was observed, and, upon searching for the cause, a bony outgrowth from the frontal bone was found, which projected inwards. It was situated above the right frontal sinus; other small bony projections were to be seen near it.

It is most probable that the brain suffered so much from the pressure of the tumor, that epilepsy was the result; the condition of the membranes would also favor this supposition.

DR. GROSS inquired into the state of the supra-renal capsules.

DR. MORTON.—One existed.

DR. LEVICK commented upon the mode in which death had occurred in this case, and remarked, in this connection, that the fibrinous clots extending from the heart into the smaller vessels of the brain, might have a direct bearing in explaining the symptoms preceding death.

DR. RICHARDSON alluded to the rarity of a single kidney.

DR. GROSS stated that he had a specimen of this kind in his collection.

Digitized by Google

DR. HARRIS presented the following remarks in relation to the specimen before the Society:—

The human kidney is subject to numerous variations in regard to its position, form, mobility, vascular connections, and the arrangement of its excretory ducts. In some instances one, and in others, both glands have been found wanting; but those in which the latter condition is said to have existed (except in the cases of newly-born infants) are not sufficiently well authenticated to be received as positive proofs. Two, and sometimes more, kidneys are occasionally united to form one; and numerous examples of this error of conformation may be found by referring to the medical periodicals and standard works which have been issued during the last two hundred years. In the journals of our own country, very few cases have been reported. "The American Journal," with its predecessors of the same series, running through a period of fifty-four years, does not report a single case; the same may also be said of "Bell's Medical Journal;" "The Boston Medical and Surgical Journal;" "Philadelphia Medical Examiner;" "New England Journal of Medicine and Surgery;" "North American Archives of Medical and Surgical Science;" "Virginia Medical and Surgical Journal;" "New York Journal of Medicine;" "Boston Medical Magazine;" and "The Transylvania Journal of Medicine and the Associate Sciences."

Before entering more particularly upon the subject of *fusion* of the kidneys, it may be well to examine into the nature of the other errors of conformation and position, above referred to.

1. *Position.*—This is quite variable, one or both glands being not unfrequently found higher or lower than the situations in which they are usually placed. Many cases are upon record, where one or both of the kidneys (though seldom the latter) have been found in the superior or inferior pelvis; and instances of the first variety have no doubt occasionally been the means of leading an examining physician to conclude that his patient had had but one kidney. In an example recorded by Rayer,* of which a plate may be found in the Atlas accompanying his work, the misplaced kidney was discovered low down in the pelvis, in front of the sacrum, and in a vertical position; it was smaller than the one normally situated, and received its arterial supply from a vessel which was given off by the aorta, between the origin of the primitive iliacs. As the other kidney was larger than natural, and the capsula renalis of the misplaced one in its usual situation, the latter might very readily have escaped the eye of a physician in making a post-mortem examination, if conducted, as we are frequently obliged to conduct them, in private practice. In most cases of

* Maladies des Reins, tome iii. page 784.

Digitized by Google

misplaced kidney, the supra-renal capsule of the same side occupies its accustomed seat, thus giving, by its independence of position, one proof of the absence of any material connection in the functions of these two bodies. Besides the forms of misplacement mentioned, cases have been met with where the two kidneys were discovered lying in front of the sacro-iliac symphysis, or placed close to each other, and in front of the vertebral column. The *floating kidney*, hereafter to be referred to, is another example of malposition.

2. *Size.*—This is subject to more variation than the position, though often influenced by the latter. Disease is one great cause of augmentation or diminution of the gland; but with it we have nothing to do at present, having only reference, in this connection, to variations in volume, which result from other causes. When one kidney is smaller than natural, the other is usually found correspondingly enlarged; and where there has been an early arrest in the development of one, the other is nearly or quite double the natural dimensions. The same may also be said of the effect of the absence of one kidney. Single kidneys seated in the lower pelvis are generally smaller than natural, and have a very short ureter.

3. *Form.*—Single kidneys vary but little in shape when in a healthy state, except when their growth has been affected by the peculiar position in which they have been placed. A few instances are upon record where a single kidney was found longer and much more curved than natural, constituting one of the varieties of *horse-shoe kidney*, though this title is generally applied to a peculiar variety of fusion. Kidneys developed in the pelvis are generally of a different form from those found in the lumbar region, being usually more cylindrical and narrow; though in this there is no uniformity, as the shape depends very much upon what part of the pelvis they occupy. We shall have more to say upon the varieties of form, when we come to consider more minutely the subject of fusion of the kidneys.

4. *Mobility.*—In their natural position the kidneys are very firmly fixed, but we sometimes meet with cases in which the arteries and veins connected with a single kidney, or with a fused one composed of two, are exceedingly long, and act, to a certain extent, as a means of suspension for the gland, allowing it to float, as it were, among the intestines, in the abdominal cavity. Such cases are sometimes mistaken for abdominal tumors, and are very difficult to recognize in the living subject. Though not properly a disease, this peculiar condition may give rise to much disturbance of the digestive organs. An example of this malformation may be found in the work of Rayer, before quoted; another in the "Boston Medical and Surgical Journal," vol. xxv. page 275; and four in the "London Lancet" for 1842–3, vol. ii. page 558. The last were observed

Digitized by Google

by M. Aberle, and reported by him; one of them is taken from the "Salzburg Gazette," of 1826, and the other three from "Schmidt's Jahrbuch," vol. xxxii. p. 312.

5. *Vascular connection.*—The kidneys, in their natural form and position, are generally each supplied with blood through one arterial trunk, and the circulation returns through one vein; but various departures from this rule are to be met with; sometimes there are several emulgent arteries to a single kidney, and when a fusion of two or more glands has taken place, it is common to find for each section a separate artery and vein. In misplaced kidneys the renal artery may come from some point considerably below the natural level of the kidneys. In floating kidneys, however, the veins and arteries are usually given off from the points whence they proceed, in cases where the glands are normally situated.

6. *Arrangement of the excretory ducts.*—Variations from the usual condition are not at all rare. A single kidney may have a double pelvis, or two pelves and two ureters, which last may either unite to form a common trunk, or continue separately to the bladder. Rayer gives a plate of one case where each kidney had two pelves and two ureters, and these conduits all entered the bladder distinct from each other. The ureters from two kidneys may unite to form one common canal. In fused kidneys there may be one, two, three, or four ureters, which may continue distinct from each other until they enter the bladder, or two or more may unite to form a common conduit. The ureter may not enter the bladder at all, but empty into the urethra; a case of this character, where the ureter was double, and entered the urethra just in front of the neck of the bladder, may be found recorded in the "Boston Medical Magazine," vol. iii. page 332. In fused kidneys the calyces are generally much longer than natural, and are exposed to view by simply removing the fat which covers the depression in which they and the pelvis are situated. We now come more particularly to the subject of union of the kidneys, and with it may properly be included that of redundancy of kidneys.

Though comparatively of rare occurrence, fusion of the kidneys has been met with sufficiently often, during the last two centuries, to have given, in the medical books and periodicals where they have been reported, a considerable number and variety of examples. The most common form of union is that known as the *horse-shoe kidney*, (this title, as I have before mentioned, is sometimes also given to a single kidney of an unusually curved form,) in which the two kidneys are united across the spine at one or other of their extremities, (in most of the instances I have found recorded it was the lower,) either by a direct union, or through the medium of a connecting band or *isthmus*. Another variety is that in which there are more than two kidneys united together in a somewhat crescentic

Digitized by Google

form, and showing, by constrictions at certain points, the number of glands composing the whole mass. Each section is supplied with its own vessels, and sends off a separate ureter. I will refer to a few of the cases which have been reported, as examples of these peculiar forms of fusion.

Rayer* reports, with an accompanying drawing, a case of horse-shoe kidney, with the concavity upwards, having a double pelvis and a single ureter. One instance of the more common horse-shoe kidney, with two ureters, such as they are usually found, is reported in the "Dublin Quarterly Journal of Medical Sciences," for 1846, vol. ii. page 239; another in the "Edinburgh Medical and Surgical Journal," for 1819, vol. xiii. page 90; and three cases in the "London Lancet." Similar cases have been met with by Panthot, Kaltschmidt, Bartholin, Wrisberg, Gebbard, Sandifort, and many other European writers. Rayer mentions having seen a crescentic kidney in which there were three distinct glands, united by their extremities. Botal, Gemma, Dalestang, and Monginot report cases of quadruple kidneys, each section of which possessed its distinct pelvis, ureter, and blood-vessels. In all these cases above referred to, the fused kidney was situated either transversely or obliquely across the spine.

From all the information that I have been able to collect from the monographs and journals consulted, I am led to the conclusion that the variety of double kidney exhibited by Dr. Morton is, with one exception, the most rare of all the examples of fusion of the two glands. The exception referred to, is that form of double kidney described by Sandifort,† where one gland was found in its natural position, and the other placed immediately in front of, and united with it; two pelves and two ureters proceeded from this welded gland.

I have been able to find but two cases recorded in all the volumes of journals, (amounting to several hundreds,) and in the books that I have examined, which very nearly resembled the specimen now before us. One is delineated in Rayer's plates, and the other is reported in the "North American Medical and Surgical Journal," of 1829, vol. vii. page 176; a reprint from a foreign periodical. Both these kidneys were seated transversely across the lumbar vertebræ, and had two pelves and two ureters, which, in each specimen, came from the anterior surface of the mass.

Three peculiarities distinguish the fused kidney upon the table from all those of which I have found full descriptions. 1st. Almost the entire mass was situated upon one side of the spinal column, a small, thin portion only, overlapping the vertebræ. 2d. The concave edge, instead of the convex, presented downward, and the pelves toward the psoas magnus

---

* Op. Cit.

† Obs. Anatom. Pathol., Lib. iii. Cap. vii. page 96.

Digitized by Google

muscle. In most instances the pelves are either upon the abdominal surface or the concave edge of the gland. 3d. Although the gland, from its size and the number of its ureters, is clearly a double one, in form, position, and vascular connection, it bears a close resemblance to a single hypertrophied kidney.

Cancer of the Lung and of the Mesenteric Glands.—DR. DARRACH presented a cancer of the lung, and remarked as follows:—

The subject of the above-mentioned disease was a married man, aged sixty-five years. He was of a spare figure, had a well-developed chest, and could count with ease 100 in a breath. At the time he was first examined (Jan. 6th, 1858,) no affection of the lung could be discovered, by a careful physical examination of the chest: the symptoms of which he complained were vomiting of food, acidity of the stomach, eructations, and, on pressing over the region of duodenum, a "deep soreness." His indisposition first appeared about two years ago, and had increased most rapidly within the last three months; but more especially for the last two or three weeks. Within the latter space of time he retained scarcely anything on his stomach. He had also become lately very irritable in temper, and indisposed to use either body or mind. Thinking that the patient might be suffering from a severe attack of mal-assimilation, commonly called oxaluria, a specimen of his urine was examined, but no oxalates were discovered. The quantity of urine passed in the twenty-four hours was about forty fluidounces, (sp. gr. 1020.) In less than forty-eight hours, in a cool room, the fluid still remaining slightly acid, there appeared a most abundant formation of vibriones, which constituted a dense cloud throughout the mass of urine. From this formation it was inferred that he was laboring under some very depressing influence, the nature of which was not as yet perceived. The patient had also been suffering for some weeks from hemorrhoids.

The treatment followed out at this time was as follows:—Nux vomica, gr. $\frac{1}{8}$ four times daily, with blue pill at night, and carefully regulated diet, &c. But the patient continued to grow worse and worse. Emaciation became extreme; the hemorrhoids, for some weeks before his death, bled at every discharge from the bowels, frequently as much as a pint. His mind became at times wandering, and he seemed to be succumbing, as his family physician remarked, to some serious blood-disease. A short time previous to his death, cancer was surmised, probably of the liver, yet the pulmonary symptoms remained extremely obscure. There was no hemorrhage, and but a trifling cough.

Death occurred on the 26th of March. An examination of the body was made on the afternoon of the 27th. The cranial cavity was not ex-

Digitized by Google

amined. The upper lobes of both lungs were solidified with what appeared to the naked eye to be undoubted tubercle, but which, on careful examination with the microscope, by Dr. Da Costa and myself, was satisfactorily proved to be cancer. The elements found consisted of cells with large nuclei, many of the cells being peculiarly transparent, and exactly resembling those described by Dr. John Hughes Bennett, in his work on "Cancerous and Cancroid Growths," page 45, as occurring in cancer of the lung. There were also cancer nuclei and granular matter.

The liver was dotted over its surface with very small, perfectly circular patches, of a white matter, dipping slightly into the liver substance, their centre having a depressed appearance, as is not unfrequent in cancer of that organ. I could not satisfy myself as to the cancerous nature of the elements composing them.

The stomach, bowels, kidneys, and spleen were normal; the lumbar glands were very much enlarged by a deposit, which gave to them the appearance of scirrhous cancer, yet on cutting into them, they were neither very hard nor resistant. The cut surface became convex, and was of a slightly yellowish hue; no creamy fluid exuded. Microscopically examined, these glands showed elongated, nucleated, fibroid cells, such as Paget has described as occurring in some structures affected with medullary cancer.

DR. STILLÉ inquired of Dr. Darrach whether diarrhœa had existed, and also what was the state of the glands in the small intestine?

DR. DARRACH.—The glands were not examined; diarrhœa had not been a symptom during life.

DR. STILLÉ spoke of the absence of diarrhœa as being a symptom of importance as regards the diagnosis between cancer and tubercle of the mesenteric glands. He believed that in an adult, tubercle of the mesenteric glands is very rarely, if ever, met with, without the glands of the intestine being affected. As here no diarrhœa existed, and as the signs of disease of the lung were evidently consecutive to those of the abdominal cavity, he thought the presumption, even during life, would have been strongly in favor of cancer.

Cancer of the Pancreas and Stomach.—DR. AGNEW presented a specimen of medullary cancer of the pancreas, with a similar deposit at the cardiac orifice of the stomach. The patient from whom they were removed (aged about fifty-six years) came under the care of Dr. Ludlow nine months ago, and from the character of the symptoms, the case had been diagnosticated as one of cirrhosis of the liver. The patient's first indisposition was three months previous; up to this period he had enjoyed good health. He was a good liver; fond of hot suppers and richly cooked

Digitized by Google

food; his hours of eating were irregular, sometimes very late at night; he used malt drinks habitually, and occasionally spirituous liquors, but not to any great extent. His weight at the time of his attack was 250 lbs. The first symptoms of indisposition were those of ordinary indigestion, with occasional nausea and oppression at the stomach, a feeling of fulness over the abdomen, and constipation of the bowels. The loss of a situation, which he had held for several years, depressed his spirits very greatly; and with this his physical distress increased rapidly. Vomiting occurred; pains of a flying character passed through his abdomen, chest, and right shoulder; the stomach rejected for a time all kinds of food; the matter vomited was of a glairy, viscid character, and exceedingly offensive; hiccough set in, and became very troublesome; also great accumulation of gas occurred, which could only be expelled by thrusting the fingers down the pharynx, in order to produce forcible gagging. His strength failed, and emaciation progressed rapidly. At one time nothing seemed to arrest the hiccough so well as small pieces of hoarhound candy; this, however, soon lost its effect, and the continued hiccough became very distressing. During the intervals of repose he would allow no one to move, shut a door, or even speak, as the least excitement would produce a violent return. The hiccough was finally controlled by small doses of strychnia and morphia. The vomiting and the unpleasant gastric symptoms were much benefited by a combination of ext. taraxici with an alkali and creasote, and by occasional small doses of calomel and bismuth. His complexion became pale and bloodless, and his countenance distressed; the eyes anxious; the pulse small and feeble. The bowels were very torpid; when moved, the evacuations were clay-colored, but sometimes of a greenish hue; the urine was high-colored, and deposited a heavy sediment; it contained bile and much mucus. Though latterly he was very much relieved of nausea and hiccough, yet emaciation went on rapidly; the fat disappeared almost entirely, and he appeared to die from entire want of assimilation.

Autopsy confined to the abdomen.—The body was reduced to about 120 lbs., its color indicating a cancerous cachexia. On turning off the abdominal walls, the tissues and organs were found to be perfectly blanched from want of blood; no peritonitis existed; the liver was in a complete state of cirrhosis, also enlarged; the gall-bladder empty; the kidneys were in a state resembling cirrhosis; the pancreas increased to more than four times its size, its glandular structure having apparently disappeared, and being replaced by a mass of brain-looking substance; the stomach, when opened, seemed to be healthy, except at the cardiac orifice, where a deposit similar to that in the pancreas existed. On examination by the microscope, both in the deposit in the stomach and pancreas, cancer-cells were found, remarkable for their great size and diversity of form. The rapid

Digitized by Google

emaciation Dr. Agnew attributed to a mechanical as well as a constitutional cause, namely, pressure of the pancreas on the thoracic duct.

Aneurism of the Aorta, bursting externally.—DR. PACKARD exhibited a specimen of aneurism of the aorta, and remarked as follows:—The patient, a colored man, aged forty-eight, was a porter in a carpet store, and kept at work until the latter part of February last.

In July, 1857, he had a cough, which, however, was not very severe, and soon afterward he perceived a swelling at the upper and front part of his chest. He applied to me in February, 1858, (seven months later,) with a swelling of the size of a large fœtal head, occupying the site of the upper part of the sternum, and extending more to the right than to the left of the median line. The pulse in the two carotids was almost alike,—that in the right radial was slightly less than that in the left. There was no numbness, but some pain, in the right arm, and a very marked pulsation in the tumor, but *no thrill whatever;* the clavicle on each side seemed bent and pushed forward, carrying the sterno-cleido-mastoid muscle along with it.

The treatment adopted was palliative; but the tumor enlarged so rapidly as to measure, on the 2d of May, 10¼ inches in semi-circumference from one side to the other, and 11 from above downward. Discoloration appeared at the most prominent part, and on the 6th of May, at 10 P.M., a small slough separated; some bleeding ensued, which was checked by means of a hemlock plaster till 6 A.M., on May 7th, when it recurred so violently that his death was instantaneous.

Autopsy 10½ hours after death.—The tumor only was examined; its anterior wall and the superjacent skin were extremely thin, and closely adherent to one another; they could, however, be separated with the fingers, except where traces existed of the sterno-cleido-mastoid muscle, and here the union was very close and firm. The sac being cut into, an immense clot was found in it, very firm below and in front, as well as at the posterior part, but becoming grumous above, toward the point where the fatal opening had taken place. Several ribs were felt projecting into the cavity of the sac on each side, in a roughened state, and a portion of the sternum lay imbedded in the clot, in a similar condition. The vessel involved was the ascending aorta and the arch; the innominata was increased in diameter to about an inch; the left carotid and subclavian were normal. Atheromatous deposits existed, to a great extent, in the descending aorta. The trachea was flattened, and pushed over to the left side of the vertebral column, which was sound; the lungs were healthy, but adherent to the tumor by their apices.

DR. DA COSTA stated that, through the kindness of Dr. Packard, he had had an opportunity of examining the patient during life, and it had struck

Digitized by Google

him, as a point of great interest, that not only was no thrill present, but also no blowing sound could be perceived. The sounds over the tumor were two sounds like those of the heart. The second sound was short and indistinct; the first was long and prolonged, and, if such an expression be permissible, weighty. They differed not only in strength from those of the heart, but also, it had seemed to him, in pitch; this was especially the case with the first sound. Both sounds of the heart, listened to at the apex, and ensiform cartilage, and at midsternum, near the aortic cartilage, were distinct, but not otherwise altered. The impulse of the heart was forcible, and somewhat extended.

DR. STILLÉ inquired into the probable production of these sounds in the tumor. Were they not produced in the sac?

DR. DA COSTA could not answer this positively. As the sounds were stronger than those of the heart, they could not have been transmitted sounds, unless we assume that they gained in strength by the peculiar physical conditions of the sac. If not thus produced, they must certainly have been generated in the sac.

DR. PACKARD did not believe that they were thus caused. He regarded the sounds heard over the tumor as the transmitted heart-sounds, since their similarity was very great.

Urinary Calculus.—DR. ALBERT H. SMITH presented, through the Secretary, a stone weighing 164 grains, which was extracted from the bladder of a child two years old, by Dr. Norris, in the Pennsylvania Hospital. The following history accompanied the specimen:—George Grater, aged two years, of Bucks County, Pa., was admitted into the hospital on the 3d of May, 1858. He has a light complexion, blue eyes, light hair, and looked quite anæmic, and very delicate and sickly; his countenance exhibited marked distress, presenting, for a child, a most care-worn expression. From the day of his birth he has suffered with incontinence of urine, the discharges being interrupted, and attended with great pain, and with excessive tenderness in the whole perineal region. He had great nervous irritability, deficiency of appetite, restlessness, morbid fear of strangers, fretfulness, and every symptom of a constitution worn and harassed by constant internal irritation. His parents stated that he has not passed a day since his birth free from acute suffering.

When admitted into the hospital he exhibited the same symptoms as above mentioned, besides having prolapsus ani and diarrhœa. By sounding, a calculus was detected in the bladder. On the 5th inst., Dr. Norris removed from this viscus, by the lateral operation with the gorget, a phosphatic stone weighing 164 grains. Notwithstanding the unfavorable condition of the child previously to the operation, he has not had an un-

Digitized by Google

pleasant symptom since. His restlessness and general irritability have greatly diminished; he sleeps well, has a good appetite, and, as his mother says, he seems more comfortable than he has ever been since his birth.

The most interesting feature of this case is the evidence of the affection being congenital. Cases of stone in new-born children are rare, so far as statistics show, though enough are recorded to prove their possibility. Civiale expresses himself entirely free from doubt on this point; and, although he has never seen a case himself, he quotes from Brendel a case of a child who passed a red sand, and dying on the second day after birth, its bladder was found to contain a stone of considerable size; also two cases of children in whom calculi were found in the fossa navicularis within twenty-four hours after birth. Numerous instances are also cited in children, of age ranging from two days to six months, in which there was probability of the stone having been formed in utero. That this affection is rare, however, in infants so young, may be inferred from the fact, that out of 5376 cases collated by Civiale there were only three under one year of age. One case mentioned as having been operated upon at that age was followed by death. The mortality in thirty-seven cases operated upon at two years of age was seven.

The size of the stone extracted from this boy is much greater than any that I have been able to find recorded as met with in a child of two years of age. The largest one mentioned at that age weighed one drachm, and is quoted by Crosse. It occurred at the Norwich Hospital.

WEDNESDAY EVENING, May 26th, 1858.

The President, DR. GROSS, in the chair.

Dilatation of the Meningeal Artery, producing a Bony Protuberance on the Head.—DR. AGNEW exhibited a skull-cap which had, on its internal surface, a very large groove for the meningeal artery. This groove terminated in a dilatation near the vertex, probably of an aneurismal nature. At the seat of the groove the internal table was absorbed, and the external table formed a considerable protuberance. The artery on the other side was large, but in its dimensions far inferior to that of the left side. The specimen was obtained in the dissecting room, and no history could be procured.

DR. STILLÉ would ask of Dr. Agnew whether he thought that this protuberance could, during life, have been distinguished from an exostosis, and its cause determined?

DR. AGNEW thought that a careful examination might have detected a thrill.

DR. STILLÉ had reference to this in asking the question. He also be-

Digitized by Google

lieved that a thrill might have been present, and thus served as a diagnostic sign. This aneurismal dilatation is extremely interesting. The occurrence of a tumor of the kind might lead to the erroneous supposition of a syphilitic exostosis.

DR. AGNEW believed that exostosis, syphilitic or otherwise, most frequently springs from the inner table, which, on the contrary, in the specimen before the Society, was absorbed.

DR. HARRIS did not agree with Dr. Agnew in this respect. He had a head in his possession, where, from a fall, an exostosis of the outer table had occurred.

DR. HEWSON also differed from Dr. Agnew with reference to this point. He had now a young lady under his charge in whom an exostosis had been developed after accidently striking her head violently against the door of a carriage. The protuberance was evidently produced by deposit on the external table. There had been no fracture, and there was no pulsation nor thrill to be felt, although the patient herself experiences a pulsation at times in the tumor. Dr. Hewson alluded also to the fact that pulsating tumors on the scalp, supposed to be aneurismal, might be of a malignant nature, as an interesting case reported by Dr. Neill proves.

DR. GROSS had seen several cases of pulsating tumors on the head, dependent upon dilated arteries. Two in especial were interesting. They were both of several years' standing, and led to absorption of the bony tissue, bringing thus the scalp and the dura mater in contact.

Bright's Disease—Fibroid Degeneration of the Kidney.—DR. MORTON presented a kidney filled with fibrous deposits. It was taken from a man who died in the Pennsylvania Hospital from effusion into the brain. Prior to his admission he had received a compound fracture of the leg, for which his limb was amputated at Norristown. The man, after being conveyed to the hospital, became comatose, and sank rapidly.

Urine taken from his bladder after death was examined, and found to contain granular casts. The kidneys, when cut into, presented a glistening whitish appearance, and were very firm in consistence. Microscopically examined, they abounded in fibrous tissue and fibroid cells.

DR. HEWSON spoke of the prognosis of amputation always being more unfavorable in cases in which the urine contained albumen, or showed, as pointed out by the observations of Bence Jones, signs of waste of tissue in the economy.

Imperforate Rectum.—DR. STILLÉ, on behalf of DR. J. FRANK BELL, presented the following notes of a case of *imperforate rectum*:—

Past History.—The mother of the child, healthy and multipara, was

Digitized by Google

delivered at full time on May 11th, 1858. The child was of good size, and appeared healthy; but on the third day, no meconium having passed, I saw it for the first time, and made an examination, when the following appearances were presented:—

A well-formed male child; seems healthy, and is tranquil; urine clear and passed freely; anus perfect; admits a probe three-fourths of an inch, when it meets with firm resistance; on very slight pressure against the probe the child cries.

Diagnosis.—The most simple form of imperforate rectum. An operation was deferred on account of there being no convexity of the membrane downwards.

May 15th, 2 P.M. Saw the child and made a second examination. The parts present the same appearance as yesterday. An old-fashioned ear speculum showed a well-formed *cul de sac*, with folds of mucous membrane at the bottom. There is still no protrusion, or convexity, of the membrane; abdomen tense in hypogastric region. Assisted by my friend, Dr. E. R. Duval, I punctured the membrane across the rectum with a medium sized trocar; after its introduction the stylet was withdrawn, when meconium passed through the canula. The trocar met with considerable resistance. The removal of the canula was followed by the discharge of one or two fluidrachms of blood of a bright-scarlet hue. The bleeding, however, stopped after a few moments, when the child was put to rest, and a dose of sweet oil given.

May 16th, 12 M. Some meconium passed last evening; also a small quantity this morning. The child rested badly last night; appears hungry, but refuses the breast; abdomen slightly enlarged; tympanitic. A medium sized catheter is introduced into the rectum with ease, but seems to be grasped at the point where the perforation was made, so that it turns on its axis with difficulty. An injection of warm water was thrown into the bowel, and was expelled with considerable force, accompanied by meconium and flatus; repeated injections procured a tolerably free discharge of meconium. Sweet oil was again administered.

May 17th, 2 P.M. No meconium passed since the last visit. The child rested well last night; nursed once in the fore part of the night; vomited twice in the latter part; vomiting not stercoraceous. The nurse thought it dying this morning at 10 o'clock. It, however, soon rallied; but has been growing gradually weaker since. Abdomen quite tympanitic; the child is very weak. The tube passed readily into the bowel, but is firmly grasped at the seat of the artificial opening; warm water injection used, which was expelled, accompanied by meconium and flatus; some toddy administered, after which the child rallied, but soon again began to sink, and died at 5 P.M.

May 18th, 7 A.M. Post-mortem examination twelve hours after death.—

Digitized by Google

Abdominal viscera normally situated; extensive peritoneal inflammation; mucous membrane of stomach and intestines healthy down to the rectum; the lining membrane of the latter highly injected; the rectum is surrounded, three-fourths of an inch above the anus, by what appears to the naked eye to be a fibrous deposit; it is one-half inch in length, and had been perforated by the trocar, leaving its walls one-fourth of an inch thick; it is quite firm under pressure, and cuts with a very perceptible grating noise; the rectum, immediately above this, was four or five times its normal size. There was no microscopic examination made of the part. The bladder, kidneys, and other abdominal viscera were perfectly healthy. No other cavity was examined.

Remarks.—Death in such cases is the rule; my case, as the record shows, forms no exception to it, and presents in this respect nothing peculiar. When the case was examined before the operation, it exhibited all the appearances of the most simple form of imperforate rectum, viz.: a simple membrane extending across the bowel, with these exceptions, that there was no convexity, or pouting of the membrane downward, and very slight pressure against the probe when the child cried. The absence of these symptoms is readily accounted for, by the dense deposit found surrounding the rectum, in a ferule-like manner, or rather taking the place of the rectum. The rectum above was continuous with the deposit, and its large size here may have been the result of the accumulation of meconium and gas after the birth of the child. In the *Boston Medical and Surgical Journal* for February, 1858, p. 512, I notice that Dr. J. B. S. Jackson thinks that the enlargement in the lower extremity of the bowel, in imperforate anus, is not due entirely to an accumulation after birth.

In all of the recently reported cases that I have examined, and in several surgical works, I can find nothing spoken of that resembles the one above reported, in regard to the fibrous deposit; but in the *Medical Facts and Observations*, London, 1791, vol. i. p. 238, I find a case reported by "Mr. Edward Ford, Surgeon of the Westminster General Dispensary," accompanied by a drawing of the rectum and deposit, as found at the post-mortem examination. This drawing is a true representation of the parts, as found in the case above. He says, in speaking of his "dissection," that "the rectum terminated in a blind pouch, at the distance of an inch from the anus, in the hollow of the sacrum. The space between the intestine and anus was lined by an inelastic ligamentous substance, which would probably have produced much inconvenience to the patient in retaining his stools, had the operation performed protracted his existence."

He does not mention whether there was or was not the grating noise under the knife; otherwise, so far as I can see, the two cases are precisely

Digitized by Google

alike pathologically; and had my patient lived, I can readily understand that he would have presented all the symptoms of one laboring under well-marked stricture of the rectum.

DR. HARRIS related a case of a child which had been operated on for imperforate anus forty-eight hours after birth. The intestine above the stricture formed a *cul de sac*, which was very large. The child lived twenty-two months after the operation, but was never in very good health. It died of a diarrhœa, brought on by eating fruit. Seven cherry-stones were found above the seat of stricture; they could not pass through the opening.

DR. GROSS thought that in very many cases there is a dense, fibro-cellular band in which the bowels terminate. It forms a barrier, an inch to an inch and a half in length, and gives rise to much difficulty, even after the operation.

DR. HEWSON believed that most cases of imperforate anus arise from arrested development, and not from morbid growths. In the fœtus these parts are all developed from the same structure, and in the earliest stage of fœtal life there is no communication between the anal orifice and the bowel. Now, in some cases of imperforate rectum, we meet with an opening into the vagina, which, as the rectum and vagina in fœtal life communicate, would prove many of the cases to depend upon an arrest of development.

DR. STILLÉ did not think that this could here be the case, since under those circumstances no increase of fibrous tissue occurred. Nor did he believe that the case was one where the bowel terminated in a fibro-cellular band. The fibrous substance here existed not only between the two parts of this bowel, but in large quantities around the termination of the upper portion of the rectum. The great thickness of the fibrous formation prevented this portion from being pressed down in a sac-like form.

Serous Apoplexy of the Retina.—DR. ADDINELL HEWSON related the history of the case of an Irishman, a bootfitter by trade, affected with this lesion. The patient was aged thirty-seven years, married; of a scrofulous diathesis; partially bald; and had grayish-blue eyes. He was an industrious man, and followed his trade steadily from 6 A.M. to 12 P.M., and was obliged to tax his sight at his work. But, although he was not intemperate, he was in the frequent habit of dram-drinking.

One day in the month of August last he went out through the broiling sun, about noon, into the yard to urinate. On his return to the house he was suddenly seized with a peculiar dimness and imperfection of vision in his left eye. One-half of everything he looked at with this eye appeared to possess a bluish-yellow or greenish hue, and to be hollow or

Digitized by Google

flat as the object was either really plain or convex. Dr. Hewson saw him six weeks after this occurrence, these symptoms were still present though not as intense as they were at first. There was to the unaided vision nothing apparently the matter with the eye. The pupil was natural, regular, uniform, and responded promptly to the light. The ball seemed very firm. The ophthalmoscope revealed an effusion between the hyaloid and retina, of a reddish-yellow color, and extending over the right hemisphere of the eye. Through this effusion the vessels of the retina could be but indistinctly seen; they appeared large and seemed to project forward, as though the effusion had taken place behind as well as in front of the retina. This fact could be especially well perceived at the points where the vessels passed from the circumference of the optic nerve to be distributed to the retina. This patient was blistered very frequently on the temple, and put on Plummer's pill, gr. iij., thrice daily. Under this treatment he rapidly recovered his vision and was quite well by the end of October. During the progress of his case he was frequently examined, and the absorption of the effusion readily noted.

Cancer of the Liver and Mesenteric Glands.—These specimens, which had been previously exhibited to the Society, were removed by DR. BRAGG from a patient under the care of Dr. S. W. MITCHELL at St. Joseph's Hospital. The following description was given:—

The liver and mesenteric glands were markedly cancerous. The liver was also in a state of fatty alteration and greatly enlarged, so that the stomach was displaced and thrust to the left side,—the cardiac portion being in the left hypochondriac region, and the pyloric extremity in the left iliac fossa. The organ was enormously distended, and presented numerous ulcerations and two small cicatrices upon its mucous surface. The cancerous tissue was soft, and composed principally of large cells and free nuclei. The cancerous portions of the liver were light in color, and level with the surface of the organ. All other organs were healthy.

The more remarkable points in connection with this case were the total absence of pain and of burning, even when irritating condiments were used as food. Pressure over the region of the stomach also gave no pain, but pressure below the ensiform cartilage really affected the liver and not the stomach, which was, as above stated, completely dislocated. Vomiting was almost the only evidence of the presence of ulcers in the stomach, and this symptom easily yielded to $\frac{1}{8}$ gr. doses of nitrate of silver. The existence of cancer of the liver was diagnosticated during life; but the great bulk of what was felt as a solid tumor in the epigastric region was due to the increase of the size of the liver from fatty deposit, while the mass of the cancer lay behind both liver and stomach in the mesenteric glands.

Digitized by Google

WEDNESDAY EVENING, June 9th, 1858.

The President, DR. GROSS, in the chair.

Dilatation of Heart, with Adherence of the Pericardium; Deposits of Lymph in the Liver; Solidification of the Lung; Disease of the Kidney.—DR. DARRACH presented a diseased liver, heart, and lung; they were removed from Mr. B., aged nineteen years, who had, when about six years of age, a very severe attack of scarlet fever, which left him much prostrated. His attending physician stated that anasarca had been present. The urine was not examined; most likely his kidneys, at the time, were affected. The patient, however, recovered; but it was not a great while afterwards before he exhibited evident signs of disease of the heart. Since, he has been feeble, and, up to the occurrence of death, has suffered more or less severely from a cardiac affection, yet having sometimes rather prolonged intervals of comparative health.

During his last attack he suffered very much; his lower limbs became exceedingly swollen, so that the skin on his feet burst in several places. There was extended and marked dullness over the heart. No abnormal sounds could be distinguished. The impulse of the heart was diffused and fluttering, but without force of beat. The sounds were not marked nor distant, from which signs the conclusion was, that there existed dilatation of the heart without valvular disease. Posteriorly, mucous and sub-crepitant rales could be heard in the lungs. There was also great dullness on the right side, but no blowing sound could be perceived. The general appearance of the patient was that of one laboring under disease of heart, or albuminuria. The urine was examined a short time before death, and a large amount of albumen was found in it.

Sectio cadaveris.—The cranium was not opened. The lungs were found adherent, throughout their whole extent of surface, to the walls of the chest. The pericardium was in the same condition. Posteriorly, the lower half of both lungs were solidified. The heart was found dilated; its walls not thicker than normal. The pericardial sac was entirely obliterated by the adherence of its approximate surfaces. The mitral valves, and semilunar valves of the aorta were very slightly thickened, but not by any means insufficient. There were extensive washed clots in all the cavities, and at the commencement of the larger vessels.

Abdominal region.—The liver was enlarged, and very firm and elastic to the touch. A cut surface presented brownish yellow and black markings, somewhat resembling a nutmeg liver. The kidneys were larger than normal; the left one was evidently in an early stage of degeneration, being of a yellow hue, which contrasted strongly with the healthy appearance of the other renal organ.

At first sight one was struck with the oily appearance of the yellow por-

Digitized by Google

tions of the liver; but the color was more of a brownish hue than is occasioned by an oily deposit in that organ; and when, by a microscopical examination, no cells containing oil, nor any free oil globules were found, but, on the contrary, cells less than usually granular, and also much free granular matter, the conclusion that suggested itself, both from the above as well as from the appearance of the organ to the naked eye and its firm, elastic feel, was, that it was not really in a state of fibroid degeneration, but that unorganized lymph had been deposited in the organ, about the capsule of Glisson—perhaps, if the person had lived, to be formed into fibroid cells, but as yet none had made their appearance, or at least could be discovered.

The deposit which produced the solidification of the lungs, no doubt was of the same nature; and the same condition was, likely, commencing in the kidney; a universal lymph deposit having taken place from some fault in nutrition.

Ulcers on the Tongue, Larynx, and in the Bronchial Tubes; Tubercle in the Lungs and Kidney.—DR. MORTON presented, for Dr. Hutchinson, a tongue and larynx covered with numerous ulcerations, also tubercular lungs and kidneys. These specimens were removed from C. N., aged twenty-three, a native of Germany, who was admitted into the Pennsylvania Hospital on June 3d, for syphilis, and who died suddenly from œdema of the glottis, on Monday morning, June 7th. When admitted, he was in a state of great debility; his eyes were the seat of a severe inflammation, and he had a very haggard expression; he suffered from diarrhœa; his face was covered with an eruption resembling rupia, which was also found upon other parts of his body; his tongue and palate were horribly ulcerated. It was afterwards ascertained from his physician, Dr. Demmé, that during the winter of 1857 he had contracted a chancre, which soon became indurated. On the 14th of April, of this year, Dr. Demmé describes him as presenting an extremely emaciated appearance, and complaining of soreness in his eyes, a frontal headache, of an uneasiness in the throat, and of a profuse and fetid muco-purulent and bloody discharge from the nose. An examination showed in one nostril, upon the septum, a deep, excavated ulcer, with well-defined edges, at the bottom of which the vomer was exposed, denuded of its periosteum. The course at that time adopted was a mercurial treatment, and injections into the nose of a solution of chlorate of potassa; subsequently he was placed upon the iodide of potassium in five-grain doses. About the 4th of May his eyes became very much inflamed, his appetite failed much, his breath was foul, and he complained of great uneasiness at the throat; but the disease in the nose he declared to be cured. Iron and bark did not remedy the progressing debility, nor did any applications stay, excepting temporarily, the disease in the throat. His

Digitized by Google

eyes, after having greatly amended, became again suddenly much worse, presenting most characteristically the appearance of scrofulous conjunctivitis and corneitis. The lungs, which were at that time examined, sounded clear on percussion. There was no cough, nor were there any symptoms which pointed to the liver or kidney. Toward the middle of the month, rupia-like ulcers appeared upon the skin, and on the mucous membrane of the mouth and tongue, and an exhausting diarrhœa set in. It was in this state that he was carried to the Pennsylvania Hospital.

Post-mortem examination eight hours after death.—The tongue was one mass of distinct ulcers from end to end; the entire top of the organ was eaten away. Some of these ulcers appeared, on close inspection, to be situated on the surface of an exuded whitish matter, or a degenerated substance, and not directly on the tissue of the tongue itself. They extended, forming a continuous line, through the larynx into the smaller bronchial tubes. The tip of the epiglottis was destroyed, and also the vocal chords; the lungs were filled with infiltrated tubercle; tubercular ulcers were situated throughout the small intestine; the kidneys had large patches of infiltrated tubercle scattered throughout their structure. The cortical and the tubular tissues had, in parts, entirely disappeared. In the left testicle was a small softened spot, which had the appearance of a commencing abscess.

DR. MORTON directed the attention of the Society to this case as combining lesions produced by syphilis, with tubercular disease of several organs. It was difficult to say which of the ulcerations were produced by syphilis. The ulcers on the tongue and larynx might be syphilitic or tubercular.

DR. GROSS inquired if the ulcers on the tongue had an indurated base.

DR. MORTON stated that it had seemed to him as if the tissue around the ulcerations was dense and hard.

DR. BRINTON asked if the glands of the neck were indurated.

DR. MORTON had not perceived them to be.

DR. KELLER thought it a difficult matter to determine whether syphilis had preceded or followed the tubercular deposits. From examining the specimens on the table, he was inclined to believe that the tubercular matter had been deposited in the different organs at different times. The disease of the kidney was evidently much older than that of the lungs.

Perforation of the Aortic Valves.—DR. MITCHELL presented, for Dr. Darby, a specimen of disease of the aortic valves, with Dr. Darby's account of the case. The patient from whom it was obtained, Thomas Darley, a boatman, thirty-five years of age, was admitted, on Thursday, May, 21st, into the St. Joseph's Hospital, exhibiting signs of great suffering and de-

Digitized by Google

bility. His face was pale; his lips were colorless; his eyes heavy; the extremities cold and clammy; his forehead was covered with large drops of sweat, and his hair as moist as if he had been under a shower-bath. While making arrangements for entering him as a patient, he complained of so much weakness and nausea that half an ounce of brandy was administered, and he had to be assisted into the ward and undressed by an assistant. On being placed in bed, he immediately vomited about six ounces of fluid, resembling coffee grounds, covered with froth, and of a sour, fetid odor. In the ejection of this fluid he suffered intense pain, and complained of great burning in the region of his stomach. Being for the time unable to answer questions, he gave, after a period of several minutes, a rather disconnected history of his case. He had been quite suddenly taken sick on the Friday previous, with great weakness, much nausea and pain in the epigastric region; he did not think it would last, and went on board the boat in New York, but found, on the first day of the passage, all symptoms increasing, so much so that he could not do duty; and, on going to bed, was unable to lie on his left side. His bowels at first were loose, and a cough soon commenced, which produced great pain over the whole of the hypochondriac and epigastric regions and left side of the thorax; he expectorated thick, white, frothy sputa, without any discoloration. He had been unable to eat anything since he was taken sick, on account of constant vomiting, but he drank a great deal of water, as it cooled the burning in his stomach. From intense pain in coughing or drawing a long breath, he had not slept since the attack; no medicine had been taken; but to relieve pain he had placed a tar plaster over the region of his stomach.

On examination, his pulse was found threadlike, and beating 104 in the minute; his tongue was dry and thickly coated, and his whole abdomen was tympanitic; the stomach was much distended, felt hard, and was exquisitely painful to the touch; there was much dullness, on percussion, on the left side of the chest, particularly over the region filled by the posterior lobe of the left lung, and on the left side the respiratory murmur could only be heard beneath the clavicle. On the right side the respiration was puerile. His heart palpitated violently, and a bellows murmur could be heard over the aortic valves, and as high as the arch of the aorta; his breath was so fetid as to render it unpleasant to remain near him; his cough was harsh, dry, and frequent, causing great pain during the paroxysms, which were of some length.

From this time the patient lingered for two days, suffering from symptoms of gastritis, and annoyed by vomiting and great oppression of breathing. The vomited matters were composed of mucus, bile, and altered blood; his pulse ranged between 90 and 100. Death took place

Digitized by Google

suddenly, about twenty-four hours after his admission, and while he was in the act of turning over.

Post-mortem examination eighteen hours after death.—The heart was much enlarged, and the auricles were relatively more dilated than the ventricles. The only valves found diseased were those of the aorta; the edges of two of the discs of these valves were much thickened, and the valves were pierced by three perforations; the muscular structure of the right auricle was separated in longitudinal sections, as if cut by a knife, and was only held together by connective tissue. There was no actual perforation of the auricle, for no blood was found in the pericardium; yet it was so thin as to present the appearance of being ruptured; and not until the auricle was distended, by water being poured into it, was the fact proved otherwise. There were two quarts of watery effusion in the cavity of the thorax, compressing the left lung to one-third the natural size. In other respects the lungs appeared healthy. The stomach was filled with a dark and fetid fluid, and the structure was much changed, being emphysematous when rubbed between the fingers. The mucous membrane was elevated, decomposed in parts, and much inflamed in the middle portion, the inflammation extending toward the pyloric orifice. This inflamed portion was traversed by enlarged vessels, and in other parts of the stomach dark-greenish colored spots were seen. The liver was decreased in size, and such considerable force was required in tearing it, or pushing the fingers through its structure, as to induce the opinion that there was cirrhosis. The other viscera presented no abnormal appearances.

WEDNESDAY EVENING, June 23d, 1858.

The President, DR. GROSS, in the Chair.

Syphilitic Ulceration of the Larynx.—DR. HALL exhibited a specimen of syphilitic ulceration of the larynx. It was obtained from an Irish woman, unmarried, aged thirty-six, of robust frame, but of a worn, slightly haggard expression, who was admitted into the medical ward of the Pennsylvania Hospital, August 31st, 1857, for laryngitis, under the care of Dr. Gerhard. The most prominent symptom, and one that directed attention immediately to the site of the disease, was the harsh, stridulous respiration. Her pulse was good, and there was none of that purplish appearance about the face to indicate much obstruction to the circulation in the lungs. Percussion revealed no dullness; over the front and back portions of the chest there were merely some few bronchitic rales to be heard.

Owing to her dyspnœa and apparent reluctance to answer questions, not much information could be obtained from her, beyond the fact that she had

Digitized by Google

been sick for four weeks—the result of a cold she had taken. With a view of promoting diaphoresis and relaxation, vin. ipecac. in syr. scilla was ordered every two hours. She was placed upon a good supporting diet, with beef essence and broth.

At the evening visit, the dyspnœa still continuing, calomel, half a grain, and nitrate of potassa, ten grains, every two hours, were ordered. A blister, two inches square, was applied over the throat.

At midnight she was breathing very much better; there was very little stridor; she was sleeping, and seemed to be much improved.

At 4 A.M., of September 1st, Dr. Hall was aroused in haste, but, on reaching the bedside, found that the patient was dead.

Examination ten hours after death.—Head, nothing abnormal. Lungs and heart perfectly healthy. The liver, stomach, spleen, kidneys, bladder, and intestines, also healthy. The right labium externum was the seat of two excavated chancres with indurated bases.

The immediate cause of death had been œdema of the glottis and of the rima glottidis. In the larynx were two ulcers, each the size of a ten-cent piece; one just below the upper border of the thyroid cartilage in the median line, superficial in character; the other, situated over the cricoid cartilage on the left side, extended deeply, and had produced corrosion of the cartilage, and formed an abscess external to the larynx in size, of two and a half inches by two inches in breadth. The walls of the abscess were much thickened, and contained a small quantity of thin, fetid pus.

This case is one of interest, from the nature of the affection, and from the light thrown upon it by the post-mortem examination. The ulceration of the larynx might be mistaken for tubercular deposit; the absence of tubercle in the lungs and other organs, together with the inflammation and destruction of the cartilages of the larynx, went to disprove this—the presence of the chancres on the labia forming conclusive testimony as to the character of the ulceration in the throat.

Langston Parker calls it one of the most formidable varieties of constitutional syphilis, and says that he has seen several examples of it. Ricord, Cazenave, and Carmichael, of Dublin, have reported others. Hasse says that the cricoid cartilage is the one principally affected. He also speaks of the purulent cyst, external or internal, to the larynx or trachea; both of which observations are verified in the specimen presented to the notice of the Society.

When a student of Prof. Pancoast, Dr. Hall continued: I saw a case of this disease, in which the man was almost moribund; but, upon tracheotomy being performed, the patient rallied, and, after a doubtful period of successive improvements and relapses, recovered his health, although with the loss of a portion of the laryngeal cartilages.

Digitized by Google

In this case just reported, tracheotomy would also have been performed, had the patient not sank so rapidly.

Chronic Abscess of the Brain.—DR. GROSS exhibited a specimen of abscess of the brain sent to him by Dr. W. M. King, one of the resident physicians of St. Joseph's Hospital of this city. The patient was an Englishman, twenty-one years of age, and was admitted on the 8th of November, 1857. He had been a flax-dresser, and consequently led a sedentary life. A short time ago he had emigrated to this country, and during the voyage he had suffered much from the want of the necessaries of life. Soon after his arrival he had repeated epileptic attacks, followed by hemiplegia of the right side, which, however, retained its sensibility. His pulse was small, only forty-five beats a minute; pupils acted readily under the influence of light; the tongue was black; the stomach irritable; and bowels costive. The speech was slow and rather difficult, and he complained of pain through the temples. The treatment consisted in regulating the bowels, applying cold to the head, and administering iodide of potassium and mercury. This course was continued until the 12th of December, when he was able, with the aid of a crutch, to hobble around his room. His appetite had greatly improved, and his pulse had averaged about fifty beats a minute. His articulation, however, was rather worse, and his right arm was perfectly useless. From this time he grew gradually worse; he suffered from constant irritability of the stomach, and, at the end of a week, he had several violent epileptic convulsions. The attack came on in the following manner:—He would fall back apparently lifeless; his extremities were stiff, and he foamed slightly at the mouth; his respiration was feeble, and his pulse was beating at the rate of forty-five a minute. After remaining in this condition about fifteen minutes, he would draw several deep respirations, and gradually revive; but in a few moments another convulsion, more violent than the preceding one, and of much longer duration, would take place. On the 26th of December his appetite still continued good, although he could retain nothing on his stomach; he slept well, but when he awoke was in a stupid condition, with his eyes partially closed. He had ceased to complain of the headache, which had been so troublesome. In a few days he had almost entirely lost the power of deglutition, and, upon assuming the semi-erect posture, he fainted. On the 5th of January the patient had several convulsions, and died quietly early the following morning. On dissection, the brain seemed to be atrophied, and so much softened that a stream of water, when allowed to fall upon it from a slight height, washed away a considerable portion of its substance. In the interior of the left hemisphere there was a large abscess containing about two ounces of fetid pus, and lined by a thick secreting membrane.

Digitized by Google

Cancer of the Fundus and Body of the Uterus Perforating the Rectum.—This specimen, presented by DR. HARRIS, was obtained from the body of a married lady, aged fifty-four years, who was affected with cancerous disease (dating from the time when the first symptom of uterine disturbance made its appearance) for about four years and three months. In early life, and up to the period when the disease commenced, she was remarkably healthy, and for some years anterior to the cessation of her menses, had been of very full habit. At the age of forty-eight she ceased to menstruate, and no bloody discharge came from the uterus during the two succeeding years. A sanguine fluid then commenced to escape from the vagina in small quantity, and this discharge continued without intermission, until the disease was so far advanced that the nature of the fluid became changed by admixture with broken-down cancerous tissue and purulent secretion.

For about two years and five months there was no pain attendant upon the disease; the patient very slowly lost flesh, which was not much remarked by her friends, who supposed it to be due to the effects of age, as she made no complaints of ill health, and called in no medical advice. The first severe pain experienced came on immediately after taking a cold plunge bath; it was felt in the iliac regions, and was of a lancinating character. From this time until a few weeks anterior to death, a period of about twenty-one months, this pain returned daily with a gradually increasing severity, until in a few months it became excruciating, and required a constant resort to anodynes to relieve it. For a long time it returned at a regular hour each day or night; it was occasionally much less acute for a day or two, and sometimes for several days was reduced to a form much more readily to be endured; after which the lancinating character of the paroxysms would return.

Medical advice was first called in about twenty months before death; at which time there was a constant oozing of blood from the uterus, though small in quantity, and a daily paroxysm of pain, as yet not very severe. There was no tenderness of the abdomen upon pressure, the patient being in the habit of forcibly compressing the abdominal walls, and striking herself in the iliac region for the purpose of alleviating her sufferings; and no tumor could be distinguished by the most careful palpation. A vaginal examination, either by the touch or speculum, was not permitted, so that the diagnosis had to be made from the two symptoms mentioned: viz., lancinating, paroxysmal pain, and constant menorrhagia, taken in connection with the fact that the parents of the patient had died of cancerous disease. The malady was pronounced cancer of the uterus, and treated as such.

After being under medical treatment a little more than a year, the patient, by much persuasion, was brought to submit to a per vaginam ex-

Digitized by Google

amination. The uterus was then found enlarged, and its cervix very hard to the touch, but smooth upon its vaginal surface; the whole organ, judging from the size of the neck, was thought to be quadruple its natural dimensions, which could be more readily determined, as the patient had never borne children.

Seven or eight months before death the discharges from the vagina became slightly changed in character, purulent matter being mixed with the bloody fluid, and pus was soon afterwards found in the excrementitious matters from the rectum. The purulent matter escaping from the vagina gradually increased, and became fetid, though seldom so offensive as not to admit of the odor being corrected by the use of chloride of lime or other disinfecting agents.

About four months before death, fecal matter commenced to pass by the vagina, and toward the latter period of life, nearly the whole of the excrement passed through this channel. Frequent urination became necessary to the comfort of the patient, owing to the pressure of the enlarged uterus upon the bladder preventing its distention, though the act was not always readily performed, for upon two occasions it was attended with very severe pain; the fluid was retained for a considerable time. On the last of these occasions (nine weeks before death) the urine was not passed for twenty-four hours, and the distended bladder, by pressing upon the uterus, produced an alarming hemorrhage, after the occurrence of which, a voluntary evacuation took place.

Defecation was painful and exhausting during the latter months of existence. Before perforation of the rectum took place the bowels were generally costive,—four days to a week sometimes elapsing without a passage. No diarrhœa ever occurred except upon one occasion, when it was owing to the patient, unknown to the medical attendant, taking an active cathartic; the attack lasted two days.

During the nine weeks subsequent to the attack of hemorrhage, the patient remained continually in bed; suffered much less pain than formerly, except an occasional paroxysm; lived almost exclusively upon milk-punch; passed large quantities of puriform matter, mixed with fæces, from the vagina; and was troubled much with nausea, and, when she attempted to take any solid food, with vomiting. During the last few days she suffered but little, and died finally from exhaustion.

Autopsy, made sixty hours after death.—Body much emaciated, considering the size of the patient when in full health; but not so much reduced in the extremities, particularly the lower, as is often found in subjects that have died of cancerous affections. The trunk was very thin, and the abdominal parietes flattened, but the opposed portions of the thighs, at their upper portion, still retained a considerable adipose deposit, the skin covering which was red and excoriated from the vaginal

Digitized by Google

discharges. The abdominal walls contained but little fat, and were so much contracted that scarcely any trace of the umbilicus could be discovered. When the abdominal cavity was laid open, the omentum was found to be joined to the fundus of the uterus; and in front of this adhesion the cavity of the womb communicated with the cavity of the abdomen by an irregular aperture, with very soft and rotten edges. In drawing up the omentum to examine more minutely the extent of the adhesion, the adherent portion of the uterus was detached from the remainder of the organ, thus enlarging the opening in the fundus. The body of the omentum presented no abnormal condition, except that it was somewhat more dense and thick than it is usually found. The caput coli was also joined to the uterus, and the vermiform appendage was united by a deposit of lymph to the side of the colon, and was also involved in the connection with the uterus. The large intestine, except the adherent portion, was found healthy from this point to the commencement of the rectum, where were discovered two oval gangrenous perforations near to each other; one large enough to admit the end of the forefinger, the other of smaller dimensions. The liver had undergone fatty degeneration, presenting the most perfect example of this pathological condition I have ever met with. It was very light in color, solid, greased the knife used in cutting into it, and under the microscope showed very large fat-cells. The spleen had undergone no change. The stomach contained between one and two ounces of brownish-yellow bile, and its mucous membrane was much stained by this fluid, but the organ was unaltered by disease. The kidneys were imbedded in fat, and contained adipose deposits in their calyces, but the tissue proper was unaffected. The small intestine and mesenteric glands were healthy.

FIG. 6.

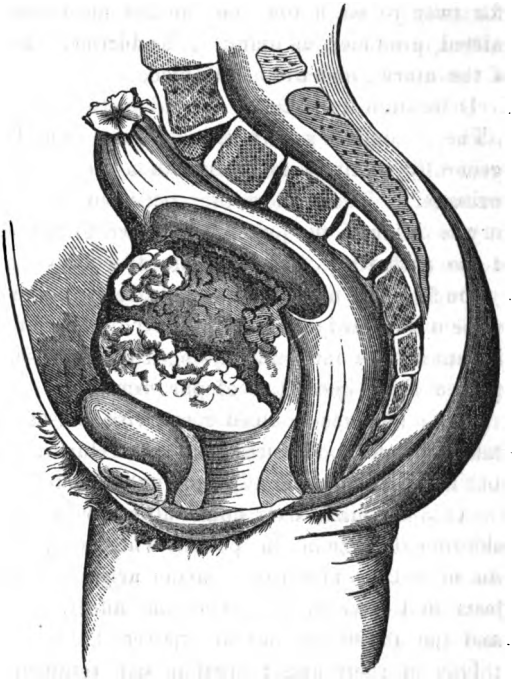

The uterus was found

Digitized by Google

to be the main seat of disease. It entirely filled the pelvis, with the exception of the space occupied by the contracted rectum and bladder; its fundus was on a level with the superior strait, which accounted for its not having been felt during life. The rectum was more in the median line than usual, and the sigmoid flexure more to the right side. The whole of the pelvic contents were dissected out in mass, and a more minute examination revealed the following:—The ovaries were cancerous, but not larger than natural; the uterus had undergone cancerous degeneration; the os was oval, soft, patulous, and readily admitted the thumb; the cervix was short, very much developed laterally, and had lost its scirrhous condition; the cavity of the neck and body of the organ was greatly enlarged, being capable of containing four or five ounces of fluid, and was filled with a pultaceous mass, composed of broken-down cancerous tissue and fecal matter; the posterior wall of the body of the uterus was united to the anterior of the rectum, and the cavities of the two viscera, communicated by an ulcerated opening an inch wide and three inches long; the non-adherent portion of the rectum was contracted, most probably from want of use, as it was not diseased; the vaginal surface of the cervix was not diseased, and there was no protrusion of fungus through the os; the vagina was found much shorter than natural, and dilated at its uterine extremity to more than two inches in diameter—no cancerous disease existed in its mucous lining. The bladder was united to the anterior wall of the uterus, and was contracted, but the disease had not extended entirely through its walls.

The abdominal cavity contained no effused fluid, pus, or fæces; and, besides the points of adhesion mentioned, there was no other sign of local peritonitis. The perforation at the fundus of the uterus must have been very recent, and most probably occurred after death, by the decomposition of the part, which was very thin and soft,—an event which was favored by the fact that the body was not placed under the preservative influence of ice until twenty-four hours after death. The utero-rectal communication must have existed for at least six months, for as early as that, purulent matter escaped through the rectum.

The soft cancerous matter contained in the cavity of the uterus, when examined under the microscope, exhibited broken-down cells, having nothing characteristic of cancerous disease. The cancer tissue proper was of a medullary character, and easily broke down under pressure; the microscope revealed in it an abundance of oval cancer-cells, with nuclei and nucleoli. This cancer tissue appeared to the naked eye to be infiltrated in the tissue proper of the uterus, constituting a form of disease known as *Infiltrated Medullary Carcinoma.*

This case presents several points of interest which are worthy of our

Digitized by Google

attention, as bearing upon the anticipation and recognition of internal cancers.

1st. The patient was an example of that remarkable robust health so commonly enjoyed by those in whom there exists a strong hereditary predisposition to cancerous disease. Both parents and a half-sister having fallen victims to cancer, her healthy appearance was an additional reason for the anticipation of the same disease; and the first symptoms of uterine disturbance, under such circumstances, would naturally lead to a suspicion of cancer, and greatly assist in making a prognosis of the case.

2d. The medical history of the family of the patient goes to show that cancerous parents are very apt to transmit cancer to their children, but that the seat of the disease in the latter is less influenced by the former than its nature. In the father the disease was seated in the cervical glands; in the mother in the mammæ; in one daughter by a former wife, and in the case here reported, in the uterus. The cervix uteri is the most common seat of cancer, and where there is an hereditary predisposition in a female, this point is most apt to be attacked, no matter what be the seat of disease in the parents. In some rare instances, however, we meet with cases where not only is the disease the same in form, but it occupies the same situation (though an unusual one) as it occupied in the parent. In a patient under my care in 1848, a cancer as large as a small orange occupied the extremity of the nose; the father of the woman died of the same disease, similarly situated. This woman was also remarkably robust previous to the commencement of the disease.

3d. The entire freedom from abdominal tenderness that existed, detracts from the reliability of this symptom as an evidence of the existence of cancer of the uterus.

4th. The inability to detect by palpation the presence of cancer of the body of the uterus, is no evidence that it does not exist, as the prolapsed condition of the womb may render its being felt impossible, even in an emaciated subject.

5th. The absence of pain in the early stages of uterine cancer may readily mislead us in making a diagnosis, where a per vaginam examination cannot be obtained, as menorrhagia may arise from a variety of causes other than the existence of scirrhus. Where there is an evident predisposition to the disease, the return of the menstrual discharge after a long period of cessation is to be regarded as a dangerous symptom, and particularly in those who have previously enjoyed vigorous health.

The specimen of disease before us exhibits what it is rare to find in uterine carcinoma, *i.e.* extensive disorganization, without ulceration of the cervix and vagina. The primary seat of the malady, instead therefore of being the neck, which is almost universal, must have been the body of the uterus, and, judging by the ulceration, that portion of it contiguous

Digitized by Google

to the rectum. The total destruction of the neck of the uterus, upper portion of the vagina, and contiguous walls of the rectum and bladder, is much more common to be met with than perforation of the rectum or bladder, without ulcerative destruction of the cervix. In this, as well as in all the cases of cancer of the abdominal or pelvic viscera I have examined, there were no signs of general peritonitis manifested during life, or found after death. Cancerous union of viscera it is common to meet with, and this is in all probability preceded by a subacute local peritonitis; but general peritoneal inflammation is rare in cancers of the abdominal or pelvic organs, particularly where the uterus is the seat of disease. Another marked feature in uterine cancer is, that with the exception of contiguous viscera, which are diseased by extension from the primary seat, cancer is rarely found in other organs, not even in the mammæ, with which there is such a marked sympathetic connection. Occasionally, in cases of long duration, a deposition of cancerous matter takes place in organs not contiguous. The liver, lungs, and glands of the groin are most apt to be thus affected.

DR. GROSS would ask whether Dr. Harris did not think that the rectum and uterus had become simultaneously affected? There was evidently much disease of the rectum; and it seemed to him not improbable that it had become cancerous at the same time, or shortly after the uterus, and was not simply an extension of the disease of one organ to another.

DR. HARRIS believed the case to have been a primary cancer of the uterus extending to the rectum. There were no signs of disturbance of the intestine until the last year of life, while long anterior to this, signs of a morbid state of the uterus existed.

DR. WOODWARD directed attention to the fatty degeneration which had here existed. He felt persuaded that in cancerous formations, fatty degeneration of organs, not themselves affected with cancer, very frequently occurred; indeed, almost as frequently as in tubercle. He had especially noticed this in the liver and heart. He also alluded to some recent observers, who had stated that, in malignant growths of the uterus, the muscular fibres increased. He would ask whether this had been noticed in the specimen just described?

DR. HARRIS answered, that in the parts examined by him with the microscope no fibres of any kind were perceived; but he had not specially examined those portions of the cancerous mass which stretched into what appeared to be the still healthy structure of the uterus.

Cysts of the Thyroid Gland.—DR. AGNEW presented, for Dr. S. W. Gross, a serous cyst of the thyroid gland, with the history and an account of its minute structure. Mary Neff, aged twenty-five, a widow, with one child three years old, came to the Jefferson College Clinic, on the 19th of

Digitized by Google

April, on account of a swelling in the median line of the neck, just above the sternum. She said that her attention was first directed to it by her friends, five weeks previously, when it was the size of a filbert. It rapidly increased, causing a sense of fullness in the throat and slight impediment to respiration and deglutition. Her general health was not good; she occasionally felt sick at the stomach, had no appetite, and now and then vomited. Thinking that this derangement of the system had some connection with the tumor, she applied for its removal. About four days before coming to the clinic, the tumor was painful and the integuments discolored. She was ordered to be leeched, and to take purgative medicine. The tumor being very hard and elastic, fluctuated slightly, and moved with the trachea on deglutition; a small puncture being made, a few drops of fluid, resembling black tea, escaped. On the 2d of June, Mary was brought before the class, and the cyst was removed by Professor Gross, by an incision in the median line of the neck. It was overlapped by the sterno-hyoid and thyroid muscles, and was pretty firmly connected to the deep cervical fascia and the isthmus of the thyroid gland. It was, however, readily enucleated by the handle of the scalpel. A large branch of the right inferior thyroid artery, which ramified over the surface of the tumor, was ligated; the blood oozed from many points, and a very small portion of the isthmus was included in a ligature. The wound was left open for about an hour, being kept constantly covered with compresses, wet with cold water. The dressings consisted of four silver sutures, adhesive strips, and a compress. The patient progressed favorably to a cure, the whole of the wound having united in three weeks.

Anatomical Characters of the Cyst.—The cyst was of a bluish color, of a globular shape, and about as large as a medium-sized egg. The opening in it made by the exploring needle two weeks before the operation, had not closed. It consisted of an outer connecting cellular coat, a middle fibro-cellular, which could be divided into several very fine layers, and an inner lining membrane, which was smooth and glistening like any of the serous membranes of the body. Its walls received quite an abundant supply of blood-vessels from the surrounding parts, and were thicker in some places than in others. In the lower portion of the cyst there was an opake fibro-albuminous deposit, about three-fourths of an inch in diameter; but, with this exception, it was either perfectly transparent or translucent.

Microscopical Appearances of the Lining Membrane.—This consisted of a structureless membrane, here and there fibrillated, and lined with large, pale, delicate polyhedral cells, having distinct and large oval nuclei, resembling tesselated epithelium. It was coated with altered blood-corpuscles, a large quantity of granules and crystals, for the most part

Digitized by Google

prismatic, but occasionally hexagonal or occurring in masses, resembling the so-called blood-crystals. As seen with the naked eye, there were adhering to it in parts, small portions of coagulated blood, and a few small pedunculated, amber-colored bodies, resembling somewhat in appearance a gelatiniform polypus, and consisting of the same altered blood-corpuscles and crystals. Here and there were cells entirely filled with granules. The lower portion of the cyst was thickened about one half a line, and contained, between the lining membrane and outer coat, a soft, dirty-yellowish substance, composed of imperfectly-formed cells, embodied in a fibro-albuminous matrix.

Physical, Chemical, and Microscopical Characters of the Fluid.—A drop of the greenish-black fluid, which escaped from the puncture, was found to contain shrivelled corpuscles with irregular cell-walls. They were in great abundance; and evidently old and altered, not a single globule being of the normal shape. Upon opening the cyst the fluid was found to be of a dirty brownish-red color, and to amount to six drachms. It had the odor and taste of blood, with a specific gravity of 1·027. It contained a great amount of albumen, as was shown by the action of heat, corrosive sublimate, and nitric acid. After standing fourteen hours, it separated into two parts, the serum constituting about nine-tenths, and the globules the rest of the amount. Upon subjecting a drop of the serum to the microscope, the same altered corpuscles appeared in abundance, as well as a few blood-crystals and cholesterine.

Remarks.—Cysts connected with the thyroid body are of rare occurrence when compared with other affections of this gland. During the last two years, I have seen not less than five cases of this affection, three having occurred at the clinic of the Jefferson College; but the one now communicated, is the only one which I have been able to examine minutely. About the same time that the above patient presented herself at the clinic, a German woman, twenty-one years of age, also consulted Prof. Gross for a tumor similar in physical appearances to that of Mary Neff. She attributed its origin to the effects of parturition, it having made its appearance two months after the birth of her first child. In the case of which I have now given an account, it will be seen that the patient had not been confined for three years, nor could she assign any cause whatever for its appearance. It is not at all probable that the tumor had any connection with labor.

In another case, the specimen of which I obtained last winter at Dr. Agnew's anatomical rooms, and which I send with this communication, it will be observed that the cyst is globular, and of nearly the same size as the one which was removed from the patient. When first seen by me, a puncture had been made into it, from which exuded a dark-colored fluid, containing what I supposed to be disintegrated blood. This cyst, also,

Digitized by Google

was connected to the isthmus of the gland at its inferior part, and throughout its whole extent intimately to the substance of the left lateral lobe. The supply of blood, in this case, came principally from the left superior thyroid artery, a large branch of which ramified over the posterior surface of the cyst. The thyroid plexus of veins was very much enlarged. The gland itself was hypertrophied, which was not the case in the other two subjects, and I have left the arteries supplying the gland, mutilated as they have been in the dissecting-room, in order to show the reciprocal influence of the enlargement of the one upon the other. In this specimen the cyst has become hardened from immersion in alcohol, which prevents an analysis of its contents. From its extensive connections with the gland, extirpation would have been a formidable procedure.

Much diversity of opinion exists in regard to the formation of these tumors; nor shall I weary the Society by presenting them, even with an epitome of the opinions of the principal authorities in pathology concerning this point. It is not always possible to say whether, in their production, the cyst is produced before its contents, and conversely, or, in other words, which was the cause, and which the effect.

In some such as the sebaceous and the true hydatid, we know there is a sac that secretes its contents, which, in their turn, are the cause of its distension; but we cannot with equal certainty trace the origin of some cysts lined by an adventitious serous membrane, which, in most cases, is supposed to be a new formation from a perversion of nutritive action. In regard to the present specimen, I am disposed to attribute its appearance to the formation of an adventitious serous membrane in one of the cells of the areolar tissue in the neighborhood of the isthmus of the thyroid gland. This cell, becoming distended, was finally closed by slight inflammation, and the secreting surface furnished the contained fluid which rapidly increased. The existence of blood in the fluid of the cyst may be attributed to an accidental hemorrhage into its interior during its growth; or, what is more probable, may it not have been a result of perversion of the nutritive functions of the part, in consequence of an accidental inflammation?

DR. DA COSTA presented the following paper on *Cancer of the Pancreas*.—At a former meeting of the Society I exhibited a specimen of primary cancer of the pancreas, and was requested to report more fully on the occurrence of this affection, and on the symptoms by which it is marked. In accordance with this wish, I beg leave to present this paper, accompanied by a table of thirty-seven cases, derived from various sources, and including two brought before the Society.

I have not endeavored to swell the number by instances adduced from the older writers; I have not included in the subjoined table the

Digitized by Google

three cases of Morgagni, the five cited by Bonetus, or the thirty-six observations on scirrhus of the pancreas, which Lieutaud has collected; nor have I referred to the oft-mentioned, but exceedingly unsatisfactory accounts given by Heberden; but I have attempted to bring together the cases of pancreatic disease which have been published by authors still living, or not long deceased, and such as seemed to have been undoubtedly cancer of the organ.

The great difficulty, indeed, in studying cancer of the pancreas is, that, while the older writers have most evidently confounded all chronic alterations of the pancreas under the title of scirrhus, many of the later physicians have taken the ground that cancer does not affect this gland, that all the observations, certainly those of primary cancer, are erroneous, and have brought about a skepticism with reference to the whole subject, which, in connection with the rarity with which the organ is carefully inspected in post-mortem examinations, has tended much to retard our knowledge of its morbid states. Yet there are (leaving out the descriptions of the older writers) a sufficient number of well-authenticated cases of disease of the pancreas on record, not only to prove that the gland is frequently the seat of cancer, but also that, in all probability, cancer is the most common of its chronic affections. These very cases, too, demonstrate that the malignant diseases of the organ are not always, as has been affirmed, secondary, but that cancer may commence in the pancreas and be confined to it, or else extend from it to surrounding textures. (*See cases recorded in the Table.*)

When the pancreas becomes cancerous the disease usually attacks its right extremity. The whole gland may be equally affected, or only the middle portion and the splenic end suffer (*Case* 31;) but this is not frequent. For the most part the cancerous change takes place mainly, if not solely, at the head, the other portions remaining healthy, becoming indurated, or undergoing a fatty degeneration. The disease shows a great tendency to spread to the adjacent lymphatic glands, and a cancer of the pancreas often in reality consists of the transformed head of the organ, so closely blended with these glands, as to have occasioned an apparently uniform tumor of considerable size, which, by pressure, produces obstruction of the ducts leading from the liver, or changes in structure in the surrounding tissues.

Scirrhus and encephaloid are both met with in the pancreas, and run the same course as in other organs. Colloid deposits, too, have been described as occurring. (Dr. Wilks; see Table, *Case* 32.) The natural structures disappear entirely, and the microscope exhibits nothing but abnormal cells, or else the cancer may be infiltrated through the regular gland-tissue.

The form and size of the pancreas are materially modified by the cancer-

Digitized by Google

ous disease, especially is the size. Enlargement almost invariably occurs, and the organ may exceed three or four times its natural bulk. Duponchel* relates the case of a soldier who died at Cadiz after a long and obscure disease of the abdomen, and in whom a large tumor, of the size of a child's head, consisting of a brownish matter resembling coagulated blood, and of a broken-down cerebral-like substance, was found occupying the place of the pancreas, of the glandular structure of which not a vestige remained. A mass of similar size occurred in the case of a woman described by Caspar.†

The pancreatic duct often becomes implicated in the disease. Sometimes it remains pervious, but at others it is entirely obliterated. It may be pervious in the diseased mass, or where it opens into the intestine, while at the more healthy portions of the gland it is obliterated. Again, the reverse takes place; it permits the pancreatic secretion to flow, until it reaches the diseased portion of the pancreas, but here and at its mouth it is closed. Cruvelhier‡ met with what appeared to be a cyst in the pancreas, but which, on closer examination, was proved to be the much-dilated pancreatic duct, the duodenal extremity of which was strongly compressed by a scirrhous degeneration of the head of the pancreas. A still more remarkable case happened a few years ago in the clinical wards of Professor Bamberger.§ The duct, by pressure at a part of its course, was dilated into a cyst, containing a yellowish-red fluid, of the size of a man's fist. True cysts, however, occur in cancer of the organ; their walls are thin and translucent; their contents may be a bloody serum, (*Case* 19,) or blood mixed with broken down tissue. (Duponchel, *loc. cit.*)

The effects of pancreatic cancer show themselves chiefly on the adjacent organs. Secondary cancers in the brain are not described, nor do the thoracic viscera become often affected. Albers mentions a case in which the lungs were filled with small, yellowish cancerous deposits; Bennett (Clinical Lectures) one, in which gelatinous-looking masses in the lung proved, when microscopically examined, to be cancer; and it is not improbable that the "pulmonary consumption" in Sewall's case (*Case* 3) was cancer of the lung, as it did not come on until a long time after the pancreatic disease was fully developed. The stomach, intestine, and liver, from their proximity to the pancreas, are the organs which suffer most. The *stomach* may be perfectly healthy, or it may be adherent to the pancreatic tumor and thickened, especially near the pyloric extremity. The thickening is due to a simple increase of the normal structure, or to a cancerous deposit in the coats of the organ. The pyloric

* Bulletin de la Societé Med. d'Emulat. Mars, 1824.

† Caspar's Wochenschrifft, No. 9; quoted in Canstatt's Jahresbericht, 1844.

‡ Essai sur l'Anat. Pathol., tome i., p. 286, 1816.

§ Vol. vi. Virchow's Path. and Therap., p. 667.

Digitized by Google

orifice may be narrowed, and so pressed upon by the tumor as to be nearly obliterated, (*Case* 2.) The mucous membrane of the stomach is found in a state of softening, or of thickening, but for the most part it is perfectly healthy. The viscus may be much distended, or contracted. Its inner surface has been observed to be covered with a dark slimy fluid, or to contain blood, or even as much as a gill of pus, derived (*Case* 22) from a perforation of its coats, through which the pancreatic mass communicated with the stomach. Such cases of perforation have been several times noticed. The perforation occurs at the seat at which the stomach adheres to the morbid mass; the rupture may be at one, or at several places. (Hasenöhl.)

The *duodenum* presents the same changes as are met with in the stomach. It may be adherent to the pancreas, thickened and contracted, or distended; its calibre may be nearly obliterated by pressure, (see *Case* 23,) its mucous membrane softened, and one or several ulcerations communicating with the pancreas exist in it. The other parts of the intestine generally remain healthy; yet they, too, have been noted to have been greatly contracted, to have been ulcerated, (*Case* 15,) to have contained (*Case* 23) small cancerous masses, or to have been nearly filled with blood. The colon has been observed to be much contracted, and its coats thickened and covered with small patches of lymph, (*Cases* 17 and 18.) There seems, indeed, to be a very great tendency to fibrinous deposits, and to an increase and thickening of the cellular textures of the body, as witnessed in the intestines, and also in a cirrhosed state of the liver.

The *liver* is very variously affected. It remains healthy, becomes the seat of cancerous deposits, or exhibits abnormal changes with reference to size, density, and color. One of the most frequent appearances is to find it enlarged, and of a peculiar greenish hue. Dr. Bright, in an oft-quoted case, describes it as resembling "dark greenstone porphyry." It may be softer than natural in consistency, but is frequently denser, owing, in some instances, to a thickening of its cellular tissue. Well-marked examples of cirrhosis (*Cases* 26 and 34) have also been observed. In common with all the other organs in the body, it is at times pale and devoid of blood, (*Cases* 7 and 29.) The biliary ducts may be normal, or have their calibre greatly increased. The hepatic duct, as well as the cystic and common duct, are at times in some parts nearly obliterated, while in others they are much dilated; or one duct is dilated and the other compressed. Again, both the hepatic and cystic duct may be expanded, and the common duct be barely pervious, (*Case* 9.) In a case described by King,* the hepatic and choledoch duct above the seat of their compression were

* Medico-Chirurg. Review, 1827, (See Table, *Case* 1.)

Digitized by Google

dilated to the size of the ileum of an infant. Todd* had a young girl under his care, in whom the hepatic and common duct were so distended as to form a distinct swelling in the epigastric region, which was tapped during life, and was found to contain several quarts of bile. The cystic duct alone may be closed; but the duct which most frequently suffers is the common duct. It is evident, however, that the exact spot of its occlusion, or the state above the seat of compression of it, or of the cystic and hepatic duct, will depend much upon the shape and size of the pancreatic tumor.

The gall-bladder, in cases of compression of any of the ducts connected with the biliary function, is enlarged and greatly distended. Its coats have been observed to be much thickened, and its mucous membrane slightly ulcerated, (*Case* 23.) Its contents are a dark, inky bile, or an inodorous, colorless fluid, (*Cases* 1 and 15,) which King (*loc. cit.*) tells us has no resemblance in chemical composition to bile.

The other structures situated in the abdomen do not often become affected in consequence of a pancreatic cancer. The omentum may be implicated in the disease; the spleen remains healthy. The supra-renal capsules were involved in a case described by Dr. Bright.† The diseased mass may press upon the nerves and narrow the aorta, as in a case quoted by Mondière from Portal.‡ In another instance, the latter author has observed an aneurism to have been produced by the pressure of a scirrhous tumor of the pancreas.

The *age* and *sex* of those suffering from cancer of the pancreas may be seen from the following table of thirty-seven cases:—

Age.	Males.	Females.
14 to 22	–	2
24 to 28	2	1
33 to 36	3	–
40 to 46	4	2
48 to 58	8	4
58 to 68	2	4
68 to 78	–	2
Not stated	3	–
	22	15

These figures certainly show that cancer of the pancreas conforms, in respect to age, to the general laws of cancerous disease. It will be perceived that the majority of cases occurred after the fortieth year. The youngest (*Case* 21) was a girl 14 years of age, the eldest a woman of 76.

* Dublin Hospital Reports, vol. i.

† Med-Chirurg. Transactions, vol. xviii., *Case* 7. It may not be without interest to state that in this case no bronzy color of the skin is mentioned.

‡ Traité de l'Apoplexie.

Digitized by Google

Rokitansky has mentioned an instance of the pancreas having been found scirrhous at birth. With reference to sex, the majority of cases are met with in men. Of the fifteen female cases, two occurred in colored women. Dr. Walshe's statements concerning sex do not agree with my deductions. He thinks the disease is more frequent in the female.*

The exact *duration* of the affection it is not possible to ascertain. Like all chronic diseases, its commencement cannot be accurately fixed. It would seem that, although it may last for several years, and occasion prolonged suffering, it may also run a more rapid course. It is, indeed, in not a few of the cases specially noted, that the patient had been, up to a certain time,—not a year before his death,—in excellent health. In several instances, no marked symptoms appeared until four or five months before death, and a case has been reported in which the disease seemingly commenced with acute symptoms, and ran on, in eleven weeks, to a fatal termination, (*Case* 36.) In one patient it was ushered in by jaundice, in another by a febrile attack, (*Case* 7.) In one case it is recorded that it followed a sudden disappearance of tumefaction of the parotid and submaxilliary glands, (*Case* 9,) in another, (*Case* 28,) that it was produced by continual pressure against the stomach. Death usually takes place from gradual exhaustion. But it may occur after hemorrhage, or by the development of cancer in other parts of the body, or with the symptoms of an adynamic fever, (*Case* 8.) The patient mentioned by Dr. Campbell (see *Case* 22) expired suddenly, after a sound like something bursting. The stomach had been perforated, and was found to contain a large quantity of pus.

The *symptoms* of cancer of the pancreas are not always the same; they are mostly produced by the effects of the disease on other organs. The affections of the pancreas themselves give rise to few, if any, special symptoms; to none which are constant.

Local Signs.—Amid the local signs, one of the most important is the existence of a swelling, or a tumor. In thirteen cases out of the thirty-seven recorded below, a tumor is specially noticed; in one, there was fulness at the epigastrium; and in one at the left hypochondrium; in one fullness at the epigastrium, with resistance to touch; in one, an indistinct hardness at the pit of the stomach, and in another, at the right side of the abdomen, making eighteen cases in which the pancreas had given rise to perceptible signs of its enlargement. The situation of the tumor is mostly noted as in the epigastric region, or between this and the umbilicus. It may extend into the right hypochondrium, or into the left, or (*Case* 22) into both. It may be fixed or movable, (*Case* 35,) with limits not definable, or capable of being accurately determined by the touch and by percussion. In some

* Walshe on Cancer, p. 321.

Digitized by Google

instances it is painful on pressure; in others not. In several very interesting cases it was accompanied by pulsation and a blowing sound, and might thus have been readily mistaken for an aneurism. In Dr. Battersby's patient (*Case* 17) there was an apparent systole and diastole; the pulsation ceased in two months, but the bruit and the tumor remained. In the patients of Sandwith, Fletcher, Tessier, and McClurg, (*Cases* 20, 24, 27, and 28,) the pulsation continued as a permanent phenomenon. Both pulsation and blowing sound may be accounted for by the tumor lying across, and compressing the abdominal aorta. In Dr. Battersby's case, however, the blowing sound may have been produced by the deposits which covered the inner coat of the abdominal aorta.

An epigastric tumor of a different nature may be caused by disease of the pancreas, and lead to singular errors of diagnosis. Petit* operated on a case of what he thought to be a strangulated hernia of the stomach or colon. The tumor was soft and compressible, and accompanied by vomiting and hiccough. The operation demonstrated that it was the stomach, pressed forward by an enlarged pancreas; whether cancerous or not, was not determined. In another case already cited, (See *Case* 21,) an epigastric tumor was not the cancerous pancreas itself, but a dilatation of the hepatic and choledoch duct produced by it.

Pain is a very constant symptom: it is mentioned in thirty-two out of thirty-seven cases. The seat of the pain is, in most instances, the epigastrium. In twenty of these thirty-two cases it seems to have been there most marked, although it was not always confined to this seat, but extended to the right side, or to the left, or to the back, or to the umbilicus and lower part of the abdomen. In one case it was an intermitting pain confined to the lower part of the abdomen. In two or three others it extended equally over the whole abdomen. In four cases it had its seat of greatest intensity in the back, but in one of these there was also deep-seated epigastric pain, a constant pain in the lower part of the abdomen, and pains extending to the arms. In another case they radiated to the left half of the chest, and to the abdomen. In three cases the pain was mainly felt in the sides, and extended into the back.

The character of the pain is very various. In the majority of the cases it is severe, in some excruciating, and in paroxysms of several days duration. It is, at times, much like colic; or again it is described by the patient as "a deathly distress," (*Case* 29,) or (*Case* 19) as a "hot sensation extending into the back." In some cases it is very slight, more of an undefined uneasiness (*Case* 9) than actual pain. In Andral's patient at La Pitié,† the pains were like blows of a hammer, or like the perforating

* Discours sur la Medecine du Cœur: Lyons, 1806.

† Lancette Française, No. 16.

Digitized by Google

dart of a dagger, and increased at night. The pancreatic tumor was found, on post-mortem examination, to have compressed the nervous plexus which spreads around the abdominal aorta. The pain is not, as a rule, increased by taking food, for this is only noted in very few of the cases, (see 18 and 29;) on the other hand, there are instances in which it is specially stated that it was not. The pain may become duller (*Case* 32) as the disease advances; it may or may not be increased on pressure. It may be suddenly augmented by turning in bed from side to side, (*Case* 14.) In not a few cases is it increased by the erect position, and hence we find patients seeking relief by stooping, and curving their body forward so as to relax the abdominal parietes, (see *Cases* 2, 3, 5, 13, 28.)

Vomiting is a symptom, the frequency and importance of which it is difficult to determine, for it is obvious that in those cases in which much disease of the liver or cancer of the stomach were superinduced, it cannot be established in how far the symptom may be placed in connection with the disease of the pancreas. In the thirty-seven cases below noted, vomiting is mentioned in twenty-one; but in two of these it was a transitory phenomenon, lasting a very short time, and occasioned in one, by eating indigestible food. In one case it came on after an attack of hepatitis, which happened seventeen years before any symptoms of pancreatic disease developed themselves; in three others, it occurred in patients in whom considerable disease of the liver and stomach was, after death, detected. Leaving out these six cases, we still find it in fifteen. In nearly all of them it was a late symptom, and in only a few constant. In one patient (*Case* 20) it did not appear until six weeks, and in another not until ten days before death, (*Case* 23,) although in him the pylorus was found greatly contracted. The narrowed state of the pylorus, caused by the pancreatic disease, or the pressure of the tumor on the stomach will explain the vomiting in several instances. In a case mentioned by Dr. Henry Lee,* at the Royal Medico-Chirurgical Society, in which vomiting was among the symptoms, the stomach was perforated by the head of the pancreas, which had produced ulceration by pressure. In another case, (22,) in which ulceration of the stomach occurred, nausea and vomiting became prominent symptoms as the pancreatic tumor increased. The vomited matter consists either of the food that is swallowed (in many cases there is neither nausea nor vomiting until shortly after food be taken) or else (*Case* 18) of a substance like bran and water, of a bilious fluid, (*Case* 9,) of fluid of a glairy character, or of a watery, colorless fluid, (*Cases* 29 and 37;) or, again, the ejection may contain blood, (*Cases* 9 and 16.) The watery fluid that is sometimes discharged may be very

* Lancet, 1842.

Digitized by Google

abundant. It is thought by some to be the pancreatic secretion itself, and not to be derived from the stomach at all; others regard it as an increased salivary flow. The vomited matter is stated in one case, (23,) in which the pylorus was greatly contracted, to have been like coffee-grounds. But the coffee-ground vomit, so often seen in cancer of the stomach, is evidently here but exceptionally met with. In the case kindly communicated to me by Dr. Harris, there was in the vomit a distinct blackish sediment; this was proved to be stove coal, of which the patient was in the habit of consuming daily about half a pint, eating it in the form of cinder.

The condition of the *bowels* is usually that of constipation. In thirty-four cases constipation is mentioned in nineteen; in four the bowels were regular; in three diarrhœa occurred as a late symptom; one patient passed blood and pus by stools; two others, at times blood; in the other cases diarrhœa existed, or alternated with constipation. The fæces are mostly hard, and vary in color according to the presence or absence of the biliary secretion. Hemorrhage into the bowels, which has been observed as occuring in several cases, will explain the black, bloody stools sometimes voided. Dr. Bright has directed attention to the presence of *fatty* stools in cases of pancreatic cancer which he has published (*loc. cit.;*) they were noticed in three cases. But he is far from having affirmed, as subsequent writers wish us to believe, that they are of constant occurrence. He himself speaks of cases of scirrhous pancreas without fatty discharge, and, although he thinks that it is connected with "disease probably malignant of that part of the pancreas which is near to the duodenum, and ulceration of the duodenum itself," he does not, by any means, lay this down as positive, since, at the end of his paper, he suggests that the symptom might be diagnostic "of the *nature* of the diseased action rather than of its seat." Many observers have since brought forward instances of fatty discharges in which no disease of the pancreas existed, and, on the other hand, to the cases of Bright, but few others have been added in which these discharges were associated with affections of this gland.* A desire to bring the physiological teachings of the present day in connection with morbid anatomy may have prompted many to accord so much importance to the occurrence of fatty stools in pancreatic disease. But pathological anatomy seems to contradict the assertion that the pancreatic secretion possesses alone the power to emulsify, and to render the fatty matters fit for absorption. It can certainly

* Dr. Eisemann, Viertel Jahreschrifft für die praktische, Heilk, 1853, (quoted in the Med. Examiner, 1855,) speaks of several cases of pancreatic disease, with abundant fatty discharge, but in the case which came under his own care there was none. In some of the instances quoted the oily evacuations had ceased, although the pancreas was so indurated as to have rendered the performance of its function impossible.

Digitized by Google

not be the only agent. The cases of Dr. Bright would lead rather to the conclusion that, for fat not to be acted upon, the duodenal secretions must also be vitiated, and the flow of healthy bile interfered with. For in all of them there were also ulcers in the intestine, and the ducts through which the bile flows were compressed or nearly obliterated.

Jaundice constitutes, in a large proportion of cases, one of the most prominent symptoms; it is persistent, and resists all treatment. In most instances it does not appear until the pancreas has enlarged considerably, in other words, not until late in the disease; but in a few cases it is noted among the early signs. It usually increases as the disease progresses, and the skin becomes of a deep-yellow, or of a greenish hue, (*Cases* 1 and 36.)

Dyspeptic symptoms are a class of symptoms which are found in pancreatic cancer, in a very varying degree. From the vague manner in which the term is made to embrace different states, it is difficult to ascertain the exact nature of these symptoms in the reported cases. They are noted in twenty-five out of thirty-seven cases, some as of early, some as of late occurrence; but of these twenty-five cases there are several in which the signs of indigestion had been evidently present at a time long anterior to the other symptoms of the disease, and probably to the disease itself. *Acid eructations* were troublesome in five cases; in two cases there was much pain after eating; in five cases there was considerable flatulency, incontrollable in one, but not dependent upon taking food, (*Case* 30.) A feeling of weight and oppression at the stomach are noted in three cases; of sinking, relieved by food, in one; of great irritability of the stomach in two. Constant *thirst* is mentioned in six cases, but in one of these diabetes existed.

The *appetite* fluctuates in every conceivable way; it frequently remains good even to the last; it is sometimes capricious, although the patient (*Case* 7) can take a great deal of food; anorexia is noted in seven out of the twenty-five cases in which dyspeptic symptoms are mentioned. *Hiccough* was in two cases (28 and 34) an exceedingly annoying incident. The *tongue* is not often alluded to; from which it may be inferred that it does not often present any peculiarity. It is stated in four cases to have been dry; in two, it was covered with a yellowish coat; in one, with a brown fur; it remained clean throughout in one, and its cleanness and great moisture are especially commented on in two interesting cases (17 and 18.) The *ptyalism*, which sometimes takes place, will give rise to this macerated appearance of the tongue; but, although it may be both very abundant and exceedingly offensive,* the occurrence of this salivary discharge is not frequent, and its importance in diagnosis, therefore, less than some authors state it be.

---

* Mondière. Archives Générales de Medecine, 1836.

Digitized by Google

Dropsy is met with in the advanced stages of pancreatic cancer. It was present in sixteen out of thirty-seven cases; yet, although many of these were complicated with hepatic derangement, in none was it very marked; in most, ascites was present; in some, ascites and anasarca; in one case, marked anasarca of the upper and lower extremities, (*Case* 17,) and only slight ascites; and in another, (27,) œdema of the feet was seen disappearing and reappearing.

Emaciation and *debility* are both very striking and constant symptoms. The emaciation is great and progressive. In a case, reported by Sandwith, the patient was so emaciated that the spine could be distinctly traced through the abdominal parietes. Debility usually goes hand in hand with the perceptible loss of flesh, but it may not be as extreme; and, again, it is sometimes prominent among the earlier symptoms. In exceptional cases the loss of flesh is slight, and debility not marked. The *countenance* is usually pallid, and has a distressed look; the features become pinched, and the face is expressive of suffering and anxiety. The skin is sallow, of a bloodless hue, or jaundiced, or more rarely it is straw-colored, (*Case* 28.) The *pulse* is not often noted, when it is, it is stated to have been quicker than in health. A tendency to hemorrhage must also be alluded to; blood was lost from the stomach, bowels, and lungs, in several cases.

The main symptoms, then, of pancreatic cancer, are a tumor in the epigastric region, pain there, or in the back, constipation, progressive emaciation and debility, and obstinate jaundice and occasional vomiting, as the disease advances. The diagnosis is possible, if these symptoms be present, and provided we are able to exclude with certainty the diseases of the stomach and of the liver. I shall not attempt to decide in how far the symptoms may be shared by other chronic affections of the pancreas. Tubercle of that organ is rare, and is associated with tubercle of the lung or of the brain.* Chronic pancreatitis gives rise to many of the same phenomena; but, taking the cases which I have met with in pursuing this inquiry as my standard, I should say that those signs which indicate a tumor, and the symptoms which show its marked growth and pressure upon other organs, are not often present; that pain does not occur to such a marked degree; that the falling off in health is very gradual, and the disease slower of progress, and also that the bowels are not as constipated, but are, on the contrary, more frequently relaxed. It is, however, fair to state, that Dr. Claessen, in a work on Diseases of the Pancreas, (Cologne, 1842,) remarks that constipation in chronic pancreatitis is urgent and enduring.

---

* Würtemberg. Med. Correspond. Blatt.

Digitized by Google

Case.	By whom and where reported.	Age and Sex.	Duration.	Local Signs.	Pain.	Vomiting.	State of Bowels.	Jaundice.	Emaciation and Debility.	Dropsy.	Dyspeptic Symptoms.	Other Symptoms, and Remarks.	Post-mortem Appearances.
1	King. Medico-Chirurg. Review, 1827; from a case under the care of Dupuytren.	45; male.	Not mentioned; but upwards of four months.	Not mentioned.	Not mentioned.	Not mentioned.	Not mentioned, except that during the day before death, stools of black and bloody appearance passed involuntarily.	Very great (skin of a greenish-yellow color) occurred upwards of four months before death.	Emaciation moderate; debility not mentioned; (excepting as noticed after an operation for cataract; then, also, tendency to syncope, in the perpendicular position.)	None.	Not mentioned.	Cataract of some years' standing.	Pancreas was large; a portion of it forming, with a cluster of scirrhous glands, a tumor, by which the common duct was much compressed, but its mouth remained pervious. The pancreatic duct was free; so was the cystic duct. The hepatic and choledoch duct, above the seat of their compression, were distended to the size of the ileum of an infant, and filled with gas. The gall-bladder, besides gas, contained an inodorous, colorless fluid, which had no resemblance, in chemical composition, to bile. Liver was large and green. Large intestines contained coagulated blood.
2	Sewall. Med. and Physical Journal, vol. xxxi. p. 96.	27; male.	About one year.	Tumor in epigastrium.	Severe, deep-seated, epigastric pain, increased by the eréct position; hence patient always in a curved position of the body.	Almost constant.	Constipated.	Not mentioned.	Both great.	Very slight ascites; (post-mortem.)	Acid eructations; great irritability of stomach.	Disease preceded by tumefaction of parotid and submaxillary glands, which suddenly subsided.	Pancreas was nearly three times its natural size; hard throughout, irregular, and unyielding. Its right extremity pressed firmly on the duodenum, and on the small extremity of stomach, thereby nearly obliterating the pyloric orifice. Other organs healthy.
3	Sewall. *Ib.*	"A young man."	A few years.	Not mentioned.	Deep-seated, epigastric pain, increased by the erect position; hence always a curved position.	Present.	Not mentioned.	Not mentioned.	Great emaciation; debility not noted.	Slight ascites; no œdema.	Great acidity; no food except milk could be retained on stomach, yet appetite remained good.	A pulmonary consumption came on two months before death.	Pancreas—only one of the abdominal viscera, which was diseased, was enlarged, and scirrhous, particularly its right extremity, which embraced the duodenum, and pressed so firmly on the pylorus that its orifice would scarcely admit of the introduction of a common-sized catheter. Stomach and intestines were greatly contracted. Liver healthy. Lungs hard and unyielding, and in many places ulcerated, and affected with tubercle.

Digitized by Google

4	Martland. Edinb. Med. and Surg. Journal, 1825.	60; female.	Six months.	Hard tumor, about the size of the palm of the hand, at scrobiculus cordis and right side, below the margin of the ribs; very painful on pressure, and enlarging toward the end of the complaint.	In and about the region of the tumor.	Not mentioned.	Regular; stools very white.	Most intense; came on a few weeks after first manifestations of the disease.	Great and progressive debility, and extreme emaciation.	Not mentioned.	Anorexia; great thirst; furred and dry tongue.	Pulse between 80 and 100.	Pancreas. The head formed a scirrhous tumor about the size of a hen's egg. In this tumor was lodged the ductus communis, which was almost impervious, and was still more obstructed by a small calculus. The cystic and hepatic ducts were considerably dilated. Gall-bladder much enlarged. Liver studded with small, distinct tubera, which were confluent opposite the gall-bladder.
5	Abernethy. In a lecture delivered at St. Bartholomew's Hospital. Lancet, April 21st, 1827.	"A man of advanced age."	Not mentioned.	None.	Pain in the epigastric region, gradually extending, and increased by pressure, by erect posture; hence patient constantly stooping forward. He had also to be propped up in bed, to lessen pressure.	Not mentioned.	Constipated.	None; (countenance had a distressed appearance, even from commencement, but was never jaundiced.)	Increasing debility.	Not mentioned.	Pain after eating.		Pancreas in a state of complete disorganization and ulceration from end to end. State of other organs not mentioned.
6	Abercrombie. "Diseases of the Stomach," p. 412. Am. ed.	56; male.	Two years.	Not mentioned.	Pain in the left hypochondrium, extending into back.	None.	Regular.	Occurred only a few weeks before death.	Both present; died gradually exhausted.	Not mentioned.	Symptoms of indigestion present.		Pancreas, in parts, hard; in others soft, and composed of yellowish and white matter. Mass attached to spine. Liver enlarged and soft. Other organs healthy.
7	Abercrombie. *Ib.*	35; male.	Eighteen months.	Not mentioned.	Undefined uneasiness in epigastric region.	As a late and transitory symptom.	Sometimes constipation, at others diarrhœa.	None; (countenance remarkably pale.)	Both present to a marked degree, and progressive.	Not mentioned.	Present; appetite capricious; took a good deal of food.	Strong action of heart; throbbing in head; disease commenced with a febrile attack; frequent perspirations at night.	Pancreas considerably enlarged, and of nearly cartilaginous hardness, except some spots, which were soft, with the appearance of medullary sarcoma. Pylorus thicker than normal, and adherent to pancreas. Other organs healthy, but very devoid of blood.

Digitized by Google

Case	By whom and where reported.	Age and Sex.	Duration.	Local Signs.	Pain.	Vomiting.	State of Bowels.	Jaundice.	Emaciation and Debility.	Dropsy.	Dyspeptic Symptoms.	Other Symptoms, and Remarks.	Post-mortem Appearances.
8	Andral. Archives Générales de Medicine, 1831; or *Lancette franc.*, T. Y. No. 216.	54; female.	Four months; previous health good.	Fullness in left hypochondrium, but no tumor perceptible.	Intense pains in dorsal region, extending to the left half of the chest, or through abdominal region; more frequent at night, lasting from several hours to several days at the time.	Not mentioned.	Diarrhœa as a very late symptom.	None.	Not mentioned; (face pale, expressive of suffering.)	None.	Extreme disgust for taking food; tongue had a yellowish coat.	Insomnia; febrile signs; patient died with all the symptoms of an adynamic fever.	Pancreas enormously enlarged, and transformed into a tumor, which seemed a combination of scirrhus, encephaloid, and tubercle. (?) This mass compressed the aorta, and the plexus of nerves which surrounds it. Other organs healthy. A sanguineous effusion into the pericardium.
9	Becourt. Quoted by Andral, Pathol. Interne. Tome ii. p. 283.	45; male.	Four months.	Pain on pressure at a small point between umbilicus and curvature of stomach; heat over stomach.	Above umbilicus; abdominal cramps; at times violent pains over stomach, extending over whole abdomen.	Nausea; also vomiting, in last two months, bilious, sometimes sanguinolent ejections.	Costive; hard stools, at times white.	Occurred early, and became intense; slight jaundice, with feeling of oppression at the epigastrium, were indeed the first symptoms.	Great debility; also emaciation.	Slight ascites.	Great thirst; appetite good; cardialgia flatulency.	At times passive hemorrhage.	Pancreas—head scirrhous, rest converted into fat; liver of an olive-color, and containing a few cancerous spots. Gall-bladder distended, containing very dark bile; hepatic and cystic ducts enlarged; common duct very much compressed, and barely pervious. Stomach healthy.
10	Percival. (Transact. of College of Physic., Ireland,) Vol. ii. p. 132.	"Middle aged man."	Three months.	Epigastrium distended; tumor felt protruding from middle.	Not mentioned.	Bilious vomiting.	Blood and pus passed by stools.	Present.	Emaciation and much debility.	Anasarca toward the end.		"Disordered secret. of urine."	Liver "much diseased." Pancreas scirrhous, contained a considerable abscess. Ductus com. choled. closed, in the parts adjacent to the pancreas. Gall-bladder full; cystic duct pervious.

Digitized by Google

11	Dr. Bright's Cases. Vol. xviii. Med.-Chir. Transact., 1833. Case I.	49; male.	One year.	None.	Pain in loins.	Not mentioned.	Stools copious and light-colored; for the last two months fæces contained a yellowish, fatty matter, and bowels were much relaxed.	Present; commenced six months after first symptoms of disease.	Great debility, and emaciation, continually increasing.	Slight ascites; legs very slightly œdematous.	Great thirst and appetite.	Marked enlargement of liver; frequent urination; diabetes; acute pleurisy two weeks before death.	Pancreas hard and cartilaginous to the touch; of a bright-yellow color; its head formed, with the surrounding glands, a hard, globular mass; at junction of pancreas with duodenum ulcers had taken place. Liver resembled dark greenstone porphyry, and contained hard, circumscribed masses; its ducts were enlarged; common duct dilated, but terminated by a *cul-de-sac* in diseased part of pancreas. Signs of jaundice pervaded many structures; serum olive-colored; coating of fibrine on pleura.
12	Dr. Bright. Case II. *Ib.*	50; female.	Not ascertained; certainly not less than seven or eight months, perhaps some years.	None.	No pain on pressure; some pain at lower part of abdomen, relieved by pressure, and occurring only at intervals.	Retching and vomiting for seventeen years; increased much within the seven months before death.	Rather costive; evacuations whitish; a few dark motions like pitch; a week before death large coagula of blood; while under observation for three months, fatty matter noticed in her dejections.	Very great; gradually increasing; did not occur as a permanent symptom until four or five months before death.	Progressive and great debility; general emaciation, cheeks much sunken, but some fat on abdomen.	None.	Not very marked.	Good health until seven or eight months before death. Seventeen years ago severe hepatitis; she became very drowsy during the last days of her life.	Pancreas hard and cartilaginous; its head enlarged and glued to duodenum, and communicating through an ulcerated spot with this. Common gall-duct pervious, but evidently had been compressed; biliary ducts distended. Liver cancerous. Lungs healthy, but firmly bound down posteriorly by strong, adhesive bands.

Digitized by Google

Case	By whom and where reported.	Age and Sex.	Duration.	Local Signs.	Pain.	Vomiting.	State of Bowels.	Jaundice.	Emaciation and Debility.	Dropsy.	Dyspeptic Symptoms.	Other Symptoms, and Remarks.	Post-mortem Appearances.
13	Dr. Bright. *Ib.* Case III.	21; female.	Decided illness for two months.	Indistinct hardness on right side of abdomen.	No pain mentioned.	Not mentioned.	Rather bound, but subsequently evacuations were copious, fatty, and thin.	Slight; increased towards close of life.	Emaciation not great, but great debility; restlessness.	Anasarca; also some ascites.	Not mentioned.	Out of health for two years; slight cough; preferred lying in a raised position.	Pancreas—hard mass near its head; another near the spleen; intervening portion seemed more healthy; masses of yellow color. Ulcers in the intestine; some ulcers communicating with glands in the meso-colon; mesenteric glands and supra-renal capsules diseased; also, bronchial glands; slight deposit of round size at apex of lung. Liver enlarged, of a dark-olive color; hepatic and cystic duct enlarged, but common duct becoming much constricted before entering duodenum.
14	Dr. Bright. *Ib.* Case VI.	76; female.	Thirteen months; good health before attack.	None.	Severe pain in the sides, extending to the back; pain also immediately under right mamma; acute pain in turning from left to right side; pain in the side became very fixed.	Vomiting not mentioned; nausea as a late symptom.	Constipated at the latter portion of the disease; clay-colored stools.	Jaundice only latterly present.	Great and increasing lassitude and debility.	Among the late symptoms anasarca; also some ascites.	Weight and distension of stomach.	Palpitation of the heart.	Pancreas large and in a scirrhous condition, involving the ductus choledochus in the diseased structure. The common duct was dilated up to its termination, where it was found completely obliterated; near the duodenum it formed a complete *cul-de-sac*. Liver small, but gorged with bile. Gall-bladder enormously distended. Duodenum thickened, and somewhat contracted.

Digitized by Google

15	Dr. Bright. *Ib.* Case VII.	35; male.	Thirteen months.	Tumor above umbilicus, reaching not quite to pit of stomach.	Not mentioned.	Not mentioned.	Constipated; stools became, subsequently, clay-colored and yeast-like; a few days before death very dark.	As a late symptom.	Both present to a marked degree; at first greater debility than emaciation.	Not present.	Not mentioned.	A tumor below umbilicus.	Pancreas—malignant disease towards its middle; its splenic and hepatic heads not infiltrated; its duct pervious. Its middle portion was involved and continuous with a large, movable mass, connected with the lower tumor seen during life. This tumor consisted of masses, which surrounded the aorta and iliacs, and, passing up the spine, involved the pancreas and renal capsules. Upper tumor was a movable mass in the omentum. A few scirrhous tubera in liver. Gall-bladder distended. Orifice of cystic duct very nearly closed; hepatic duct and common duct both somewhat contracted; colorless fluid in gall-bladder and cystic duct. Small, malignant tumor attached to surface of the heart. Pancreatic duct seemed obstructed in healthy part of pancreas; in other parts pervious.
16	Dr. Bright. *Ib.* Case VIII.	43; male.	Ten months.	Indistinct hardness at pit of stomach.	At pit of stomach.	Towards end of life; severe vomiting of a dark-colored fluid shortly before death.	Relaxed at first; clay-colored stools, then varying in color.	Jaundice appearing suddenly and early; became persistent.	Both markedly present; debility as an early symptom.	Not present.	Flatulency.	Appetite unusually great; itching over body; frequent drowsiness; tendency to hemorrhage.	Pancreas not enlarged, but its head formed a large yellow mass, with neighboring absorbent gland; pancreatic duct greatly enlarged. Liver full of yellow spots, of varying size; liver enlarged; all the ducts involved in cancerous masses; hepatic duct enlarged, and filled with colorless fluid. Stomach full of dark, grumous fluid. Serum in chest of dark-yellow color. Ulcer in duodenum.

10

Digitized by Google

Case	By whom and where reported.	Age and Sex.	Duration.	Local Signs.	Pain.	Vomiting.	State of Bowels.	Jaundice.	Emaciation and Debility.	Dropsy.	Dyspeptic Symptoms.	Other Symptoms, and Remarks.	Post-mortem Appearances.
17	Dr. Battersby. Dublin Medical Journal, Vol. xxv. 1844. Case I.	About 58; female.	Sick twenty-five months; disease marked for thirteen months.	Deep-seated pulsating tumor in epigastrium, having a well-marked *bruit de soufflet*; the pulsation ceased in two months, but the bruit and the tumor remained; fullness in epigastrium.	Severe pains in back, extending to arms; then uneasiness and deep-seated pain in the epigastrium, increased by pressure; also, constant pain in the lower part of abdomen.	None.	Very sluggish; passages attended with violent straining and intense distress; feces generally watery, deficient in bile.	Present, but not to a great degree.	Both present; emaciation extreme.	Slight ascites; very marked anasarca of upper and lower extremities, which increased much at later portion of disease.	Eructations; appetite nearly gone, but this not until last month of disease; no thirst; tongue pale and clean.	Ptyalism; mouth always full of saliva; dysphagia.	Pancreas enlarged and hard throughout; every trace of its natural structure had disappeared. At its lower edge existed a thin cyst, about the size of a walnut. Duodenum extremely contracted, and adherent to pancreas; pancreatic duct was pervious for about an inch only from the duodenum. Liver small, of a dark-gray color, and dense; owing, apparently, to a thickening of its cellular tissue. The common duct and hepatic duct were not interrupted; colon and cardiac orifice of stomach much contracted; cellular tissue increased and hard. Mesenteric vessels and nerves involved in the scirrhous mass; gastro-hepatic omentum dense, hard, and thickened; aorta diseased by deposits in its entire course through the abdomen.
18	Dr. Battersby. *Ib.* Case II.	24; male.	Four years.	None.	Severe pain in stomach, coming on generally after meals; subsided after vomiting; sometimes appearing in the middle of the night.	Present; sometimes of dark fluid, sometimes like bran and water.	Severe constipation; diarrhœa at end of life.	Not mentioned; (skin sallow.)	Emaciation; features pinched; debility not mentioned.	Ascites and anasarca, both as late symptoms.		Cleanness and great moisture of tongue.	Pancreas dense and cartilaginous; confounded somewhat with surrounding structures. Liver healthy. Stomach and intestines distended. The sub-mucous coat of ileum and colon thickened; also covered with small patches of closely-adhering lymph.

Digitized by Google

19	Crompton. Birmingham Path. Society; in Prov. Med. Journal, Dec. 1842.	60; male.	Upwards of two years.	None.	Constant pain below the ensiform cartilage; sometimes "a hot sensation," sometimes pain extending into the back.	None, until last month, then only for two days, after eating indigestible food.	Tolerably regular; at times somewhat relaxed; dejections of good color.	Slight and not permanent.	Extreme and progressive emaciation; (a peculiar pallid appearance of countenance noted.)	None.	Appetite irregular; suffered more after a full meal; mouth generally clammy; tongue constantly covered with a brown fur at the base, and down the centre.	Pulse somewhat quick; skin dry and harsh.	Pancreas hard as cartilage; its left side distended by a large cyst, containing a bloody fluid. Many of the mesenteric glands enlarged and hardened. Liver small; scirrhous tubercles scattered through its substance; cystic duct obliterated by a deposit. A few calcareous deposits in lungs. Other organs healthy.
20	Sandwith. Ed. Med. and Surg. Journ. Vol. xvi. p. 880.	67; female.	Not mentioned.	Pulsation, left side, below cartilage of false ribs.	Continual pain in epigastrium, extending to hypochondrium; at times most intense; increased on pressure.	Not until six weeks before death, then very constant and distressing; everything she swallowed was rejected.	Costive.	None. (Complexion sallow.)	Both; eyes had a peculiar expression of anxiety; emaciation was extreme; spine could be traced through abdominal parietes.	Not mentioned.	Loss of appetite.	Great agitation, tore the bedclothes, etc.	Pancreas presented usual signs of scirrhus. Stomach erythematous. Splenic artery imbedded in scirrhous matter.
21	Todd. Dublin Hospital Reports. Vol. i.	14; female.	Some months.	Tense swelling in epigastric region, extending to right hypochondrium; it was tapped, and a greenish fluid escaped.	In epigastrium; increased on pressure; at times severe and very acute.	Not mentioned.	Not mentioned.	Deep orange-colored skin.	Great debility and emaciation.	Ascites and anasarca.	Present.	Spasms and convulsions; had had, for a long time, pains in the abdomen; development of disease followed; a fever, with relapses.	Pancreas; head and glands around it converted into a hard, solid mass; its duct obliterated. Stomach somewhat thickened. Liver healthy; cystic duct dilated, but at its juncture with hepatic it was impervious; remaining portion natural.

Digitized by Google

Case	By whom and where reported.	Age and Sex.	Duration.	Local Signs.	Pain.	Vomiting.	State of Bowels.	Jaundice.	Emaciation and Debility.	Dropsy.	Dyspeptic Symptoms.	Other Symptoms, and Remarks.	Post-mortem Appearances.
22	Henry F. Campbell. South. Med. and Surgical Journal. Vol. v. 1849.	72; female.	Not mentioned.	Tumor like large orange in epigastrium, extending into both hypochondriac regions.	Pain in epigastrium; two months previous to death became very distressing.	Nausea and vomiting as tumor increased.	Not mentioned.	Not mentioned.	Both to a high degree.	None.	Present.	Expired suddenly, after sound like something bursting.	Pancreas much enlarged; altered in structure, excepting at left extremity; tumor at the right extremity, with pus on surface, and ruptured entrance, which communicated with a cavity in its interior, and with a rupture in the rear of the stomach. This viscus, containing a gill of pus, was softened towards pyloric extremity. At the greater extremity thickening of its coats. Duodenum, near pancreas, was softened. Liver small, and very dense, of darker hue. Gall-bladder much distended; cystic duct distended; duct com. choled. occluded by tumefaction and induration of duodenum. Wursungian duct only seen at left extremity, and here its calibre obliterated.
23	Dr. Greene. Dublin Journal of Medical Science. Vol. xxv. 1844.	Male; age not stated.	Nine months.	None, save fullness in epigastrium.	Pain in epigastric region, and over umbilicus, sometimes like colic.	None, except ten days before death, then coffee-ground matter.	Constipated.	Jaundice intense.	Not mentioned.	None.	Anorexia; thirst; acid eructations; signs of indigestion were the earliest symptoms.	A week before his death delirium; died in that state.	Pancreas.—Its head was bound down, with the ascending and descending colon, into a cancerous mass, with which the duodenum was also connected; cystic and hepatic duct obstructed by the malignant growth. Mucous coat of gall-bladder ulcerated in several spots. Cancerous masses in several parts of the small intestines. Stomach dilated; pylorus hard, thick, and firm, and its calibre greatly contracted.

Digitized by Google

24	Dr. Fletcher. Birmingham Path. Society: Jan. 20th, 1844. Prov. Med. Journal.	52; female.	Not mentioned; (under treatment for two months.)	Hardness and increased space of dullness, extending from the right hypochondrium into the epigastrium; pulsations felt there and in the left hypogastric region; and a distinct *bruit de soufflet* attended each impulse when the patient was in the recumbent position.	Intense, excruciating pain in region of stomach; increased on pressure; pain extended to right hypochondrium, and down to the umbilicus.	Vomiting generally in about half an hour after taking food; constant nausea.	Costive; scanty evacuations twice or three times daily in an advanced stage of the disease.	Not mentioned.	Extreme emaciation.	Ascites; bowels above very tympanitic.	Irritable stomach; great thirst; tongue dry and red.	The whole surface of abdomen was tender; pulse small and feeble, 120 per minute.	Pancreas.—Entire organ carcinomatous; its head very much enlarged, wrapping around the duodenum, and inclosing that intestine in its diseased structure, so as to produce a stricture just below the pylorus. Liver studded with carcinomatous tubercles; other organs were healthy.
25	Albers. Rheim. Corresp. Blatt, 1843; or, Canstatt's Jahresbericht, 1849. Vol. ii.	50; male.	Upwards of one year; (previously in good health.)	Fullness of epigastric region; a tumor with an irregular surface felt there, and in the right hypochondriac region; and a pear-shaped, movable body between twelfth rib and the anterior superior spinous process of the ileum.	Above umbilicus, and extending to right hypochondrium; subsequently pain in the left side, extending to ensiform cartilage, and to umbilicus; also, dorsal pain; pain not constant; also, pain over spinous processes of all lumbar vertebræ; at least on pressure; (these vertebræ were very prominent.	As a late symptom; matter vomited; yellowish-green, then dark matter.	Soft, white stools; very late in the disease black stools.	Present, and increased; occurred as an early symptom.	Present.	Not mentioned.	Eructations of a bitter fluid; also, clear, yellowish, green, and acid fluid expectorated; appetite good; very fetid breath.	Dullness on percussion on left side of chest; disposition to lie on the back; salivation for three months, after taking ℈ij. of calomel; urine dark color, containing cholesterine; passed with some difficulty.	Pancreas.—Its head hard and degenerated, forming a yellowish tumor, which, microscopically examined, showed irregular cells, with several nuclei. Similar cells are seen in the small, yellowish deposits in the left lung, and in the liver; pancreatic duct pervious, and could be traced to the middle of the gland. Gall-bladder much dilated. The entrance of the common duct could not be found. Pancreas adherent to duodenum, and at seat of adhesion an ulcer in the latter.

Digitized by Google

Case	By whom and where reported.	Age and Sex.	Duration.	Local Signs.	Pain.	Vomiting.	State of Bowels.	Jaundice.	Emaciation and Debility.	Dropsy.	Dyspeptic Symptoms.	Other Symptoms and Remarks.	Post-mortem Appearances.
26	Caspar. Caspar's Wochenschrifft, No. 9; quoted in Canstatt's Bericht, 1844; 3.	40; female.	Not mentioned.	Tumor could be felt, whose edge extended along median line to umbilicus.	Not mentioned.	Present mainly after taking food.	At times stools containing dark blood	Present.	Present.	Ascites as disease advanced.	None.	Vomiting commenced after delivery.	Pancreas, the size of a child's head, and in a state of scirrhous degeneration; cirrhosis of the liver; gall-bladder much distended.
27	Tessier, Journal de Medic. de Lyon, Nov., 1847.	33; male.	Not mentioned; (appeared, when first seen, in tolerably good health.)	Hard, pulsating tumor extending from ensiform cartilage to umbilicus; abdomen prominent. In the last stages abdomen constantly rising, and simultaneously so with pulse, each movement accompanied by a sound audible some distance from patient, (glou-glou.)	Present; when the œdema appeared there was violent pain extending to the feet.	Not mentioned.	Constipation.	Doubtful; pale-yellowish complexion.	Not mentioned; but great debility is noted as perceived suddenly two days before death.	Œdema of feet, disappearing and reappearing.	Not mentioned.	Pulse became small; face altered; extremeties cold two days before death.	Pancreas.—Whole of the organ converted into a cancerous mass, which compressed the aorta; a few mesenteric glands around the tumor cancerous. In the pancreas a few softened spots. Other organs were healthy, except the stomach, which was much dilated and filled with fluids. (This supposed to be the cause of the gurgling "glou-glou" sound.)

Digitized by Google

28	J. R. McClurg. Medical Examiner, Phil., 1861.	50; male.	Eight months.	Fullness in epigastric region, and to the touch the feel of a thickened condition; decided pulsation in the epigastric region; great tenderness there on pressure.	Pain commenced early, and was constant and very intense; sometimes most in the region of the stomach, then in the left side, or in the back; no pain in the right side, excepting a month or two before death.	None.	Costive.	None; (skin dry, of a straw color; countenance had a wild, anxious look.)	Progressive debility and emaciation.	Ascites and anasarca four weeks before death.	Anorexia; feeling of oppression at epigastrium; tongue covered with a thick, yellow coat.	Great restlessness; patient unable to lie in bed; also inability to stand erect; bent forward so as to relax abdominal muscles; at one time fever; pulse, 90. In the last month of the disease hiccough became an almost constant symptom. The patient thought his disease had been produced by having carried, two years previous to his last sickness, a load of coal in a tub, which pressed hard against the stomach, giving him pain at the time, and ever after some uneasiness or a tired feeling at the epigastrium.	Pancreas.—The whole of the organ was converted into a cancerous mass, which also embraced the smaller curvature of the stomach, surrounded the solar plexus, the aorta, and accompanying vessels, and adhered to the diaphragm, the liver, the arch of the colon, and omentum. Liver was enlarged, hard, and "tuberculated;" gall-bladder healthy.

Digitized by Google

Case	By whom and where reported.	Age and Sex.	Duration.	Local Signs.	Pain.	Vomiting.	State of Bowels.	Jaundice.	Emaciation and Debility.	Dropsy.	Dyspeptic Symptoms.	Other Symptoms, and Remarks.	Post-mortem Appearances.
29	Dr. Kneeland. New York Journal of Medicine. Vol. xi. 1853.	64; male.	About eighteen months.	Hard tumefaction in epigastric region; not tender on pressure.	"Constant deathly distress," confined principally to epigastric region; increased by nourishment; suffering, indeed, much greater when he did not reject whatever he swallowed.	Present, and as an early symptom; matter vomited colorless; of a saltish taste.	Constipated.	No jaundice.	Extreme emaciation; (skin of a dingy, pale, bloodless hue.)	Not mentioned.	Continual vomiting of food; occasional vomiting and sinking sensation about the stomach were very early symptoms.		Pancreas enlarged and hard; adherent to stomach; converted, with the portion where it was adherent, into one mass of scirrhus, of a uniformly dull or yellowish-white color, and of a homogeneous structure. Liver, spleen, and kidneys anæmic in appearance. The mucous membrane of the stomach had retained its normal structure; the viscus was much contracted.
30	John S. Antrum. Association Med. Journal, 1855.	52; female.	"Several years."	Indistinct fullness in epigastric region, in the later stages; also, indistinct dullness on percussion; at one time a circumscribed spot, an inch square, below the edge of the liver, tender on deep pressure, was noticed.	Continuous epigastric pain, as a very early symptom; at first relieved by change of air and tonics; later more severe, and extending to the right groin, and to the back.	Present, but rarely, and only as the disease advanced, and then appeared to arise from distension by wind; never a black appearance of vomit.	Rather irregular and irritable; stools natural, except when deficient in bile; nothing like fat passed, not even when cod-liver oil was taken.	Never marked; skin gradually became slightly yellow and muddy.	Increasing debility and emaciation; had had attacks of debility for several years.	Not mentioned.	None. Food readily digested; uncontrollable flatulence, but not dependent on taking food; pain in the earlier stages relieved by taking food; seemed more a sensation of exhaustion.	Abdomen became, in the last stages, tympanitic; right thigh became swollen, and femoral vein tender in several parts of its course. Death took place from inanition.	Pancreas.—Its head enlarged to the size of a goose egg, by a cancerous deposit in its tissue. Similar deposits in the smaller end, and in neighboring lymphatic glands. Pancreas not adherent. Pyloric end of stomach, near pancreas, thickened by a deposit of cancer, apparently colloid; deposit ceased abruptly at the pylorus; dark, black, slimy mucus, as is often ejected in cases of cancer of the stomach, covered the pylorus. Other viscera, as far as examined, healthy.
31	Haldane. Month. Journal of Med. Science, Edinb., 1854.	Male age not stated.	Seven months or upwards.	None.	Not mentioned.	Not mentioned.	Costive; clay-colored stools during jaundice; previously dark and scybalous; not fatty.	Intense, but occurring as a late symptom.	Present, and both continually increasing.	No anasarca; but ascites, with much tympanitis.	For seven months.	Gradually, before death, sank into asthenic coma.	Pancreas cancerous, (by microscope) but disease was not at the head of the organ, which was healthy. Retrograde cancer-spots in liver, and in the mesentery. Gall-bladder much distended; ductus communis compressed, and involved in the disease.

Digitized by Google

32	Dr. Wilks. Transactions of the Pathol. Society of London, Vol. vi. 1855.	56; male.	Six months.	Abdomen felt rigid in the last stages of the disease, but no tumor perceptible.	In middle of back and in abdomen, varying in intensity; very severe at first; became dull, and lessened much as disease advanced.	None.	Obstinately constipated, but stools throughout normal.	None.	Emaciation steady and progressive; became extreme; debility not specially mentioned.	Slight ascites, as a late symptom.	Appetite bad, but not capricious.	Patient, when first seen, did not appear very ill.	Pancreas changed into a cancerous mass; in part fibrous and hard, in part gelatiniform. The head still retained some healthy structure. The duct, close to the duodenum, was pervious, but quite impervious when running through the diseased gland. The pancreas was closely adherent to the duodenum and stomach. A few of the gastric absorbent glands were partly infiltrated with morbid matter, but they were not connected with the diseased pancreas. The omentum was drawn up, and converted into a hard cancer. In it, and in the pancreas, were found well-marked cancer-cells. No cancer existed in other parts of the body.
33	Dr. Da Costa. Proceed. of Path. Society of Philadelphia, p. 8; or, North Am. Med.-Chir. Review, January, 1858.	45; male.	Seven months.	None.	Pain across epigastrium, but not severe; extending to back.	Occasional, and not at commencement of disease.	Constipated; dejections are clay-colored, not fatty.	Very marked; occurred rather early in the disease, and continually increased.	Both present, but neither to a marked degree.	None.	Very slight symptoms of indigestion.	Hemorrhage from the lungs.	Pancreas enlarged; its head and surrounding glands converted into a hard tumor, which, microscopically examined, proved to be a cancer; middle portion in a state of fatty degeneration. Pancreatic duct pervious. Liver enlarged, green and mottled, with irregular and large pigment masses in its structure; hepatic and common duct much compressed; cystic duct dilated; a few cancer-spots in liver; other organs healthy. All the cellular tissues were extremely yellow. The lower lobes of the lungs were voluminous and engorged; the seat of the hemorrhage could not be detected.

Digitized by Google

Case	By whom and where reported.	Age and Sex.	Duration.	Local Signs.	Pain.	Vomiting.	State of Bowels.	Jaundice.	Emaciation and Debility.	Dropsy.	Dyspeptic Symptoms.	Other Symptoms, and Remarks.	Post-mortem Appearances.
34	Dr. Agnew. Proc. of Path. Society, p. 84, or North Am. Med.-Chirg. Rev., July, 1858.	56; male.	One year; previously in good health.	None.	Pains of flying character, passing through abdomen to the right shoulder; no pain on pressure; feeling of fullness and weight in epigastrium.	Present; matter rejected was of a glairy character, and very offensive. Nausea was among the earliest symptoms, but vomiting occurred only as the case progressed.	Very torpid; evacuations clay-colored; sometimes greenish.	Very slight, if any; (countenance pale and bloodless; color of skin indicating a cancerous cachexia.)	Both markedly present; weight, when first attacked, 250 lbs.; at time of death, 120 lbs.	None.	Signs of indigestion were the first marked symptoms; nausea; flatulency; a feeling of fullness over the stomach.	Troublesome hiccough; he was a good liver, and had, for a long time, had slight dyspeptic symptoms, which became, rather suddenly, much aggravated; at the time they became so he was much depressed in spirits.	Pancreas enlarged to four times its size; its structure replaced by cancerous masses; also a deposit of cancer at cardiac orifice of stomach, (both examined with the microscope;) liver cirrhosed; the ducts pervious; kidneys also seemed granular. The enlarged mass of the pancreas pressed on the thoracic duct.
35	Dr. Bennett. "Clinical Lectures," p. 449.	50; male.	One year; previously in good health.	Tumor in epigastrium perceived by patient himself three months and a half before death; tumor very painful on pressure; could be moved upwards and to the right. It was distinctly felt, two inches below the ensiform cartilage, and three above umbilicus.	Pain severe and constant; is epigastric, but not increased on taking food.	Present; occurred at first occasionally; later, became constant; he vomited matter resembling coffee-grounds, mostly one hour to an hour and a half after meals.	Not mentioned.	None.	Both present and progressive.	None.	No appetite; pyrosis as a very early symptom; food could not be retained on stomach; thirst only occasionally; tongue and gums dry.	Tenderness over liver; pulse small and weak; slept but little; urine normal; prolonged expiration, feeble and harsh respiratory murmur in lungs.	Pancreas.—Its head involved with the surrounding mesenteric glands, and a mass compressing the pyloric extremity of the stomach in a cancerous tumor. This mass was seated in the smaller curvature, and projected into the stomach. The remaining portions of the pancreas were healthy, but the duct was obliterated. A cyst in the right kidney; liver felt hard and nodulated; lung presented gelatinous-looking masses, which, microscopically examined, proved to be cancer.

Digitized by Google

36	Dr. Bennett. "Clinical Lectures," p. 462.	50; male.	Eleven weeks.	None.	Gnawing pain in epigastrium, (was the first symptom of disease;) also acute grinding pain in the region of the liver.	No vomiting; food excited nausea.	Constipated; stools of a lead color; at times dark green.	Yellow tinge of skin appeared four weeks after first symptoms; jaundice steadily increased; finally skin became of a dark-green tint.	Emaciation not mentioned, but progressive exhaustion.	Not mentioned.	Loss of appetite; tongue slightly furred, moist, but became dry; considerable thirst; food excited nausea.	Two weeks after he felt gnawing pain, was overworked; drowsiness, loss of appetite, anorexia appeared, soon followed by jaundice.	Pancreas—right extremity converted into a cancerous tumor, rest of the organ indurated; contained a few small cysts. The portion of the common duct which passed through the tumor barely admitted a small probe. Behind this constriction the common, cystic, and hepatic ducts were greatly enlarged; liver of a green color; its bile-ducts dilated; some cancerous spots in liver, as also in kidney; gall-bladder distended, containing two gall-stones, supposed, by their passage from the liver, to have occasioned the grinding pain over the organ.
37	Case communicated to me by Dr. Harris.	44; colored woman.	Upwards of thirteen months.	None.	Constant, dull, and extending over abdomen.	Of watery fluid, depositing a blackish sediment; never of food; was not as constant as disease advanced; indeed, at one time ceased for several months.	Regular.	Yellowish conjunctive, but not early in disease, and never very marked.	Both present and progressive.	None.	Present from the first, increased with the disease; loss of appetite marked; tongue remained clean throughout; some flatulency.	Died of exhaustion.	Pancreas converted into a cancerous mass the size of a fist, and having the general characters of encephaloid. Its right extremity was mainly diseased; the liver was slightly enlarged, had a few small cancerous tumors on its external surface. The stomach was perfectly healthy, so were also the other abdominal organs; common duct pervious.

Digitized by Google

WEDNESDAY EVENING, September 8th, 1858.

The President, DR. GROSS, in the Chair.

Abnormal Size of the Groove for the Meningeal Artery, and Dilatation at its termination.—DR. AGNEW presented a skull with a very large groove for the great meningeal artery of the right side, and near the vertex at the termination of the groove a depression of sufficient depth to receive the end of the middle finger. He remarked that the Society would remember that on a former occasion he had exhibited a skull-cap having a similar groove and depression; but as no history could be obtained, all explanations offered were only problematical. It was believed, however, to be due to an aneurismal dilatation of the vessel. The present specimen he thought might furnish a satisfactory explanation of the condition in question. The artery, though unusually large, does not exhibit any positive evidence of dilatation, and near the vertex the main trunk breaks up into a great number of small parallel branches, with unusual groups of Pacchionian bodies placed between. Wherever these bodies are found there are usually little pits in the inner table of the cranium for their reception. In this case the extraordinary size of the groups placed among the numerous meningeal branches, derived from the main arterial trunk, will account for the large depression.

Tubercular Abscess of Right Kidney, and Chronic Inflammation of the Bladder, with destruction of its Mucous Membrane.—DR. GROSS exhibited a diseased bladder and kidney removed from John Anthony, aged fifty years, a resident of Carbon County, Pennsylvania, who had been suffering for four years with symptoms of vesical and renal disease. He consulted Dr. Gross early in August last; he was much emaciated, and became easily fatigued from the slightest exercise. He complained of pain in the right loin, and very severe pain in the region of the prostate gland. When first seen he stated that he had come to be treated for stricture of the urethra; but upon introducing a sound, the canal was found to be completely pervious, although somewhat tender; the sensation imparted by the examination was such as to induce the belief that the muscular coat of the bladder was hypertrophied and columniform. Mr. Anthony passed his water during the day about once every hour, and was obliged to get up seven or eight times during the night. His urine, which was offensive and scanty, was passed in a small stream, with much pain, and contained pus. The pain in the region of the prostate was so severe as to require

Digitized by Google

the use of opiates. His appetite was bad, and he complained of cough, with expectoration. The treatment consisted in the administration of the copaiba mixture with morphia to relieve pain, and he was ordered brandy and a nourishing diet; but he had no appetite for anything, and died in about two weeks from utter exhaustion.

Upon examination, seven hours after death, the right lung was found to be adherent to the pleura throughout the whole posterior aspect of the superior lobe, and in the apex and back portion of the same lobe a large tubercular cavity was found, as well as several smaller ones. The mitral tricuspid and aortic valves were thickened, and in some portions opaque; in other respects the heart was normal. Some of the mesenteric glands were enlarged. The left kidney was healthy, but the right was enlarged, and firmly adherent to its investing membrane. The substance of the gland was in some places so thin as to show the presence of pus beneath. Upon a section being made, this fluid gushed out to the amount of about two ounces; it was offensive, and bore all the distinctive features of being tubercular. The cortical portion of the kidney was much discolored. The ureter was but little enlarged, and contained some matter. Its mucous coat was slightly inflamed, and presented a capilliform injection.

Upon removing the bladder the index finger perforated the very thin walls at its apex, allowing the escape of a large quantity of pus into the pelvic cavity. The mucous membrane had completely disappeared, leaving the muscular coat entirely denuded, and presenting a deep maroon appearance. A cavity containing pus was found in the left lobe of the prostate gland, and the prostatic portion of the urethra was without a mucous covering. The bladder contained about six ounces of purulent matter mixed with a small quantity of urine.

DR. GROSS believed that such complete destruction of the mucous coat of the bladder was always the result of tubercular disease. He had examined several specimens which had confirmed him in this opinion. The deposits of tubercle taking place in the submucous tissue give rise, by their softening, to the extensive destruction witnessed in the organ.

DR. STILLÉ inquired whether there had ever been gonorrhœa. The morbid appearances, both in the bladder and kidney, did not seem to him to be of necessity tubercular; they might have been caused by a cystitis or nephritis, and the tubercular disease of the lung be independent of the affection of the urinary organs. No distinct tubercles in the kidney were perceived.

DR. GROSS replied that a disease of the urethra had not at any time existed.

DR. KELLER spoke of a case of tuberculosis of both kidneys which had

Digitized by Google

come under his care for a supposed vesical affection. The bladder was, however, found to be perfectly healthy, but the normal structure of both kidneys was entirely effaced. In one, the disease with what remained of the renal tissue formed a confused mass of broken down texture, in the other, the isolated gray tubercles were distinct.

Cystic Growths on Intestines.—DR. PACKARD stated that the subject in whom these growths were found was a man, aged thirty-seven, a patient in the Pennsylvania Hospital for nearly a year, on account of ascites, for which he was eight or nine times tapped; cirrhosis of the liver was suspected.

The abdominal cavity, when laid open at the autopsy, showed abundant traces of chronic peritonitis, the serous membrane having deposits of lymph scattered over its entire surface. The liver particularly was encased in a thick layer of false membrane, but its size was not notably diminished, nor was there anything else abnormal about it, except that its tissue was less easily torn than is usually the case.

The intestines seemed entirely healthy, but at different points along the canal were attached cystic growths, over a dozen in number; these growths were of various sizes, from that of a marble to that of an orange, the largest being situated in the great omentum, close to the transverse colon. They had no connection, vascular or otherwise, with the bowel, merely lying in the sub-serous tissue. One of the smaller ones only was subjected to a careful examination: it contained a clear-yellow liquid, somewhat ropy, like synovia, and stretching in a wavy manner through this were several flocculent masses or bands, like imperfectly-formed septa. The liquid, placed under the microscope, was entirely homogeneous, but here and there one or two nucleated granular cells were seen floating in it. The flocculent bands alluded to were found to have a dimly-fibrillated or nebulous appearance.

DR. HEWSON reported the death of the patient whose thigh-bone he had exhibited to the Society. (See Proceedings of Dec. 23d, 1857.) The wound had nearly healed, but a troublesome diarrhœa set in about three months after the operation, which exhausted the patient. He died on the 16th of July.

WEDNESDAY EVENING, September 22d, 1858.

The President, DR. GROSS, in the Chair.

Abscess of the Brain following Fracture of the Skull.—DR. HALL exhibited for DR. HUTCHINSON a fractured skull and an abscess of the

Digitized by Google

brain. The patient, R. W., aged twenty-three, colored, was admitted into the Pennsylvania Hospital on Friday, September 10th, with contused wounds of the scalp and two wounds of the face, which appeared to have been made by penetrating instruments. Through one of the wounds of the scalp a depressed fracture of the parietal bone was discoverable; the zygoma also was found to be fractured. The patient was unable to give any particulars of himself, and no satisfactory account of the accident has been obtained. He was able to walk, but was, during and after the examination, so exceedingly restless, that he had to be confined. His pupils were sluggish, but neither dilated nor contracted; the pulse was ninety-four. He was trephined the next day, and the depressed portion of bone raised, but he never fully recovered his power of speech, although his intelligence increased, so much so that he put his tongue out when told to do so, and appeared to take an interest in things around him. His fæces, however, passed involuntarily from him, and his urine had to be drawn off by a catheter. Four days after the operation he had a chill, which was very slight, and not repeated. But his symptoms became again worse, and he gradually relapsed into a comatose state. Just before his death, on the morning of the 22d, abscesses formed about his ankles, which discharged pus and a quantity of fetid gas. Upon making a post-mortem examination, the brain was perceived to be much softened, and a large abscess existed immediately beneath the point at which he had been trephined. The fracture was found to extend down to the base of the skull, involving the sphenoid and temporal bones.

Metastatic Abscesses of the Liver following an Injury of the Head.—DR. HALL next exhibited for DR. HUTCHINSON, a liver with several abscesses, from the body of Edward Morris, aged fifty-seven years, seaman, who was admitted into the Pennsylvania Hospital on Thursday, the 2d of September, with a contused wound of the scalp over the left parietal bone, and one on the same side of face, beneath the orbit. Neither appeared to be serious, and there was nothing in his condition to occasion any alarm until Sunday, September 19th.

On Friday he complained of pain in his head, but this was not sufficient to confine him to bed. On the same day he had a chill, which, as he formerly suffered from an intermittent, was attributed to that cause.

On Saturday he complained of pain in his abdomen, which was relieved by a mustard plaster. He had an old rupture, but there was no reason to suspect any strangulation.

Finding on Sunday that the patient had retained his water, about f℥iv of a yellowish liquid was drawn off, which did not possess, in the slightest degree, the smell of urine.

Digitized by Google

On Monday a little blood was discharged through the catheter. During Sunday night and Monday, he had spasms of the muscles of the right side of the body, and in a less degree of the left side. He died on Tuesday morning at two o'clock; the autopsy was made on the same day at 2 P.M.

There was no fracture of the skull, but immediately beneath the spot upon which he had been struck was a deposit of pus, and within the membranes a deposit of lymph. The brain was very much congested. In the liver several abscesses were detected, and in the kidneys some pus. The bladder was very much contracted, and contained clots of blood.

This specimen led to an animated discussion, mainly carried on by Drs. Keating, Hewson, and Woodward, in which the different prevalent theories concerning the formation of metastatic abscesses were reviewed.

Tubercles in the Peritoneum and in the Liver.—The Secretary presented, for DR. H. LENOX HODGE, a specimen of tubercular peritonitis, with the subjoined history:—

Patrick Bannon, aged fifty-four years, a native of Ireland, was admitted into the Pennsylvania Hospital on the 6th of August, for dropsy. He could not give a very accurate account of his disease, but stated, in reply to our questions, that until he had taken this affection he was well as anybody, that he had not been able to work since spring, that now he could eat nothing, and was obliged to drink all the time. Upon examination, the abdomen was found tense, but not very much distended; fluctuation, although not very evident, could be detected; there were vague pains throughout the part, especially on motion; the urine contained no albumen, and showed no evidence of disease; the heart appeared healthy upon percussion and auscultation; the liver certainly was not enlarged, and perhaps did not cause dullness over quite as large a space as usual. After noticing these symptoms, Dr. Gerhard said that the case was probably one of chronic peritonitis. Under the influence of diuretics, such as cream of tartar, juniper berries, squill, and digitalis, the dropsical symptoms lessened and soon disappeared. After a time, upon the application of counter-irritants, the pains left the abdomen. Thus the patient became more comfortable; but he had no appetite, and he grew more and more emaciated. A slight cough that he had had before entering the hospital increased; evidences of tubercles and cavities were detected in the lungs; and gradually becoming weaker and weaker, he died yesterday, (the 21st,) in the morning.

Autopsy.—The lungs contained tubercles at the upper portion, especially of the right lung, where there was a cavity, and also one at its very base. There were very few pleuritic adhesions, and these chiefly at the

Digitized by Google

lower portions. The heart was healthy, the pulmonary arteries considerably dilated. Upon opening the abdominal cavity, the peritoneum was found much thickened, and the abdominal walls everywhere studded with tubercles; the mesenteric glands were much enlarged. Liver about the normal size, but containing, in the left lobe especially, tubercles. Kidneys were healthy. The spleen contained tubercles in its capsule, though not in its substance.

Ulcer of the Stomach.—DR. KEATING presented a specimen of perforating ulcer of the stomach, and gave the following history:—

Mrs. L., aged fifty-one, of sallow complexion and spare habit, had consulted me at various intervals during the last four years, in reference to a pain which she now and then experienced over the cardiac orifice of the stomach. She occasionally suffered from violent pyrosis, cardialgia, and other symptoms of dyspepsia, and became at times exceedingly emaciated. Having in connection with this pain constant palpitations of the heart, she was convinced that her affection originated from some cardiac disorder. During the month of February last, she was occasionally troubled with rejection of her food about an hour after eating; but this, as well as her other dyspeptic symptoms, yielded rapidly to treatment.

In March last, I was sent for in haste to visit her on account of a profuse vomiting of a chocolate-colored fluid, in all about a pint and a half. I submitted a portion of this fluid to my friend Dr. Da Costa for an examination under the microscope; he reported the existence of broken-down blood corpuscles in abundance, sarcinæ ventriculi, and mucous membrane in a state of degeneration. This hemorrhage had been preceded by a great increase of pain over the left side, corresponding with the cardiac orifice of the stomach. Upon careful examination, I could not discover the existence of a tumor in any portion of the stomach or abdominal cavity. The hemorrhage soon yielded to treatment, but it was followed by a constant rejection of the food taken during the day. Sometimes the vomiting occurred two hours after each meal; at other times twelve hours would elapse without any rejection of food, and then suddenly about daybreak profuse emesis would take place, bringing up in a partially digested form the engesta of several meals. This state of things continued with but little variation for four weeks, although at times the symptoms would lull, and apparently yield to treatment, so as to induce hope that the disease might be cured. At one period she was nearly three weeks without vomiting, and began to gain flesh. Another hemorrhage set in, and was followed by the previous train of morbid symptoms.

Her appearance at times indicated so strongly a malignant disease, that Dr. Pepper, who visited her in consultation, feared with me that the ulcer-

Digitized by Google

ation might be malignant, especially as she had had a sister who died of scirrhus of the rectum. These fears, however, were dispelled by our examination for a tumor, no traces of which could be detected. The pain continued over the left portion of the stomach, the vomiting increased, until, on the 16th of the last month, symptoms of perforation set in, and death followed in twelve hours.

Post-mortem examination revealed a healthy state of all the organs save the stomach; in which was found, about an inch from the cardiac orifice, on the greater curvature, a perforated spot, with thick indurated edges; about half an inch from this ulcer there was a partial softening of the stomach, and evident signs of another ulcer forming. The remaining portions of the stomach were in a healthy condition. An examination of the ulcerated part by Dr. Da Costa, under the microscope, gave no evidence of malignant disease; and hence, although situated near the cardiac orifice and along the greater curvature, the disease was undoubtedly a chronic perforating ulcer, with a constant deposit on its edges during the gradual process of perforation.

The death in these cases usually ensues from hemorrhage, emaciation, or perforation. In her case the hemorrhage was always immediately controlled by the tincture of the perchloride of iron; the emaciation was not excessive, for at the post-mortem examination large deposits of fat were found under the abdominal muscles, and in different portions of the abdomen. In reflecting upon the therapeutics of such cases, I believe that the greatest chances of success are to be found in a continued opiate treatment, with an allowance of just sufficient nutriment to support life; the stomach might thus be placed in the condition of throwing out bands of lymph, and of protecting itself from perforation and effusion of its contents. Undoubtedly such a method of treatment affords more hope in the chronic perforating ulcer, than in the acute with its sharp edges.

The question which presents itself for solution is, whether these ulcers are simple local lesions, or whether they may be a local expression of a general cachectic condition of the whole system? In this case, a point of interest lies in the fact that the patient was of an age at which ulcer of the stomach is certainly not often met with; nor is, indeed, the disease in this country at all frequent. Judging from the few cases which have been reported, its occurrence must be far rarer than in England, or on the Continent of Europe.

Digitized by Google

WEDNESDAY EVENING, October 13th, 1858.

The President, DR. GROSS, in the chair.

Tubercles in the Cerebrum and Cerebellum.—DR. PACKARD, in presenting these specimens, said:—For notes of this case, I am indebted to Dr. F. W. Lewis and Dr. Dunton, who attended the patient.

James Gray, aged six, of a hereditary scrofulous habit, slipped, or was pushed, from a sidewalk, in September, 1857, and in his fall struck the back of his head forcibly against the curb-stone. The blow stunned him for a time, and for several weeks he had occasionally severe attacks of pain in the occiput. He however continued otherwise well until the latter part of December, when the paroxysms of pain became more frequent and intense, recurring several times daily.

From this time he grew worse and worse until April 26th, 1858, when he was admitted into the Children's Hospital, under the care of Dr. Penrose. On admission his symptoms were as follows:—Head rather large, body and limbs decidedly emaciated; expression of countenance "cerebral," with a marked amaurotic stare, and considerable dilatation of both pupils, particularly of the *left;* complexion somewhat waxy, with irregular flushing of one or both cheeks; decubitus dorsal, with slight flexion backward of the head. His intelligence was not impaired, nor were his special senses, except, perhaps, that of vision. He complained at intervals of intense pain in the occiput, and during these paroxysms he would utter short, sharp cries; their duration was usually two or three minutes. They occurred several times in the twenty-four hours, and were most aggravated at night. The temperature of his skin was natural; his head was not abnormally heated; his respiration was unaffected; his pulse regular, full, about 80 per minute. His appetite was voracious, but his digestion rather sluggish, and his bowels constipated.

He was removed from the hospital in about ten days, having derived no benefit during his sojourn.

From this date the unfavorable symptoms made very rapid progress. His emaciation became very considerable, especially in the body and extremities; his complexion more waxy, and the irregular flushing of one or both cheeks more vivid. In addition to the decubitus before mentioned, his knees became drawn up. His intellect was still clear; the amaurosis was now complete. There was no unusual heat of head, but the temporal and carotid arteries throbbed very forcibly during the paroxysms of pain, which amounted to agony. These attacks now recurred

Digitized by Google

about every half hour, with a strongly-marked tendency to remission on the alternate days.

His digestion, respiration, and pulse, (except during the attacks,) continued much as before; his appetite was capricious, although mostly very voracious. It was always observable that the act of mastication continued for some time after his food had been swallowed. Owing to his inordinate appetite he had frequent dysenteric attacks; toward the close he began to pass his urine and stools involuntarily. The urinary secretion was generally copious, high-colored, of neutral reaction, and showed a tendency to deposit phosphates shortly after being passed. No priapism was at any time observed.

About the beginning of July, the emaciation and debility became so extreme that his death was daily looked for. He rarely moved, but lay with his knees drawn up, his head thrown back, his eyes open, his pupils (especially the *left*) enormously dilated, the conjunctivæ inflamed and covered with a viscous secretion. His pulse became more frequent and irregular, and he could hardly be seen to breathe at all. From this apparently almost lifeless condition he would at times rouse himself and call for food.

July 23d.—He cries at intervals; answers questions, but never talks. Flexors of both upper and lower extremities in a state of tonic contraction. He has some difficulty in swallowing; tongue red and covered with *muguet*. His bowels are quiet, and have been for three days past; previous to this he had diarrhœa.

July 25th.—He has less difficulty in swallowing; vomits occasionally; was several times convulsed during the night.

July 30th.—An ulcer appeared on the right cornea. He gapes continually.

August 17th.—Emaciation much increased; contraction of flexors more decided.

August 26th.—Diarrhœa; abdomen much retracted, with enlargement of its superficial veins.

August 30th.—Has had no convulsions for the last two weeks, but lies moaning; occasionally his breathing seems to stop entirely. His death occurred on the 3d of September.

By the kindness of Dr. Dunton, I assisted at the autopsy, which was made thirty-three hours after death; the head only was examined.

Brain softened, and a very large quantity of serous effusion in the ventricles. The cineritious layer was very thick. In each lobe of the cerebellum was found a tumor of about the size of a walnut, rounded, deep-yellow, of firm consistence, and presenting traces of a concentric formation.

Digitized by Google

A similar tumor, but of smaller size, was taken from the posterior portion of the right cerebral hemisphere.

Under the microscope, the structure of these tumors appeared to be tuberculous. Some of the elements observed bore some resemblance to those seen in amyloid formations in the brain.

A case remarkably similar, in some respects, to the one I have now reported, was published by Dr. Pepper, in the *Medical Examiner* for December, 1856. In that case there was, however, no injury known to have been received, and the course of the disease was much more rapid, (only four months;) the attacks were also much more epileptiform in their character. In my notes taken at the time of the autopsy, some particulars are set down, which were omitted by Dr. Pepper because they had no direct bearing upon the point discussed in his article.

The calvarium being removed, the skull was found to be excessively thin—having not more than half its proper thickness. The inner surface was rough and vascular, and much darker than normal; on the outside, a patch, reaching from the coronal suture back as far as the division of the skull, (in removing the skull-cap,) and on each side to the line of attachment of the temporal fascia, was discolored in much the same way, and the vessels most beautifully injected.

On removing the brain with the dura mater, the base of the skull had a similar appearance, being over the sphenoidal cells so thin as to feel like a mere membrane. This change was especially well marked in the channels for the lateral sinuses, which seemed deepened as if by an erosive action. The surface of the brain was much congested, and a large quantity of clear serum escaped when the dura mater was cut into.

The cerebellum was softened down, and within its substance, just between the two lobes, was a tuberculous deposit of the shape of an English walnut; this mass weighed half an ounce, and measured an inch and a quarter in diameter.

Pneumonia and Pleuritic Effusion occurring in Enteric Fever, with signs of Perforation of the Intestine, but without any post-mortem evidence of this lesion.—DR. HALL exhibited, for Dr. Albert H. Smith, an ulcerated intestine and inflamed lung, removed from the body of Chas. Huttner, aged thirty-two, German, who was admitted on the 11th of September into the Pennsylvania Hospital. He had been taken sick, about two weeks previously, with enteric fever, and passed through the ordinary course of the disease without having, as far as could be learned, any remarkable or unusual symptoms. On the 27th of September he was convalescent; the rose-spots had disappeared; the pulse was regular; the bowels very slightly inclined to diarrhœa; no tenderness of abdomen; no

Digitized by Google

chest symptoms, except an occasional appearance of sonorous rhonchi; and although quite weak, his strength was gradually returning and all the functions being well performed.

In this way he continued (great care having been taken to guard him from exposure to cold, and from the use of any solid or irritating diet) until the morning of the 6th inst., when he was found with a cold, clammy skin, the pulse 160, feeble and irritated, the countenance anxious and distressed, with great pain in abdomen, slight tympanites, and a tendency to delirium. On the supposition that perforation had taken place, he was placed upon beef-essence and milk-punch; dry cups were applied to the abdomen, and sufficient laudanum was given to narcotize. The symptoms continued for twenty-four hours, when they entirely subsided. The skin became warm and dry, the pulse fell to 110, the pain in abdomen ceased, no tympanites was present, and the patient felt altogether more comfortable, although greatly prostrated. The stimulants and nourishment were continued.

In about twelve hours another set of symptoms had developed themselves. In addition to the dry, hot skin and frequent pulse above mentioned, there came on, for the first time, violent chest symptoms: great oppression and dyspnœa, constant cough, with expectoration of bloody sputa; entire flatness of the posterior portion of both lungs and the lower lobes anteriorly; subcrepitant rhonchi on right side, at base; crepitant rhonchi and friction sound on left side. The patient was dry-cupped over the chest, blistered on the left side, and kept constantly turning so as to prevent hypostatic congestion. Mustard poultices were applied to the extremities, and carbonate of ammonia was administered, but he continued to sink from this time, and died on the 9th.

The autopsy showed congestion of the lower part of right lung, with red hepatization of the lower lobe of the left; over the whole pulmonary pleura of the left side there were thick patches of lymph, and in the pleural cavity about a half-pint of serum. There was no other lesion except the ulceration in the small intestines, which was extensive, but appeared to be healing. No evidence of perforation could be detected.

Phthisis with Paraplegia.—DR. HALL exhibited, also for Dr. Albert H. Smith, a tuberculous lung and a softened spinal marrow:—M. B., aged fifty-four, was admitted into the Pennsylvania Hospital September 27, 1858, with evident signs of tubercle at the apices of both lungs. He had a cough, and had been gradually losing his strength for six weeks. He was very feeble, almost unable to walk, dragging the right leg in his attempts; the countenance was pale, with a particularly anxious and haggard expression. His symptoms gradually grew worse, until com-

Digitized by Google

plete paraplegia of the lower limbs ensued. There were no cerebral symptoms; sensation and voluntary motion declined gradually and simultaneously in the limbs; there was no spasmodic action. He died from general prostration, his death being hastened by suffocation from inability to expectorate.

The autopsy showed both lungs infiltrated with tubercles; a cavity existed at the upper portion of the right lung; the heart, brain, and the other viscera were healthy; on removing the arches of the vertebræ, there was found in the arachnoid about six ounces of serous fluid; the pia mater was greatly injected; the congested vessels ran in places into the substance of the cord, which was completely softened.

Gangrene of the Spleen.—DR. HALL presented the following paper on gangrene of the spleen, with a water-color drawing of a specimen of the disease:—

Of this abnormal condition of the spleen Rokitansky observes, "that it is as rare an occurrence in the spleen as in the liver; we have had an opportunity of observing it once in a chronic tumor of the spleen, affecting the organ to a considerable extent."

Baillie* remarks "that it is very rare to find the substance of the spleen either in a state of inflammation or suppuration, but such cases have been occasionally observed and related by authors. Instances have also been related where the spleen has been observed to be 'mortified,' but this I should believe to be even much more rare than the former."

As a witness on the other side, Portal† states that "Gangrene of the spleen is observed rather frequently, (assez souvent;) it is recognized by the softening of its tissue, and the fetid odor which it exhales; it is the frequent consequence of the inflammation of this viscus, and then the rational symptoms (les symptôms exposés) above mentioned diminish or cease suddenly, and mortal weakness and sinking succeed. It has also been remarked in subjects who have died of malignant fevers."

Case.—During my service of House-Surgeon in the Pennsylvania Hospital in 1856, was admitted on the 25th of September a stout, vigorous young German, Michael H——, aged twenty-three, with an extensive gunshot wound of the upper part of the right arm, which had cut clean across the brachial artery at the upper third of the biceps muscle of that side. There was not any bleeding of consequence at the time of admission, although we were told that there had been, an hour before; shortly after the occurrence of the accident, a Spanish windlass had been twisted above the wound, but no ligatures were applied. The brachial artery was tied

* Morbid Anatomy, p. 168. † Anatomie Médicale, tome v. p. 336.

Digitized by Google

in the wound, and eight or nine ligatures were put on smaller vessels after admission into the house. The arm from the site of injury down to the fingers was cold; there was no pulsation in the arteries below the wound. A consultation was held, but the man was so depressed from the shock that amputation at that time was out of the question. On the next morning, however, the patient having rallied sufficiently, Dr. Neill (the surgeon on duty) amputated the arm about three inches below the axilla.

October 27th, (a month after the operation.)—Pulse 102; patient feverish, with hot skin and flushed cheeks; great deal of deep suppuration in the stump, an erysipelatous blush on its surface; complains of pain in the right "hypochondrium." [I wish the Members to remark this hypochondriac pain, as I think that it was reflexly sympathetic from the inflamed spleen in the left hypochondrium.]

The next day he had a slight chill, followed by fever and sweating; pulse 99, full and quick; tongue a little furred, yellow; "*pain* still in the right hypochondrium; *increased* by pressure."

November 4th.—My term of service in that ward having expired, I handed over my charge to Dr. George H. Humphreys, my successor in office, still, however, by his kindness, observing with him the progress of the case.

Some time later, unmistakable symptoms of pyæmia developed themselves, became confirmed, and, as usual, in spite of any treatment, carried off the patient in about four weeks' time.

Sectio cadaveris ten hours after death.—Rigor mortis well pronounced; body not much emaciated, well formed. Head not permitted to be examined. The bone of the amputated arm presented a ring of necrosis one-quarter of an inch in length. Pus in the veins of the stump. On opening the thorax one quart and a half of straw-colored serum was found in the pleural sac. The lungs were much congested, with localized spots of inflammation; several small abscesses of one inch in diameter were found in the posterior aspect of the lungs. Liver healthy. The spleen was lobulated; it measured five and a half inches in length, and four inches in breadth; form natural, *i.e.* slightly concavo-convex. Color of a bright-red, approaching crimson. On its anterior inferior surface was a patch of gangrene one and a half inches in circumference. This was of a dark, greenish hue; mottled; color well defined; not shading off into the color of the surrounding texture; flaccid to the touch, with a sense of fluctuation. Odor, garliclike.

There was a well-marked line of demarkation, of a pinkish color, with numerous vesicles upon its surface. The discoloration was superficial, merely involving the capsule, not going down into the splenic substance; beneath this was a cavity two inches in depth, filled with a soft chocolate-

Digitized by Google

colored matter. There was a small cherrylike cyst on the omentum, just beneath the spleen. Bladder distended with urine.

As already stated, gangrene of the spleen is of very rare occurrence. Rokitansky* speaks of an inflammation of the spleen, in which "the portion affected is converted into a puriform creamy mass, or into a sanious, greenish, greenish-brown, or chocalate-colored pulp." Magaziner† gives an account of an epidemic gangrene of the spleen that occurred during the year 1831, at Dorfe Mandrowa, Russia, called by him the "Siberian Epidemic," or "Splenitis Gangrenosa."

A male and three females were seized with a burning pain under the præcordial region; with nausea; pain in the abdomen, and especially about the spleen. Two died, and a post-mortem examination gave the following appearances: Body of the patient who died on the third day of the disease.

"A dark spot on the left side of the abdomen; traces of inflammation here and there on the peritoneum; stomach and intestines distended with gas, and inflammation of their external surface; the spleen, much enlarged and tender; when divided gave issue to a great deal of dark blood, and presented on its surface *a large* gangrenous point." Nothing abnormal in the head or chest.

The appearances were the same in the body of the other patient.

On the 29th January, 1831, two females were seized with the same symptoms, and the writer now recognized the existence of the "Siberian Epidemic," or "Splenitis Gangrenosa." There is a reference to this Siberian Epidemic in *Canstatt's Jahresbericht*‡ for 1851.

Bright§ notices the occasional occurrence of gangrene of this organ, and cites the case of Anne Howell, a house-maid, aged twenty-one, received into Guy's Hospital, January 24th, 1829, with symptoms of great depression, in a most reduced state, having been ill some weeks and undergone active treatment for what was supposed to be carditis. On admission there was observed a rapid, weak pulsation of the heart, and frequent vomiting, under which she sunk in about ten days.

Sectio cadaveris.—In the abdomen there were some cellular adhesions of long duration between the liver and diaphragm, and between the liver and stomach; on the left side were more recent adhesions in the neighborhood of the spleen, circumscribing a cavity bounded above by the under-surface of the left lobe of the liver, to the inner side by the stomach, and to the outer side by the spleen. This cavity contained an offensive dark-colored matter, with "a strong gangrenous odor," which

* Path. Anat., vol. ii. p. 137, Am. ed.

† Kleinert's Repertoire, from the Russian Military Med. Gazette, No. 3, 1833.

‡ Band vi. p. 15.

§ Guy's Hospital Reports, vol. iii., 1838.

Digitized by Google

was produced by the breaking down of a portion of the spleen, extending no great depth into the organ, the remainder of which was firmer than natural, and of a *red color*.

I wish to call the Society's attention to the red color of the spleen, as it was so well marked in the specimen before them. It was not owing to the action of the air upon the organ, but presented the same hue at the moment of removing the organ from the body. It is undoubtedly the intense red of acute inflammation.

Many cases of disorganized or broken-down spleens are quoted by Lieutaud.* Of course what some of these older writers say on this subject must be received with caution; but still, when they describe the appearances of gangrene, together with "a most offensive odor," it is but right to believe that what they saw was gangrene: "A man† died on the eighteenth day of a continued fever; the spleen was tumid, livid, and 'greenish,' from which, when incised, a great quantity of matter like black pitch flowed forth." Also, a case‡ in which the spleen was livid and black, a portion cut off, as though amputated. Another,§ in which the spleen was gangrenous and partly destroyed. Finally,‖ a gangrenous and putrid spleen, after a pneumonia.

Cases are cited by Morgagni,¶ one in which the spleen was impregnated with a gangrenous blackness, and exhaled "a most offensive odor."

The "offensive odor" here mentioned is of more importance as a point of medical evidence than the gangrenous blackness so often dwelt upon. This black color may exist without gangrene; it should not, taken alone, be considered as a sign of gangrene.** Morgagni†† cites a case after peripneumonia:—"The abdomen being opened, a heavy odor was perceptible, as if from inflamed viscera, taking on gangrene. The liver was whitish, but the spleen was affected with a gangrenous blackness."

Dr. Janney, of this city, informs me that he has seen a case in which the spleen was three times its natural size; he cannot recollect how large the gangrenous portion was, as it occurred years ago during an epidemic of intermittent; it had a gangrenous odor, and he had no doubt that it was gangrene.

Briefly to compare other states of the spleen with gangrene, I shall indicate how a lesion which resembles it most—abscess—is found in the organ. Abscesses of the lungs and liver are not unusual after opera-

---

* Historia Anatomico-Medica, tome i. p. 228.
† Observat. 958.
‡ Ibid. 961.
§ Ibid. 966.
‖ Ibid. 970.
¶ Epist. Anat.-Medica, xxv. art. 16.
** Path. Générale, 1856, p. 545, (Chomel.)
†† Epist. xxi. art. 29.

Digitized by Google

tions, injuries of the head, compound fractures, puerperal phlebitis, and even suppuration around a foreign body; but in the spleen they are not often observed. Speaking of pyæmia, Nélaton* remarks the frequency of abscesses of the lungs and liver, but does not notice their presence in the organ under consideration. Mackintosh,† however, mentions a case of a large abscess of the spleen, after an amputation of the leg. In the fourth volume of the *Transactions of the Pathological Society of London* is reported an abscess of the spleen after puerperal phlebitis.

The splenitis in these cases is consecutive, and owing to an alteration in the blood crasis. Cases illustrative of this particular point, and most practical remarks upon its pathology, are given by MM. Huguier and Littré.‡ Very interesting cases of abscess of the spleen, after fracture of the skull, leg, (compound) etc. are to be found in the *Lancet* for 1827–28, vol. ii., by Thos. Rose, Surgeon to St. George's Hospital.

There are only three conditions with which gangrene of the spleen can be confounded. These are:—

1. Apoplexy.
2. Abscess.
3. Post-mortem change of color.

That it was not apoplexy is clear from the description given by MM. Mignot and Lemaistre.§ One of these cases was from continued fever, the other from a paroxysm of intermittent.

"In each case there was an apoplectic spot, of greater or less extent, containing a half-liquid blood, and a kind of red, pulpy substance." This corresponds essentially with Choulant and Richter's account of the same lesion.‖

It differed again from the appearances presented in abscess of the spleen, for "pyæmic abscesses (metastatic) form a single, circumscribed, peculiar deposit, which goes wedgelike from the circumference toward the centre; it is at first blackish-red, then yellowish, but with dark margins, and finally purulent."¶ Or, again, the spleen may be found "of a tawny color, soft, friable, presenting either traces of purulent infiltration, or scattered depots of pus, or a voluminous abscess."**

It remains, in conclusion, to consider changes of color, particularly

* Clinical Surgery, p. 154.

† Practice of Physic, vol. i. p. 355.

‡ Journal Hebdomadaire de Médecine, tome vii. p. 424, and tome iv. p. 419.

§ Bull. de la Soc. Anat., 1848, (quoted by Valleix.)

‖ Choulant and Richter, Path. und Ther., p. 970.

¶ Choulant, p. 970.

** Valleix, Guide du Médecin Practicien, tome iii. p. 275.

Digitized by Google

green coloration. "Green coloration of the tissues," observes Vogel,* "is but rarely met with. It is sometimes observed in the lungs, the intestinal canal, and the muscles." Most of these tints depend upon changes in the body after death; some, he thinks, may be owing to the presence of sulphuret of iron, while others result from effects of putrefaction, unknown to us. He hazards the conjecture that many of these changes are owing to bile-pigment permeating the walls of the gall-bladder, and spreading, by imbibition, into the surrounding parts. "Further investigations must determine whether this kind of coloration of the dead body is seen in man at any distance from, or whether it is confined to, the immediate neighborhood of the gall-bladder."

In the case cited by Vogel, the discoloration was pretty general, and extended into the parts adjoining the gall-bladder. But in the case before the Society the change in color was small in extent, local, circumscribed, and at a comparative distance from the gall-bladder.

The intense general hue of inflammation of the organ, the line of demarkation, with its superincumbent vesicles, the peculiar fetid odor, and the character of the mass contained in the spleen, forbid us then to confound it with any of the above conditions.

Cancer of the Great Omentum, Pyloric Extremity of the Stomach and the Small Intestines, with Fibrous Tumors of the Uterus.—DR. DARRACH presented these specimens, which were removed by Dr. Barlow Darrach, at an autopsy upon a patient of Dr. Fricke, of this city. The patient was a female, of German extraction, married, and had had one child, a daughter. She was a tall, gaunt person, forty-eight years of age, and of a nervous temperament. For the last fourteen years, at least, she has not been known to have had any *severe* sickness. She had always suffered from a dry, parchmentlike state of the skin on the arms and lower limbs; and has also had frequently slight attacks of dyspepsia, accompanied with eructations of wind and loss of appetite, which always yielded readily to some mild remedies, such as an aperient pill, etc. She was a hard-working woman, having for many years been a cook in a large eating establishment.

The sickness, which terminated in her death, commenced in July last. She then complained of great pain in her back, and shortly afterwards she had numerous and large alvine discharges, accompanied by tenesmus. Her stools were changeable in appearance; sometimes mucoid, at other times presenting well-formed discharges. In the latter part of her affection, the intestines were constantly distended with gas, so much so as to prevent a

* Path. Anat. Human Body; Phil. 1847, p. 860.

Digitized by Google

satisfactory examination of the abdominal viscera. She still suffered much from eructations of wind, and a diffused pain over the abdomen.

The above symptoms gradually augmented throughout July and August, the pain becoming the prominent symptom. A very severe attack of palpitation of the heart occurred at the end of the month of August. Dr. Fricke thought this to be owing to the action of quinine, which she was then taking. This palpitation was so alarming that the woman was thought to be dying; but relief was obtained after the administration of valerian. Now followed great insomnolency and constant vomiting for two weeks, which was considered to be owing to some obstruction in the bowels. The tongue was natural; the patient had no cachectic appearance.

Autopsy.—The abdominal cavity alone was examined. The liver was healthy; the stomach was thickened at the pyloric end, which thickening, from microscopical examination, was proved to be cancerous; no cancerous elements could be discovered, however, in the other parts of the thickened walls of the organ; from which it was inferred that the thickening, except at the pyloric end, was owing to hypertrophy. The great omentum was also thickened and contracted from cancerous deposit, which was undergoing oily degeneration; the small intestines, for the distance of about one or two feet from the ileo-cæcal valve, were thickened and contracted by a deposit which had all the characters of cancer. Beneath their peritoneal investment were numerous small circumscribed deposits, resembling the deposits of tubercles, but which were found to consist of cancerous elements. The kidneys were healthy; the uterus had four fibrous tumors growing from its fundus, the largest one, being about the size of a large walnut, had undergone peripherally calcareous degeneration; the appendages of this organ were healthy.

Cancer of the Liver and Supra-renal Capsules; no Bronzing of the Skin.—DR. DA COSTA presented, for Dr. Wm. King, a cancerous liver of enormous size:—Frederick Harkin, aged thirty-five, a native of Ireland, and a farmer by profession, was admitted into the St. Joseph's Hospital on the 19th of August, 1858, suffering with an abdominal tumor, extending from the right to the left hypochondriac region, and downward some inches below the umbilicus; it was hard, knotty, and immovable. The tumor had been noticed by the patient, for the first time, about three months previous to his admission. Upon making inquiries as to its first appearance, he persisted in stating that it came on suddenly after drinking a quantity of water; while his wife, with about equal accuracy, attributed it to a stroke of lightning. The symptoms, during the whole course of the disease, were not well marked, and it was impossible, with any certainty, to

Digitized by Google

form a diagnosis. At the Pennsylvania Hospital, where the patient had been under treatment for a month, no positive opinion as to the nature of the affection had been given. At the St. Joseph's Hospital, his attending physicians, Drs. Keating and Keller, came to no definite conclusion as to the true character of his disease.

Vomiting was one of the most prominent symptoms; it was generally induced by a full meal; the matter ejected consisted, first, of the food he had taken, and afterwards, of a glairy mucus. The liver appeared to perform its functions up to the time of his death; no symptoms of jaundice appeared; the bowels were regular, and the stools bilious; the patient felt no pain in any portion of the chest or abdomen; nor did pressure occasion any. Debility was one of the most distressing symptoms of which he complained; although not confined to his bed while under treatment, he expressed little desire to be moving about. Emaciation was present in a slight degree, but the peculiar cachectic condition of the system, common to cancer, was entirely absent; the color of the skin was natural. From the 19th of August up to the time of his death, which occurred on the morning of the 24th of September, he suffered only from debility, the weight of the tumor, and vomiting after meals. On being asked by the attending physician, a few days before his death, if he was improving, he expressed the opinion that the tumor was much lighter.

On the evening of the 23d he passed a good night. At about four o'clock on the following morning he arose from his bed, but became suddenly so weak that he had to be assisted back by the nurse. After having been placed in bed, he vomited, at first water, and afterwards mucus; the vomiting was succeeded in a short time by insensibility; the pulse was frequent, but small; the breathing labored, and the face of a livid hue. In this condition he remained until twelve o'clock, when he died.

Autopsy.—Six hours after death an examination was made, which revealed the following conditions of the viscera:—The liver formed in the abdomen a large tumor, weighing twelve pounds, which occupied the right hypochondrium, the epigastrium, and the left hypochondrium, and descended some inches below the umbilicus; its anterior and posterior surfaces were covered with a number of whitish indurated masses, evidently cancerous; these deposits were more numerous on the left lobe and on the edges; the liver measured thirteen inches in length, twelve inches in breadth, and four inches in thickness through the centre; the gall-bladder was distended with bile. The stomach was much displaced, but in a healthy condition; the pyloric extremity rested on the spleen, this organ being much increased in size, and of a dark color; the transverse colon was situated at the lower portion of the abdomen, as far down as the hypogastric region; very little omentum remained; the pressure of this immense liver

Digitized by Google

no doubt had produced its absorption. On examining the mesentery, the glands were found much enlarged, and of a bright-red color; the remaining abdominal viscera were in a healthy condition; the epigastric and internal mammary veins were much enlarged, but there had not been the slightest effusion into the peritoneal cavity. On examining the thorax, the lungs were found to contain deposits, probably cancerous. The heart was natural; no lesion was found which could account for the sudden death. It is, indeed, a remarkable circumstance in this case, that, notwithstanding the cancerous disease of the liver, no pain was felt, nor were the functions of that organ interfered with. The supra-renal capsules were both diseased, and infiltrated with cancer.

DR. KEATING, who had attended the patient for some time, stated that the extent of the swelling in the abdomen had almost precluded the idea of an affection of the liver. The appetite of the man was enormous; the stools were solid, and of natural color and appearance. There was not the slightest trace of bronzing of the skin; even the peculiar hue of the countenance, met with in cancer, was absent. The supra-renal capsules were microscopically examined, and presented undoubted evidences of cancer. The patient had employed iodine friction over the abdomen, which he thought had reduced the size of the organ.

DR. MITCHELL spoke of the frequent absence of the peculiar color in cases of cancer, and suggested that there might be, as it were, two sets of cases, one with and one without this symptom.

DR. ADDINELL HEWSON was now attending a patient in whom he had diagnosed cancer of the liver, and whose complexion did not in any way indicate cancer.

Digitized by Google

WEDNESDAY EVENING, October 27th, 1858.

The President, DR. LA ROCHE, in the Chair.

Cancer of the Liver.—DR. ADDINELL HEWSON exhibited specimens removed from the body of Mrs. C., to whose case he had alluded at the previous meeting. He had visited Mrs. C. for the first time on the 1st of October, and found her in bed, exceedingly pale, weak, and emaciated, and was informed by her daughter that she had been suffering from diarrhœa for about four months, and that very recently the alvine evacuations had become bloody, and caused them alarm. She had rejected all nourishment from her stomach during the whole of her illness. Her tongue was very smooth and pale; the lungs and heart, on examination, were found normal; the pulse feeble and frequent, 140. On passing the hand beneath the bedclothing and over the abdomen, he was surprised to find this region tumid and bossilated, as though the intestines were distended by hard, scibulous masses of fæces; this hard, bossilated condition extended from beneath the ribs all across the abdomen, and below the umbilicus into the lower regions of the abdomen; the edge of this hardness was very nodular, and, by pressing on the attenuated integuments of the abdomen, the fingers could be passed under this border; the lower part of the abdomen was dull; this was especially marked in the right illiac fossa. The patient complained of no pain in the region of the tumor; she suffered occasional colicky pains when at stool; the alvine evacuations were about four per diem, thin, but not deficient in bile; the tinging with blood was found to proceed from hemorrhoids. The patient had never observed the tumor of the abdomen before the date of her present illness; she was fifty-eight years of age; had always been thin and pale; her parents lived to an advanced age; she did not know of either of them having died of cancer; she had lost two sisters with phthisis; she was a widow; had had two children, the younger about twelve years old. Her health had been failing ever since her change of life, (at fifty-two years of age,) at which time she lost her husband; since then she had been much reduced in circumstances; she had never had any uterine discharge, or trouble with her kidneys. She rallied somewhat under the use of stimulants, but died fifteen days after she was first seen by Dr. Hewson.

Autopsy twenty-two hours after death.—Rigor mortis well-marked; slight straw tint of surface; emaciation extreme. Abdomen—enormously distended; a hard, knobby tumor could be readily felt through the walls occupying the right hypochondriac and lumbar, the epigastric, and part of

Digitized by Google

the umbilical, and the left hypochondriac regions; on making the section of the walls much gas escaped, and about three quarts of fluid were found in the cavity of the peritoneum; the tumor was found to be of the liver, which was bound by old adhesions to the walls of the abdomen on the right; the organ itself was greatly enlarged, extending up under the ribs as high as the fourth rib; its surface was studded with cancerous masses, and similar masses were distributed through its structure; the portions unoccupied by them were in a state of fatty degeneration; the organ weighed, when removed, nine and a half pounds; the gall-bladder was much distended with bile; the stomach had been pushed over by the liver into the left side, and made to occupy an almost vertical position in the left hypochondriac and lumbar regions; it was healthy as to structure. Under the liver, in the right side, was found the colon, doubled on itself at the angle of the ascending and transverse portions, bound down by adhesions, so as to nearly obliterate the canal, and in the centre of these adhesions was found a depot of about a drachm of thick, greenish pus, with the walls of the gut so much attenuated that they gave way at one point; the alimentary canal, beyond this, was healthy; in the vicinity of this the peritoneum was studded with hard masses of the size of a pea; the same were found in the right broad ligament, which was bound to the cæcum; and under these, in the iliac fossa, another collection of pus, of about a drachm in quantity; uterus and ovaries were free from disease, and both kidneys were in a healthy state, although unusually pale. Thorax—there was about an ounce of fluid in the pericardium; the heart was healthy; the lungs appeared natural; they were œdematous and frothy, and at the apex of the right lung there was a little hard mass of the size of a shot; nothing could be found in this to indicate cancer; the masses in the liver were observed, on a microscopic examination, to be cancerous.

Ossification of the Splenic Artery.—The preparation exhibited to the Society by DR. HALL was removed from a man, aged seventy-eight, who died of phthisis, in the Pennsylvania Hospital. He had been a sailor all his life, of drinking habits, and was utterly broken down in constitution. He was over a year in the House, and at the time of his death was little more than skin and bone.

Prior to his death it was evident that the right brachial, with its branches, were ossified—this could be felt at once on passing the fingers over the course of the branches.

At a post-mortem inspection, the aorta, at and just below the curve, was found studded thickly with osseous scales. The brachial artery of the right side also contained calcareous patches, while the radial and ulnar arteries were in parts quite rigid with the new formation. (These preparations were shown to the Society.)

Digitized by Google

The splenic artery was ossified throughout its course; a lesion which is rare. Dr. Bristowe,* of St. Thomas's Hospital, reports a case of "A female, aged sixty-seven, dead from dry gangrene of the foot. The arteries of the thigh and leg were ossified. The splenic artery was ossified throughout. The spleen small and natural."

Morgagni, also, quotes the case of an old man, in whom "the aorta at its bifurcation was ossified, and the splenic artery, from its commencement to its entrance into the spleen, was considerably dilated, and consisted almost wholly of bone."

DR. PACKARD alluded to the fact that the term ossification was very vaguely used; true bone being among the rarest of pathological formations.

DR. GROSS did not agree with Dr. Hall that ossification of the splenic artery was a very unusual occurrence. He had met with it not unfrequently, more often in the male than in the female. In the male, indeed, all arteries are more frequently ossified, a fact which he had had opportunity of observing himself, and which, on inquiry, he had found borne out by several pathological anatomists in this country with whom he had corresponded on this subject. Dr. Gross then exhibited a specimen, of a stellate appearance, which he believed to be true ossification of the valves of the aorta of an ox.

Examination of Black Vomit.—DR. PACKARD read the following:—During the past summer I have had two opportunities of making microscopical examinations of specimens of black vomit.

One of these was given to me by Dr. La Roche, immediately after its ejection. Examined under a magnifying power of 360 diameters, were seen—

1. Epithelial cells of the squamous variety.
2. Bodies resembling epithelial cells in various states of distension, some apparently filled with coloring matter of different shades, from light yellow to black. A few of these were perfectly opake; many of the rest were highly refractive.
3. Some brownish-yellow, nucleated cells, about twice the size of lymph-corpuscles.
4. Some very small reddish cells which may, perhaps, have been altered blood-corpuscles.
5. Many fine granules.
6. A few quite minute oil globules.

---

* A Treatise on the Structure and Use of the Spleen. By Edward Crisp, M.D.; London, 1854, p. 150.

Digitized by Google

In one of the portions examined there were several masses of what seemed to be partly digested food.

The other specimen was taken from the stomach of a sailor who died, with all the signs of yellow fever, in the Pennsylvania Hospital. The power employed was 472 diameters.

1. Epithelial cells in vast numbers, arranged in masses. Very few of them were squamous; the immense majority were columnar, and ranged side by side.

2. A great many fat globules, of all sizes.

3. Free nuclei.

The liver of this patient was very decidedly fatty, both in its grosser characters and under the microscope.

The same degeneration was very marked in the liver of another patient in whose case a similar diagnosis had been made.

DR. S. HENRY DICKSON inquired whether any of the members had met with the ruptured capillaries which are described by Blair as present in black vomit. In an examination of black vomit made at Charleston none were detected.

DR. LA ROCHE, and several other members of the Society, stated that they had never met with them.

Fatty Degeneration of a Nerve, in a Case of Tetanus.—DR. PACKARD continued: I have also made an examination which may have some interest, as perhaps bearing upon the pathology of that very formidable disease, tetanus; not explaining it, but possibly giving a ray of light in regard to it in this particular case.

The patient was a man in whom, after an amputation of the forearm, sloughing of the stump had occurred, and subsequently tetanus. By the sloughing was laid bare a portion of the ulnar nerve, which was excised by Dr. Pancoast with a faint hope of arresting the symptoms. A portion of the excised bit of nerve seemed to the naked eye to be healthy, the rest was abnormally vascular.

The former, under the microscope, was proved to be actually in a normal state; the latter was throughout in a condition of well-marked fatty degeneration. Repeated examinations of various specimens placed the fact of this difference of state beyond a doubt.

It would be absurd to infer from this single fact that tetanus is always connected with local inflammation somewhere in the nervous system, for the degeneration was here probably an inflammatory change; but the only way to arrive at the pathology of so rare a disease is to carefully preserve every item of information, and it is only as such an item that I present this isolated observation.

Digitized by Google

DR. HEWSON stated some facts in relation to this case of tetanus, which he thought important in connection with Dr. Packard's remarks. The amputation had been performed by himself on the case, in the Pennsylvania Hospital, for a severe gunshot wound, which had caused extensive comminution of the bones of the forearm, and burning of the integuments of the arm. The amputation was of the circular form, and was performed about two and one-half inches below the elbow, the patient being placed under the influence of ether. Excessive inflammatory reaction ensued in the burnt surface, and a gangrenous slough followed, which not only involved the cuff of the stump, but the integuments of the arm considerably beyond the limits of the original burn. It was on the separation of this slough that the tetanus set in.

The portion of nerve removed by Dr. Pancoast lay partly in a pouch formed by an accumulation of pus beneath the integument, between the internal condyle and olecranon, and partly in sound tissue above. The latter was what Dr. Packard has mentioned as normal, while the former was what he has described as in a state of fatty degeneration. The patient lived some time (about ten days) after the operation, but did not seem to have been benefited by it.

Ulceration of the Larynx and Trachea; Death from Œdema of the Glottis.—DR. HALL presented, for Dr. Albert H. Smith, a larynx and trachea removed from Bridget Nolan, aged fifty, native of Ireland, a housekeeper, who entered the Pennsylvania Hospital October 18th, 1858. She stated at the time that she had had a cough for two years, having been attacked first with croup, of which she had had several attacks since. When admitted she was apparently in fine health, stout and ruddy; the only evidence of disease being an occasional stridulous inspiration. On examination of the chest, slight sonorous and mucous rales, with a whistling sound in the trachea, were found. After admission, she was observed to have a stridulous cough, coming on in paroxysms, and lasting several hours at a time, with violent dyspnœa. These symptoms continued without change until about two weeks ago, when she was attacked suddenly at midnight with suffocation, and, before she could be reached, was dead.

Autopsy.—The larynx was found completely closed, with an œdematous swelling of the glottis, both above and below which the course of the larynx and trachea was blocked up with tenacious mucus. From the glottis to the bifurcation of the trachea, principally upon the posterior wall, were numerous large, deep ulcerations, with indurated edges.

There was no reason to suspect any syphilitic taint, there being no evidence of it in any part of the body; the vagina, uterus, ovaries, and other organs, were carefully examined, and found healthy. She was a married woman, with a very respectable family of children.

Digitized by Google

DR. GROSS nevertheless inclined to the belief that the ulcerations were of a syphilitic nature, partly because there was no evidence of tubercle, which might account for the ulcerations, and partly because they were multiple and presented raised and indurated edges.

Rupture of the Spleen; Collapse of the Lung.—The Secretary presented, for Dr. J. C. HARLAN, a ruptured spleen, removed from William Gordan, aged eleven, who was admitted into the St. Joseph's Hospital early on the morning of October 15th, suffering from injuries inflicted by a recent accident. While playing in the street he was knocked down and ran over by a butcher's wagon, one wheel of which, he stated, passed over his abdomen and another over his chest. He complained of some pain in the lower part of the abdomen, just above the pubes, but suffered mostly from pain in the chest and difficulty of respiration. His stomach was very irritable, and could not be made to retain anything without great difficulty. A great swelling of the face and neck was obvious at the first glance, and on further examination was found to extend over the chest and abdomen, and to be evidently caused by an enormous effusion of air. No other injury could be discovered, and he expressed himself free from pain in the other parts of the body.

It was supposed that a rib had been fractured, and that the emphysema was due to a wound of the lung by a sharp point of the broken bone. The chest was not minutely examined, as the great pain and prostration forbade it, and indeed the emphysema was so extensive as to render anything like an accurate and satisfactory examination impossible.

Stimulants and opiates were administered, a sinapism applied over the epigastrium, and a bandage placed around the chest. The bandage gave great relief at first, but was afterwards removed, as the boy thought it increased the oppression. He reacted pretty well, and in the afternoon breathed rather more freely and suffered less. He slept at intervals during the early part of the night, but about one o'clock he was seized with a pain across the upper part of the abdomen, so violent as to cause him to scream aloud. It was relieved by large doses of opium and a warm mush poultice applied over the part, and he slept pretty well until morning. During the night a scrotal hernia was observed, which, it may be confidently stated, did not exist at the time of his admission, as the pain above the pubes led to a careful examination. It was probably a result of the continued pressure of the air effused into the abdominal parietes. It was reducible, but returned immediately when unsupported. The next day the pain in the abdomen continued, and was rendered supportable only by the administration of opium, and the constant application of warmth and moisture by the poultice. Toward evening he became delirious, and died between two and three in the morning of the third day after the accident.

Digitized by Google

Post-mortem examination.—The left lung was in a perfectly healthy condition. The right was completely collapsed and congested, but not wounded, and there was no fracture of the ribs, sternum, or clavicle, nor injury of the bronchi or trachea. The apex of the lung had been confined by an old pleuritic adhesion, which it seemed as if the sudden and violent pressure upon the chest had broken loose. The pleura itself was torn. In the abdomen there were no signs of general peritonitis. The small intestines, liver, and right kidney, were perfectly healthy. There was an effusion of blood in the left hypochondrium. The spleen was ruptured, and the left kidney, transverse colon, and pyloric extremity of the stomach were in a condition bordering on gangrene. As he passed clear urine, it must have been secreted entirely by the right kidney. The liver, though not injured, is worthy of inspection. The curious fissures sometimes observed in it exist here in unusual number. There are also a number of marks that have the appearance of cicatrices, and in one instance a small fissure may be seen at the end of a cicatrix, as though the remains of a large one partially closed.

A discussion arose as to the mode of accounting for the emphysema and the collapse of the lung, since no external injury of the chest had been found. On motion, the case was referred to Dr. Wm. Keller, to obtain additional particulars.

Case of Gangrene, Probably from Arterial Obstruction.—The following case, recorded by DR. HENRY HARTSHORNE, was presented through the Secretary: In October, 1857, I was called to see, with Drs. Halsey and Hazzard, a man of about forty-five years of age, of previously good health except asthmatic attacks, suffering, at the time of our visit, with gangrene of the left foot.

The history of the case was, briefly, as follows: While walking in the street, he was suddenly attacked with intense pain at the upper part of the thigh, somewhat deeply seated. This continued for many hours, obliging him to retire to bed. Within twenty-four hours from the time of the commencement of the pain, a marked coldness was perceptible in the limb affected. This increased gradually, with equally gradual diminution of sensibility in the foot, and, in three or four days, change of color, commencing in the toes and spreading slowly up to the ankle. No evidence whatever of erysipelatous or other form of inflammation in the foot existed. The temperature, sensibility, and appearance of the other limb were entirely natural. I saw him on the fourteenth day of the illness, and his death took place on the seventeenth.

The symptoms, at the time of our visit, were those of constitutional irritation, and moderate but increasing prostration, with blackness of the

Digitized by Google

whole foot and part of the ankle, and total insensibility of the foot. The most striking feature of the case, however, was the alteration in the arterial circulation of the limb affected. As was repeatedly ascertained upon careful examination by Drs. Halsey, Hazzard, and myself, the pulsation of the popliteal and femoral artery (that of the tibial arteries being imperceptible) was not only, as might be anticipated, feebler, but very decidedly and constantly *slower* than that of the corresponding vessel in the other limb. Its rate was, in fact, about *half* that of the other.

The death of the patient took place rather suddenly, with symptoms parallel to those of the attacks to which he had been subject, and which were described as asthmatic. No autopsy was allowed.

Having had the opportunity to make but one visit to him, my attention was not, at the time, called to the condition of his heart, otherwise some ground might be afforded for accepting or rejecting the only hypothesis which suggests itself to me to account for the occurrence and course of the case. This hypothesis is, that the so-called asthmatic symptoms were those of dyspnœa from cardiac disease; that, possibly, during a subacute exacerbation of endocarditis, a fibrinous mass had escaped into the aorta, and traveled as far as the femoral artery, upon which it acted as a plug. The irritation produced by its presence might account for the pain at the commencement of the attack. The suddenness of the patient's death, moreover, at an earlier period than was to be expected from the depressing influence of the gangrene alone, might, perhaps, have resulted from the consummation of the cardiac disease itself. The age, constitution, and habits of the patient, at all events, along with the train of symptoms, removed the case entirely from the category of senile affections, and as positively did the local conditions prevent the diagnosis of erysipelas gangrenodes. If, therefore, the hypothesis above stated be rejected, what theory of causation can be substituted for it?

Digitized by Google

WEDNESDAY EVENING, November 10th, 1858.

The President, DR. LA ROCHE, in the Chair.

Idiopathic Gangrene of the Groin.—A case presented by DR. ADDINELL HEWSON.—Dr. H. was called to see the infant of Mrs. D., residing in Hide's Court, on the 21st of October. He found the child a pale, feebly-nourished little thing of nine months, suffering from teething and diarrhœa; the latter had been annoying her, off and on, through the whole of the past summer, when she cut the two lower incisors; the upper incisors were still very deep, but the gums much swollen. She had been under the care of a practicing apothecary during the whole of her sickness. A few days before he saw her for the first time, she had been much disturbed by nausea and vomiting, and by an increase of the diarrhœa; the discharges on the napkin were very white and thin, quite watery; the abdomen, when she was first examined, was flaccid, soft, and nowhere tender on pressure; she voided her urine freely. The diarrhœa and sickness yielded readily to treatment; the former had nearly ceased at the end of the third day from the Doctor's first visiting her, when the mother noticed, in putting her to bed in the evening, that she was very fretful, flinching and crying, as from acute pain, when the right hip-joint was moved. On examining the groin of this side, she also observed a livid tumefaction, which she was confident was not there in the morning when she dressed her; this lividity extended from the anterior superior spine of the ilium along the groin to the vulva. On the following day it had much increased, and the child seemed in great pain, feverish, but much exhausted; there was hardness and heat of surface extending up to the umbilicus, and the centre of the morbid action was dark-brown, this color extending the whole length of the groin, and for a width of half an inch; there was no fluctuation, and the sensibility of the brown surface seemed to be diminished. The color here became rapidly darker, and in the course of four days the part was black, soft, and had begun to be separated from the surrounding structures, a considerable quantity of grumous blood escaping from beneath the slough. The child sank under the process of separation of the slough, and died on the 2d of November, so quietly in her mother's arms, that she was not aware of her dissolution at the time.

Autopsy, made thirty-two hours after death.—The destruction of tissue had extended through the subcutaneous cellular tissue, and the contrast of the marble-whiteness of the child's body with the black sphace-

Digitized by Google

lated parts was very striking; there was no incarcerated hernia or other local source found that could account for the disease. A dissection of the vessels in the groin was not permitted, an examination of the viscera of the abdomen being all that could be obtained; here everything was found in a healthy state.

DR. WOODWARD said that he remembered a case similar, in some respects, to that of Dr. Hewson. It occurred in Blockley Hospital when he was an Assistant-Resident in that institution. Measles had been endemic in the Children's Asylum, and many of the little patients subsequently suffered from severe bronchitis or pneumonia; after which a number of cases of *gangrena oris* made their appearance, all of which, so far as he recollected, terminated fatally. While this state of things existed, his attention was called by the nurse to a small, gray, depressed, gangrenous spot in the groin of a little girl, about six or seven years of age, who had apparently recovered completely from her attack of measles. In spite of treatment, this spread rapidly, and she died in forty-eight hours. At the time of her death an extensive moist slough occupied the whole of that groin as well as the mons-veneris and orifice of the vagina. The symptoms prior to her decease were those of extreme depression. A post-mortem examination was made, but, so far as he recollected, there was no marked lesion in any of the abdominal or thoracic viscera.

Constriction of the Pylorus from Hypertrophy of its Fibrous and Muscular Coats.—DR. DA COSTA presented, for Dr. Wm. Moss, a specimen of narrowing of the pylorus, with Dr. Moss's account of the case:—Mrs. M., aged forty, came under my care on the 20th of last September, at which time she had been suffering about five weeks from the following symptoms:—Pain at the pit of the stomach, not increased by pressure; a "dead," heavy sensation throughout the abdomen, and vomiting shortly after meals, the matter vomited consisting of the ingesta only, containing neither bile, glairy fluid, nor blood. For some months she had been subject to attacks of indigestion, and had been steadily losing flesh and strength; she complained especially of great weakness in her legs; her eyes were sunken and unnaturally brilliant, and the expression of her countenance was utterly despondent; she had a slight cough; her bowels were obstinately constipated; the tongue smooth and red; pulse 100, feeble and irregular. On physical examination, I found slight dullness at the apices of the lungs; heart's size and action natural; liver not enlarged; no signs of aortal aneurism, or of tumor in the abdomen, except the slightest possible resistance to the finger over the pylorus, unaccompanied by dullness on percussion; urine of healthy specific gravity and constituents; no pain on pressure over the spinal column.

Digitized by Google

The diagnosis arrived at by Dr. Da Costa and myself, more by exclusion than from any distinctive symptoms which the case presented, was, that there existed an obstruction at the pyloric orifice, not caused by cancer nor the result of ulcer at the pylorus. That the lesion was not an ulcer of the stomach, was clearly shown by the dull, heavy character of the pain, its diffusion over the abdomen, its not being increased by pressure, and the absence of blood in the matter vomited; while the non-existence of the symptoms of ulcer in the previous history of the case tended to prove that it was not likely that a cicatrix from a former ulcer could be the cause of the malady.

We inferred that cancer was not present, because, in the state of exhaustion to which the patient was reduced, we would have had, in addition to the actual symptoms, vomiting of glairy mucus and of the characteristic coffee-ground fluid of cancer, and, in all probability, the presence of a tumor perceptible to the touch.

As to what was the real cause of the obstruction, in the absence of all positive symptoms, we could only hazard a supposition. It might have been owing to a tumor pressing against the pylorus from behind; and since the pancreas was the only one of the neighboring organs of whose normal size we were not certain, it seemed not improbable, that the enlargement might be of that organ. Yet this was a mere supposition. It would have, to some extent, accounted for the numbness of the thighs, by pressure on the nerves; but the absence of any signs of a tumor invalidated it.

The history of the case may be recounted in very few words. The vomiting after meals was an almost incessant symptom, ceasing once only, on the 23d of September, without apparent cause, since it recommenced a couple of days afterwards under the use of the agent which I flattered myself was controlling it, hydrocyanic acid, to end only with the life of the sufferer. I was equally unsuccessful in combating it with creosote, bismuth, and the opiates.

On the 29th she was seized with severe lancinating pains under both patellæ, unaffected by pressure or motion, and accompanied by pricking sensations and numbness in the legs, with great difficulty in moving them. The pains gradually ceased, together with the pricking, but the loss of motion and numbness increased daily.

October 3d.—Tongue coated; increased pain in epigastrium, and acid eructations, which yielded to the employment of bismuth and sod. bicarb. During all this time the constipation was most obstinate, requiring the daily use of laxative enemata. Her extremities were cold; her pulse was scarcely perceptible, ranging from 110 to 130 beats in the minute, and she could obtain with difficulty a few moments of sleep.

Digitized by Google

On the 17th I first noticed that her mind occasionally wandered, so slightly and rarely, that perhaps this state may have existed for several days before it attracted my attention. The constantly increasing numbness and weakness of her lower extremities terminated in complete paralysis about a week before her death; the abdominal pains and vomiting increased in severity; she complained of headache and occasional febrile attacks, and during the last few days of her life her pulse became so faint and frequent that I could not count its beats. She retained her mental powers perfectly, with the exception of the occasional above-mentioned aberrations, until the time of her death, which took place on the 26th of October, about ten weeks after I first saw her.

Examination twenty-four hours after death.—Thorax, heart, and pericardium healthy; old adhesions of pleura over tuberculous deposits in apices of both lungs; small cavity in apex of right lung; the pleura and pericardium contained no fluid. Abdomen—adipose tissue of walls about three-quarters of an inch thick; the liver, spleen, pancreas, and urinogenital organs healthy, as were the choledoch and pancreatic ducts; gall-bladder empty; the stomach was collapsed, very slightly, if at all, enlarged, empty, and not thickened; its mucous coat was smooth, clean, not thickened, and presented no signs of congestion or of inflammation; the pyloric orifice was so narrowed that the finger could with difficulty be forced into it, and its mucous lining lay in folds, like the mouth of a bag; there were no traces of ulcers or cicatrices, and the narrowing proved to be due to a thickening of the submucous and muscular coats. The rest of the intestinal canal was healthy; there was about a teaspoonful of jellylike substance lying loose in the stomach near the pylorus, which, under the microscope, consisted of granular matter and a few epithelial cells; it was, I imagine, the thick beef-tea of which she had partaken shortly before her death. Nothing was found to explain the paralysis of the lower extremities, and I was not permitted to examine the brain or spinal cord, to some lesion of the latter of which it must doubtlessly be attributed. On dissection of the pylorus its mucous coat was unaltered, and easily detached from the subjacent coat; the fibrous and muscular coats were uniformly thickened, with none of the characteristics of scirrhus to the eye or touch; examined microscopically, the thickened substance was found to be composed of fibro-areolar tissue, containing formative cells and muscular fibres of organic life.

The absence of cancer-cells under the microscope, the uniformity of the enlargement, its softness to the touch, and the presence of tubercle in the lung, were sufficient evidences that the thickening was due, not to a cancerous deposit, but to hypertrophy of the normal constituents of the part.

The points which occur to me as most worthy of notice in this case, are, the impossibility of diagnosing with certainty a stenosis of the pylorus

Digitized by Google

dependent on hypertrophy of its submucous and muscular coats, and the exceeding rareness of this disease, or rather the rare mention which has hitherto been made of it.

The physical and rational signs of constriction of the pylorus, whether from mere hypertrophy of its coats or from a cancerous thickening in its first stage, that is, before ulceration or erosion of the mucous coat has taken place, and before the tumor has attained sufficient size to be perceptible to the touch, are identical; so that to the difficulty, so dwelt on by all writers on the subject, of diagnosing cancer of the pylorus in its earlier stages, we have superadded the utter impossibility of distinguishing between it and the lesion now under consideration.

As to the infrequency of this lesion, I can find but few writers, even among those who have especially studied the diseases of the alimentary canal, who seem to have suspected its existence. Budd, Chambers, Valleix, Grisolle, and Andral make no mention of it. Rokitansky (*Pathological Anatomy*) simply alludes to hypertrophy of the gastric membranes as one of the causes of stenosis. Habershon describes, what seems to me to be the same affection, a fibroid degeneration of the pylorus, a fibrous deposit commencing in the submucous cellular tissue, obstructing the valve and followed by muscular hypertrophy, with symptoms identical with those of cancerous obstruction.

Of the later writers, Bamberger* enumerates it among the causes of stenosis of the pylorus, carefully pointing out its exceeding infrequency. Hennoch† mentions it in exactly similar terms, and refers to Brandt on Stenosis of the Pylorus, and Dittrich, the latter of whom had met with it in adults and in children under one and a half years of age.

Cruveilhier, (*Anatomie Descriptive*, article ESTOMAC,) so distinctly asserts the existence of this lesion, that I may be excused for translating, in conclusion, the entire paragraph:—

"In the examination of several patients, who, toward the close of their life, had presented all the symptoms of stenosis of the pylorus, I found no other alteration than a very remarkable hypertrophy of the pyloric ring. I cannot decide whether this stenosis were cause or effect of the continual vomiting experienced by the patient; and I scarcely dare assert that these hypertrophies of the pyloric ring have been frequently shown to me as scirrhous stenoses, by persons but little versed in the knowledge of healthy and morbid anatomy."

---

* Uber die Krankheiten des Digestions Apparatus; Virchow's Handbuch.

† Klinik der Unterleibs Krankheiten.

Digitized by Google

WEDNESDAY EVENING, November 24th, 1858.

Vice-President, DR. STILLÉ, in the Chair.

Cancer of the Pylorus.—DR. HALL exhibited a specimen of cancer of the pylorus, removed from a patient of Dr. De Benneville of this city. For many years the patient had complained of a soreness and disagreeable dragging sensation in the region of the stomach. For a month or more before his death there was but little acute pain in the stomach, but rather a feeling of soreness after the eructation of food, which followed within an hour of its ingestion.

Post-mortem examination fourteen hours after death.—Rigor mortis not well marked; body extremely emaciated; right arm amputated at shoulder-joint, a good stump, with a firm and not extensive cicatrix. A large, hard tumor in the epigastric region, to be felt readily on palpation through the attenuated abdominal parietes. Head not examined. Lungs and heart perfectly healthy; liver also normal. Spleen—capsule thickened, and opake patches from old inflammation. Kidneys healthy. Stomach—normal as to position in cavity of abdomen and adjoining organs; nodulated masses upon the superior curvature of the organ; contents not unusual; color of membrane natural, save in the pyloric extremity, where there were streaks of bright injection; no mamillation of the membrane; no softening, as evidenced by tearing up of strips; thickness at pyloric extremity seven-tenths of an inch, at cardiac extremity one-fifth of an inch; cardiac opening not constricted. Pylorus open, the index finger could pass freely into it; the mucous membrane puckered at the orifice. Pyloric orifice three-tenths of an inch in diameter. Commencing at the pylorus was a scirrhous mass extending three and a half inches in the long axis of the stomach, and four and seven-tenths inches in the transverse or short diameter of the organ. At its highest point it had an elevation of three and one-tenth inches above the mucous membrane.

Under the microscope were found well-marked cancerous elements. The surface of the tumor had undergone serpiginous ulceration in spots; its general hue was light yellow, with here and there a yellowish-green shading. The pancreas was healthy.

DR. WOODWARD made a few remarks in connection with the *homologies of cancer*, which he regarded as a malformed new formation of connective tissue, as suggested by Wedl. One of the difficulties to the reception of this doctrine was the supposed absence of forms in embryonic development, approximating to those of cancer. It was stated, however, that in

Digitized by Google

the young connective tissue of fœtal marrow, cells were often observed approximating to the forms usually regarded as diagnostic of cancer. Diversity in shape, large size of nucleus, and vesicular nucleolus being clearly observable; cells with double and even plural nuclei, besides the characteristic many-nucleated marrow cell, are to be seen.

A specimen exhibiting these appearances was shown, from the marrow of the tibia of a fœtus of five and a half months.

Certain conditions present in fœtal marrow will, perhaps, account for the shape assumed by these young connective tissue elements. These conditions are evidently—1. The large quantity of blastema afforded. 2. The modification of shape by mutual pressure. If to these be added a consideration of the stage of the development of the tissue of the embryo, which is that with which cancer is thought homologous, the significance of such forms as these will be at once apparent.

Communication of the Appendix Vermiformis with the Ileum through a mesenteric gland; iron wires in the Omentum.—DR. PACKARD, in presenting these specimens, made the subjoined remarks: William Millbank, aged twenty-seven, a colored seaman, died in the Pennsylvania Hospital, June 26th, 1856, after an illness of about five months. When admitted into the institution, about two months previous to his death, he said that the doctors had told him that his disease had begun with typhoid fever; but his case was then evidently one of phthisis. The notes of its course are omitted as irrelevant.

Autopsy, fifteen hours after death.—Body excessively emaciated. Rigor mortis not very well pronounced. Brain softened; much serous effusion. Some tuberculous deposits existed around the optic chiasm, obliterating the fissure of Sylvius on each side. Lungs much congested throughout, exuding bloody or frothy serum on being cut into or torn; both apices healthy. The left lung was the one most diseased; the lower half of its bulk was converted into a yellow tuberculous mass, presenting several small anfractuous cavities, chiefly at its posterior part; just above this mass was some miliary deposit, of no great extent. In the right lung the middle lobe, and the lower portion of the upper, presented similar yellow masses; the lower lobe contained a great deal of miliary tubercle. Heart, liver, spleen, and kidneys, healthy. Intestines—in the ileum three of the agminated glands, of small size, were found ulcerated, and many others had an appearance as of cicatrization. The mesenteric glands were enlarged, especially about the ileo-colic junction; one of them had suppurated, and communicated with the interior of the caput coli, an ulcer existing in the mucous membrane; there were several other ulcers around the spot. The appendix vermiformis was adherent to the mesen-

Digitized by Google

tery from inflammation; a perforating ulcer existed at its extremity; an ulcer in the ileum, about one inch above the ileo-colic junction, had also perforated the intestine, and both these ulcers penetrated into the cavity of a large, suppurated mesenteric gland. Whether or not this cavity had communicated with that of the abdomen, could not be determined. In the tissue of the great omentum, between its layers, were found two bits of rusty and crooked iron wire, two and one-half and one and one-half inches long. How these foreign bodies were introduced I cannot pretend to say, unless the patient had swallowed them at some period of his life.

I would call attention to the seat of the tuberculous deposit in the lungs in this case, and would inquire whether the fact of enteric fever, with its accompanying bronchitis, having been the exciting cause, may not have had some influence in this respect? Is there any tendency observable to the formation of tubercle, after enteric fever, about the inflamed tubes, rather than at the apex of the lung?

Another point of interest about this case is the discharge of the pus from an inflamed mesenteric gland into the caput coli. Did the ulceration of the mucous membrane occur independently, or did the gland burst at that point as a bubo would perforate the skin?

The communication of the appendix vermiformis with the ileum through the cavity of a suppurated mesenteric gland, although very easy of comprehension, is not of frequent occurrence, so far as I can ascertain. Whether this had anything at all to do with the passage of the wires into the abdominal cavity or not, is to my mind very doubtful.

DR. KELLER reported that he had made inquiry about the case of rupture of the spleen, and collapse of the lung, read at a previous meeting of the Society, and that he had been positively assured that the most careful examination failed to detect a fracture of the ribs.

DR. STILLÉ suggested, that the laceration of the internal parts, unaccompanied by fracture of the ribs, might be explained by the elasticity of the thoracic walls, which in a child would readily yield, and this when the same force was sufficient to lacerate the resisting textures underneath.

DR. MITCHELL spoke of the evident effect which the abdominal walls and the intestines must exert in preventing ruptures of the internal organs during injuries received. They act, as it were, as air-cushions. Dr. Mitchell then related the particulars of a case of rupture of the liver. The patient, a bricklayer, fell from a considerable height and alighted on his feet. The shock was such that it tore the liver from its attachment, which was the more easily possible because the abdominal walls had been thinned, by a coarse truss, which was worn for the relief of a hernia. Thus the proper support of the abdominal viscera was wanting.

Digitized by Google

WEDNESDAY EVENING, December 8th, 1858.

The President, DR. LA ROCHE, in the Chair.

Wounds of the Heart.—DR. DA COSTA exhibited a specimen of a wound of the heart, and read the history of another, for which he expressed his indebtedness to Dr. S. P. Brown.

CASE I.—A boy, aged eleven, while running about the fields with another boy shot himself. He was immediately conveyed to his home, not far distant, and lived, although the ball had entered directly over the heart and perforated the lung, for three hours after the accident. During this time he spoke repeatedly, and completely exonerated his companion from any blame.

On post-mortem examination the ball was found to have struck the right ventricle near the origin of the pulmonary artery, then to have glanced off to the artery, and from there to have touched several places in the left lung, passing out between the fifth and sixth ribs in the axilla. The pericardium was wounded, and contained some fluid blood. There was also some in the pleura.

CASE II.—An Irishman, Peter Conway, received two stabs in a fight, in which he endeavored to separate the combatants. It was not noticed at the time by the by-standers, although he was observed to have suddenly grown faint. He did not speak after being stabbed; he became exceedingly faint, was placed in bed, and remained quiet until his death, which occurred three hours after the injury. The wound in front was at the lower end of the ensiform cartilage, about an inch from the median line on the left side. The wound on the back was three inches from the spinous process, passing between the ninth and tenth ribs. The wounds had been inflicted with an instrument about five-eighths of an inch in breadth.

On post-mortem examination, six hours after death, it was found that the knife had passed through the pericardium, and into the lower part of the right ventricle, occasioning a horizontal cut, through which a scalpel-handle could be passed into the ventricle. The direction of the wound on the back was diagonal, and had probably cut the intercostal artery. It had passed through the pleura, but had not reached the lung. The pleura contained about six pounds of fluid blood, the pericardium none. All the other viscera were healthy.

DRS. GROSS, LA ROCHE, and HALL, each cited cases in which the heart had probably been wounded without immediate death resulting. In the case referred to by Dr. Hall, a large butcher's hook had entered deeply

Digitized by Google

immediately over the region of the heart, and must from its direction have perforated the pericardium, and touched the heart. The patient recovered.

DR. ADDINELL HEWSON remarked that although the two specimens exhibited by Dr. Da Costa were exceedingly interesting, they were, as probably most of the members must be aware, far from being unique in their character. He had had occasion to investigate the subject very recently, and could cite many cases even more curious. Thus in Dupuytren's Essays could be found a number of such, including the famous case of the Duc de Berri, who was stabbed while leaving the opera by a man who stood behind him. The dagger was left sticking in the Duke's breast, and he himself drew it out, after he had been removed from the scene of the assault. Although the wound traversed the right auricle it did not prove fatal for several hours after its reception.

Thomas Bartholin mentions (Hist. Anat. Rar. Cent. 1, Hist. 77,) the case of a young man stabbed with a knife, in which the patient afterwards walked home some distance, and lived five days. Post-mortem examination revealed a small oblique wound of the right ventricle.

There are a number of cases on record in which persons have had the heart transfixed or penetrated with a stilet or darning-needle, and have entirely recovered. But perhaps the most extraordinary case on record is that reported to the Medical Association of the State of Alabama, by Dr. Chas. E. Lavender, of Selma, in 1850. It was in a student of medicine, aged nineteen years, who had been stabbed by a fellow-student; and from the account given by the Doctor, there can scarcely be any doubt that the knife penetrated the heart, (probably the right ventricle.) The patient lost over a gallon of blood, and recovered after an interval of twenty days' confinement. This extraordinary case is very fully quoted by Dr. Eve in his "Remarkable Cases in Surgery."

The direction of the lesion of the great central organ of the circulation in these and similar cases, was probably such as to separate, rather than divide the greatest part of the muscular fibres composing the wall at the wounded point, and hence probably the gaping was but slight, as has been pointed out by Dupuytren. This, no doubt, is also the reason why more cases have recovered from stabs, and penetrating wounds of the heart, from cutting instruments, than from injuries of a similar kind from gunshots. There are cases on record where shots have penetrated the cavities of the heart and yet death did not immediately follow. Dr. Randall, of Tennessee, has reported such a case, in a boy of fifteen years of age, who was accidentally shot by a fowling-piece, and survived the accident sixty-seven days. Three shot were found, after death, *lying loose* in the cavity of the ventricle, and two in the right auricle. The shot had entered the

Digitized by Google

heart about one-third of the way from its base to its apex; the wounds made by them were at a little distance from each other; they had all cicatrized, but the spots were plainly to be seen. (See *American Journal of the Medical Sciences* for 1829.) But the most incomprehensible case of all is that mentioned by Dr. A. Christison in the *Edinburgh Monthly.* (Ranking's Abst., 1853.) In this case a musket-ball was found in the left ventricle, covered with lymph, without any traces of wound of the heart that could be discovered. The man, a soldier, had been shot some time previous by a musket-ball in the left shoulder. On dissection the course of the ball could not be traced among the textures of the shoulder, but could between the second and third ribs; it passed obliquely through a narrow canal with cartilaginous sides, and then through the costal pleura. A large abscess occupied the cavity of the pleura, except superiorly where there was air. The lung was very much condensed and pressed toward the heart; an opening in its pleural covering showed the continuation of the course of the ball, and this was traced onward as far as the root of the lung, where they failed to trace it farther. Dr. Christison thinks that the ball could only have found its way into the ventricle by one of the pulmonary veins.

Incised Wounds of the Intestine.—DR. LENOX HODGE presented a specimen of wound of the intestine.

H. W., a colored man, was brought to the Pennsylvania Hospital on the evening of Friday, November 26th, with an incised wound of the abdomen. The wound was about three-fourths of an inch long, and situated half way between the umbilicus and pubes, and about one and a half inches to the left of the median line. During the twenty-four hours that he survived, he complained of pain throughout his abdomen, and vomited constantly. On Saturday emphysema appeared, and extended as high as the nipple on the left side, and nearly as high on the right; passed down as far as Poupart's ligament, and distended the scrotum to its utmost.

The post-mortem examination showed the peritoneal cavity to be filled with fæcal fluid and gas, and the small intestines to be wounded in three places. These wounds of the intestines were situated in the ileum; the lowest was about six inches above the ileo-cæcal valve, the other two were close together and about six inches higher up. Each of them penetrated through all the coats of the intestines; was about half an inch in length, and perpendicular to the course of the canal. They beautifully show the effort that nature makes in such cases, to close the wounds, by bringing the edges together, and everting the mucous membrane.

In the course of a discussion of the various treatments pursued in intestinal wounds, DR. GROSS stated, that he invariably adhered to the practice

Digitized by Google

of promptly returning the omentum, and sewing up the external wound, so as to prevent hernia, which he believed would be an inevitable consequence unless stitches were employed. The external wound will not unite without them.

DR. EDWARD HARTSHORNE referred to a case, published at length in the tenth volume of the *Medical Examiner*, in which, although no stitches had been used, a perfect union of the abdominal walls had taken place within ten days after the accident. The patient's death was caused by internal strangulation; a loop of the intestine was so bound down by bands, the result of the previous inflammation, as to have produced an obstruction of the passage. The wound was found, after death, to have entirely healed; the recti muscles were well united.

Tubercular Meningitis; Concentric Hypertrophy of the Heart.—DR. ALBERT H. SMITH presented specimens of tubercular meningitis, and of concentric cardiac hypertrophy.

William Anderson, aged forty-seven, colored, native of Philadelphia, stevedore, entered the hospital, on the 30th of November, 1858. He had always had excellent health until three weeks previous to his admission, when he was attacked with pains through his limbs and back, general malaise, loss of appetite, and constipation. These symptoms were soon followed by a chill, accompanied with a violent throbbing pain in the head, which continued without abatement until the patient applied for admission. Beyond this, nothing definite can be said of his history; he had no convulsions, nor at any time loss of consciousness or power, or impairment of the special senses.

When he presented himself, he was of full habit; not emaciated; he was sitting with his legs upon a settee, body bent forward, and head thrown slightly backward, which position, he mentioned, was the most comfortable he could assume; the expression of his face was one of extreme misery. Upon being questioned, he answered quite coherently, though with the short hurried manner of one in great pain. His pulse was full, though compressible, quite regular, sixty per minute; tongue thickly coated with white fur; mouth dry; respiration natural; skin dry, but not hot. He had abdominal tympanitis, with slight tenderness on pressure over the whole region; his bowels had been quite loose for three days. His pupils were contracted to a point, and insensible to light. Vision scarcely impaired; all other senses perfect. The most prominent symptom was the violent throbbing pain through the head, which was constant, and without remission. To use his own expression, "the misery in his head almost drove him crazy." He was greatly debilitated, having been carried to the hospital. There was no abnormal condition of either the heart or lungs apparent from physical signs.

Digitized by Google

He continued in this state, without any change, for four days, when his symptoms became more alarming. His pulse was more frequent, weaker, and smaller; skin cooler and moist. He grew very restless, with occasional maniacal jactitation, at times jumping out of bed, calling upon persons for help whom he imagined around him. His sensibility and consciousness diminished, and a partial delirium set in; though upon addressing him in a loud voice, he would give a coherent and rational answer. His head, previously drawn back voluntarily, because it afforded him some relief, was now rigidly fixed almost at a right angle to the normal axis of the neck; his pupils were still obstinately contracted; there was slight convergent strabismus. Involuntary urination occurred, but no action of the bowels except by injection. There was no apparent affection of the lungs or heart. These symptoms continued with increasing violence until the eighth of December, when he sank under the exhaustion, and died eight days after admission. There was no paralysis, nor muscular rigidity, except that mentioned of the neck.

Autopsy.—Encephalon: Dura matter greatly congested; arachnoid cavity containing about six ounces of clear serum; arachnoid inflamed, opake, and thickened, with slight deposit of miliary tubercle on the superior surface of the posterior lobes along each side of the longitudinal fissure; none that could be discovered at the base of the brain; pia mater violently injected over its whole surface; substance of brain firm and healthy in appearance; lateral ventricles containing some effusion, rather more than the normal amount; choroid plexuses congested. Thorax: Pleuræ free from effusion or adhesions; pulmonary surface studded with miliary tubercles; costal surface entirely free from them. The whole substance of both lungs was completely filled with the same deposit. The heart was small, about two-thirds the normal size; on opening it, the walls of the left ventricle were found to be concentrically hypertrophied, being, at the middle, ten lines in thickness, and reducing the cavity of the ventricle to the capacity of from six to eight fluidrachms; there was no other abnormal condition of this organ, nor of the great vessels. Abdomen: Peritoneum free from tubercular deposit; liver large and fatty; spleen filled with the miliary tubercles through its substance; none on its surface; all the other viscera perfectly healthy.

To be certain that the heart was not in a state of post-mortem contraction it was kept for several days, and attempts were made to dilate it with the finger, but it underwent no change.

Digitized by Google

WEDNESDAY EVENING, December 22d, 1858.

The President, DR. LA ROCHE, in the Chair.

Tumor of the Breast.—DR. S. W. GROSS presented a tumor removed by Professor Gross, from the left breast of a woman forty-three years of age, at the Clinic of the Jefferson Medical College. She is the mother of seven children, having been confined, for the last time, five years ago. Her menstrual functions are performed regularly. About seven years since, she first noticed a small, hard, inelastic lump in the upper part of the breast, which did not give rise to any inconvenience up to the middle of last summer, a period of six and a half years; it had increased to about one-half its present size, that of a large fist, when she began to feel sharp pains shooting through the tumor, which caused her a good deal of suffering. There was no enlargement of the subcutaneous veins, no lymphatic involvement, nor was the nipple retracted. The diagnosis was that of a fibrous tumor. The woman made a good recovery, the wound having united by the first intention. The structure of the tumor looked very much like that of the udder of a cow.

Dr. Packard, under the microscope, (magnified 472 diameters,) detected—

1. Portions of lactiferous tubes, lined with epithelium in some portions of their extent, and at others showing merely the tube of basement membrane.
2. Fibrous tissue.
3. Fibro-plastic cells, in not very great abundance.

Aneurism of the Subclavian Artery, Injected with Perchloride of Iron.—DR. FORBES, in exhibiting this specimen, remarked as follows:—

William Brunte, aged thirty-six, was a native of Germany, and a farmer by occupation. While working in hay with a pitchfork, on the twenty-eighth of August last, he felt something give way about his shoulder-joint on the right side. He had pain throughout the entire extremity of that side, which, after a few hours, localized itself under the middle of the collar-bone. A pulsatory tumor made its appearance over the middle of the clavicle, and on the twelfth of September he left the farm, and came to this city for counsel. His surgeon pronounced it to be an aneurism, and advised that no time should be lost in seeking further aid in view of an operation, as the tumor was now as large as a hen's egg, and increasing rapidly in size. Upon further consultation, it was concluded not to operate. The tumor grew rapidly, and ten days after his arrival in the city, he sought the advice of a German physician, who proposed to him

Digitized by Google

the injecting of perchloride of iron into the tumor as his only hope. This operation was accordingly performed; three distinct openings were made near the summit of the tumor, but what quantity of the perchloride of iron was injected I could not ascertain; nor could I learn what amount of hemorrhage occurred when these openings were made. Ten days after the operation of injecting was performed, the surgeon ceased his attendance, and on the following day the patient sent for Dr. Freeman, of this city, who, after repeated solicitations, and after being well assured that the German physician had ceased to attend, concluded to visit him.

The tumor was found to be larger than an ostrich egg above the clavicle, the margins of the three openings made for the purpose of injecting the perchloride of iron, were sloughing; there was no pulsation in any of the vessels of the limb; still it was warm, œdematous, and entirely deprived of sensation. The patient was quite anæmic from the hemorrhages which had occurred since the German physician had ceased to visit him. The first hemorrhage appeared, from the man's description, to have been a general oozing from the opening farthest from the clavicle, and was stopped by the application of a cold cloth. The second hemorrhage occurred some six hours later, and was only stopped by the patient fainting. He was ordered an anodyne, which was to be kept up; a little stimulus, with broth, and other liquid nourishment; and the cold to be constantly applied. The following day the patient was more comfortable. Acetate of lead, acetate of morphia, and tincture of digitalis alternately during the day, were ordered, and the broth diet was continued with the local application of a cold cloth wrung out of lead water and laudanum.

The following day the aneurism had increased very much in size. The patient was disturbed by a constant cough, and his sputa were tinged with blood, and at times a good deal of pus. He had another hemorrhage during the night, was very anæmic, and evidently much weaker. He was most carefully watched; but bleeding more or less every day, he gradually sank. On the third of December I was asked to see him. The tumor I found extended from the angle of the inferior maxillary bone on the right side to the acromion process of the scapula, and from near the spinous processes of the lower cervical vertebræ posteriorly to beyond the interclavicular space anteriorly. The head was pushed over to one side, and the patient was breathing with great difficulty. The three orifices which were made for the injection of the perchloride of iron had all merged into one large orifice at the summit of the tumor, through which orifice the aneurismal clot was now emerging and its surface undergoing decomposition. He complained a good deal of cough and of a sensation of oppression at the summit of the thorax on the side of aneurism—the tumor evidently pressed against the lung, the phrenic and the pneumogastric nerves, and the

Digitized by Google

trachea. In this critical condition, the breaking down of the clot so exposed to the external atmosphere would have caused death at any moment from excessive hemorrhage. The clot seemed to be pressed from below upward, not spasmodically, as if by the heart's action, but continuously and quite forcibly, thus causing it to protrude through the orifice at the top of the tumor, like a hernia, thereby preventing hemorrhage; yet there was at times a slight oozing of blood mingled with the pus of the breaking down clot. The whole tumor from base to summit was covered with small shreds of lint and thickly painted with collodion. Anodynes, digitalis, and a nourishing diet were recommended, and the patient was closely watched. He bled no more, but continued to sink, and died from exhaustion just thirteen weeks after he felt something give way in his right shoulder. Twenty-four hours after death an *autopsy* revealed the following condition of the parts:—

The tumor had collapsed but very little. An incision was made from above the hyoid bone to the pubic bone below. The innominate artery was traced up; the tumor was pressing upon its upper part, and likewise against the right carotid, compressing it against the lateral surface of the bodies of the lower cervical vertebræ, and thereby interfering materially with its functions, together with those of its two important neighbors, the pneumogastric nerve and internal jugular vein. The sac of the tumor was now opened, and the huge clot removed. The sac consisted only of the external coat of the artery thickened a little by inflammation. After the clot was removed, a *lacerated* opening about a quarter of an inch in extent was found to exist in the internal and middle coats of the third or last division of the subclavian artery, viz., the part existing between the external border of the scalenus anticus muscle and the inferior border of the first rib. The man had evidently ruptured the internal and middle coats of this artery in the exertions of tossing hay, as was demonstrated by the jagged appearance of the wound. The blood had forced itself out, and dissected up the external cellular coat of the artery, had extended down the axillary artery a short distance, and had proceeded upward posterior to the scalenus anticus muscle, as far as the bifurcation of the innominate artery, embracing all the branches of the subclavian, so that the first part of the vertebral, the external mammary, and the superior intercostal, and the whole of the thyroid axis were denuded of their external coat by the blood dissecting it off. The blood had dissected up so much of the external coat of the internal mammary artery, as to have formed a tumor as large as a hen's egg, which pressed against the pleura, and the upper and anterior part of the lobe of the right lung, causing it to break down, and giving rise in part to the pectoral symptoms so prominent a few days before death. The blood had also followed up the

Digitized by Google

branches of the thyroid axis toward the acromion and upward toward the thyroid gland, and had caused extensive pressure against the phrenic and pneumogastric nerves and the internal jugular vein, by its extraordinary dissection of the external coats.

There was no cephalic disease, and only in one spot anywhere was there the slightest sign of degeneration; this spot was in the aorta just at the giving off of the cœliac axis, where there existed a very small atheromatous deposit. The lungs were perfect except at the summit of the right lung, where the tumor had pressed. Had this man been seen in a few hours after the accident occurred, the artery could have been ligated a little above the lacerated wound, just at the margin of the scalenus muscle, with some hopes of success. The character of the lacerated wound was peculiar; it extended in the direction of the long axis of the vessel and not around it. It was on the anterior surface of the vessel, and was small in extent. The innominate artery was very short, and all the branches of the subclavian came off from its first portion before pasing beneath the scalenus anticus muscle. All these conditions of the patient indicate that had he been operated upon soon after the accident occurred, and before the extensive diffusion of blood, there would have been much reason to hope for the most favorable results.

Cancerous Stricture of the Rectum.—DR. ALBERT H. SMITH exhibited a cancerous stricture of the rectum:—

James Money, aged forty-one, laborer, native of Ireland, entered the Pennsylvania Hospital on the 18th of August, 1858, suffering with symptoms of intestinal obstruction. He stated that he had had an attack of intermittent fever ten years previously, since which time he had always been affected with constipation. Eighteen months ago he became so much worse, with distension of the bowels and inability to evacuate them without immoderate quantities of purgatives, that he applied for admission into the hospital, and was treated there for about two months, for constipation, at the end of which time he was so much relieved that he felt able to resume his work. Six weeks, however, after his discharge the trouble returned with renewed violence, and ever since he has been suffering extremely, shifting about from one practitioner to another, without any permanent amelioration of his condition, and on the whole growing gradually worse.

When admitted, he was pale and emaciated, with a haggard, care-worn expression of face. His abdomen was enormously distended, and gave a loud, clear, tympanitic resonance on percussion; the distension was attended with great pain; there was no special uneasiness referred to the vicinity of the rectum. He had had no fæcal evacuation, except by injec-

Digitized by Google

tions, for five weeks, purgatives having no other effect than that of producing vomiting. His pulse was weak, quick, and frequent; tongue pale and flabby; his appetite gone. On making a careful examination of his rectum there was found to be a constriction about eight inches up, beyond which a large-sized rectal bougie would not pass, though an ordinary stomach-tube passed readily, and gave free vent to a large accumulation of gas. By means of the remedies indicated, his sufferings were entirely relieved, and Dr. Pancoast, being then the attending surgeon, attempted to dilate the stricture by graduated bougies, but it was found impracticable, as the parts were hard, firm, and unyielding. He continued without change, except an occasional attack of violent distension, which yielded promptly to remedies, until about the first of October, when Dr. Norris, then on duty, considering it a case of a cancerous character, had it transferred to the medical ward. As I had just previously been moved into that ward, I was fortunate in being able to retain charge of the patient. At that time the stomach-tube could no longer be passed, a good-sized urethral bougie alone could enter. The attacks of distension now became more frequent, the abdomen enlarging enormously, and becoming tense, and hard. These attacks were accompanied with extreme pain and prostration; vomiting usually attended them, though never of stercoraceous matter. The emaciation increased, and the life of the patient was an agony to which there was seldom a remission. The size of the instrument that would pass the constricted position gradually diminished, until the small rat-tail bougies alone could be admitted; there was evidently a great tortuosity of the rectum, and no metallic instrument could be introduced.

On the 13th inst. he was attacked, as previously, with inability to defecate, great distension, and with intense agony, which very soon prostrated him. The usual remedies failed to give relief; the smallest-sized flexible catheter could not be made to pass the point of constriction. His strength gradually failed, anodynes in enormous doses produced no alleviation of his misery, and he sank under it the following morning.

Autopsy.—The appearance of the body was most striking; the head and both upper and lower extremities were wasted to the bone, while the trunk presented a resemblance to the old Greek amphora, the thorax being compressed to the size of a child's, and looking like a protuberance upon the spherical mass of the abdomen, which measured *more than five feet in circumference.* It had the firmness and resonance of a drum head. An incision was made over the sternum, carried down into the abdominal parietes, where the skin literally cracked before the knife as it was lightly touched. When the incision had reached about an inch above the umbilicus there was a sudden explosive report, with the

Digitized by Google

expulsion of fæcal matter and gas, and an immediate subsidence of the whole abdomen to about one-half its original dimensions. Examining for the cause of this I discovered that the colon lying across the abdomen had at this point given way, being no longer able to resist the distension from which the support of the abdominal parietes was now removed. Continuing the incision and exposing the whole contents, a most interesting condition was exhibited; the small intestines were in their normal position, though greatly enlarged; but the whole colon was loosened from its peritoneal attachment, the ascending taking a course diagonally to the left hypochondriac region, forming an acute angle, descending again over itself to the right iliac, from which it made a circular sweep into the pelvis to the rectum. There was no portion which could be called transverse.

FIG. 7. FIG. 8.

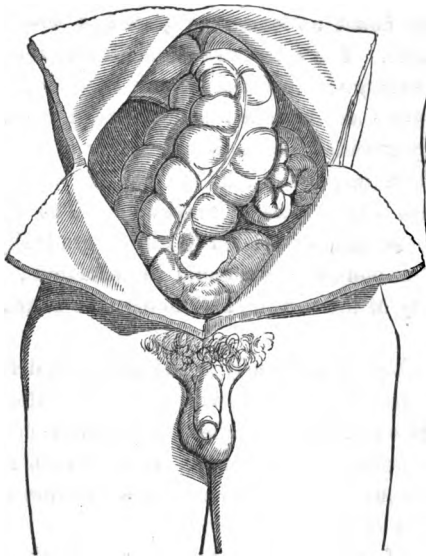

After the intestines had subsided considerably, the descending portion of the colon almost concealed the rest of the viscera, being throughout its whole extent enormously dilated, measuring at one point, even after the distension was removed, *eighteen inches in circumference*, and in no place less than fifteen. The peritoneum appeared healthy. About eight inches above the anus, in the rectum, was a stricture of the gut, at which, from the dimensions above stated, it narrowed down to about one and a half inches in circumference; (Fig. 8;) it was hard and cartilaginous to the touch On opening the bowel at this point the passage was found con-

Digitized by Google

tracted down to the size of a small quill, and immediately below the orifice toward the anus was a pediculated tumor about as large as a pea, of a firm texture, and rose-colored. Subsequent examination proved this tumor, as well as the coatings of the bowel at the constricted point, to be undoubtedly scirrhus. The coatings of the intestines were universally softened, tearing whenever any force was applied to them. There must have been more than two gallons of liquid fæces in the bowels. All the other viscera, abdominal and thoracic, were carefully examined, without any evidence of disease; not the slightest trace of cancerous deposit being found elsewhere.

Curiously Twisted Umbilical Cord.—DR. ROBERT P. HARRIS presented a spirally formed umbilical cord obtained, the day previous to the meeting, from a healthy primipara, delivered of a well developed male fœtus. This cord formed a continuous helix from the placenta to the umbilicus of the fœtus, in which there were between thirty and forty turns, each measuring (before the pulsation ceased) about three-quarters of an inch in diameter. Notwithstanding this spiral arrangement, the cord, when measured in a direct line, was about the usual length of this conduit when normally formed, reaching, after the expulsion of the child, from the umbilicus, up around the neck of the fœtus, down over its chest and abdomen, and to the placenta which was still within the uterus and firmly attached. In making traction to deliver the placenta the spiral portion within the vagina was necessarily elongated, or straightened out. The external portion not so pulled, which was presented to the Society, constituted, when fresh, a helix composed of twenty-eight spiral turns.

DR. KELLER remarked that twists and knots in the cord present many points for study. Knots in the umbilical cord may be of a simple or of a complicated nature. They may be of long existence before the birth of the child, or they may form during parturition. In the latter case they are produced while the child passes through a noose which is situated on the os tincæ, or twisted about the child's body. Thus a knot more or less tightly tied is produced which can immediately be loosened without leaving the slightest impression by which to indicate that it has existed. Those knots originating from the movements of the fœtus are often highly important to its existence, because if such a knot be drawn very tight the circulation between the fœtus and the placenta is diminished, if not entirely suspended. Sometimes, however, we meet with such knots, and even with those of a more complicated nature, which, by the impressions in the Whartonian jelly, evidently prove that they have been a long time present. A case of that kind occurred in his practice, on the 10th of March, 1858, the patient being a native of Switzerland. After her de-

Digitized by Google

livery of a healthy and stout girl, the umbilical cord presented a double knot resembling the figure 8, with deep impressions eight lines from the child's navel.

The lady, whom he had attended in confinement several times before, exhibited this abnormity for the first time.

In the course of some further obstetric remarks, Dr. Keller mentioned that he had recently delivered a lady of twins in whom he had found a perfectly movable xyphoid cartilage.

Report of the Committee on a Diseased Scapula. (See Proceedings of November 24th.)—The committee appointed to examine the scapula removed from a patient who had undergone amputation at the shoulder-joint, would respectfully report, that they considered the fragment lodged at the upper border of the glenoid cavity to be the acromion process of the scapula broken off and displaced downward.

This conclusion was arrived at accurately by comparative measurements, as follows :—

	NORMAL BONE. Inches.	SPECIMEN. Inches.
Length of spine of scapula . . .	$5\frac{6}{8}$	$4\frac{1}{2}$
Acromion process	2	$1\frac{1}{4}$

At the acromio-clavicular junction there were all the evidences of an articulation, such as a sac containing synovial fluid.

As to the change of form in the glenoid cavity, the committee are led to the conclusion that it was subsequent to the amputation, the statement of the surgeon amputating, that the glenoid cavity was healthy at that time, inclining them to this view.

HALL, HEWSON, PACKARD.

Digitized by Google

WEDNESDAY EVENING, January 12th, 1859.

The President, DR. LA ROCHE, in the Chair.

Pericarditis.—DR. GROSS exhibited a specimen of extensive pericarditis, affecting the whole of the cardiac portion of the pericardium. The masses of lymph hung on the membrane like delicate villi; some almost half an inch in length and an eighth of an inch in breadth. The left ventricle was slightly hypertrophied. No history of the case could be obtained.

Hypertrophy of the Muscular Coat of the Bladder; Occlusion of the Prepuce and Inflammation of the Kidneys and Ureters.—DR. GROSS exhibited a bladder, the muscular coat of which was hypertrophied:—

Thomas Snellard, twenty-one years of age, a native of Philadelphia, had been affected with incontinence of urine for the last fourteen years, and had not, during all that period, ever passed a continuous stream, the urine constantly dribbling away. This was attended with a dull, heavy pain in the pelvis, and a sharp lancinating pain in the lumbar region, which was most severe over the right kidney. Six years ago he received a wound in the sole of the right foot from a nail, and within a period of three years fourteen pieces of bone were discharged, leaving the foot very much contorted and deformed. During the past summer he was attacked with diarrhœa, but it was only five weeks previous to his death that he was confined to his bed, during which time his bowels were almost constantly relaxed, and he became extremely emaciated. His general health was always delicate; several of his aunts and uncles had died of consumption. He would never permit an examination of his bladder or penis, so that the cause of the vesical trouble was unknown to his attendant, Dr. McQuean. The cause of death was extreme exhaustion produced by the diarrhœa. The autopsy was made on the third of January, twenty hours after death, the body being much emaciated.

The muscular coat of the bladder was hypertrophied, the organ being a beautiful specimen of what is known as the columniform bladder. The ureters were enlarged and their mucous lining was the seat of a fine capilliform injection, and in some places of softening. The right kidney was enlarged, and contained about two ounces of pus, its fibrous investment being in some places opake and firmly adherent to the organ. The left kidney was somewhat smaller than natural. In searching for the cause of these effects it was found that the prepuce was adherent to the glans-penis and that a very small opening was all that permitted the escape of urine. Just behind this a large pouch had formed capable of containing a drachm of

Digitized by Google

urine. This state of things, which could have been easily remedied, had never been suspected during life.

Hernial Dilatation of Bladder; Dilatation of Ureters from Stricture of Urethra.—DR. LENOX HODGE exhibited a hernial dilatation of the bladder:—

J. McC., aged sixty-four years, had had stricture of the urethra for more than twenty years. He had an almost constant desire to urinate, could pass but a few drops at a time, and was in the habit of making violent straining efforts, so much so as to cause prolapsus of the rectum, and extravasation of urine into the cellular tissue of the scrotum. He died in the Pennsylvania Hospital on the twenty-sixth of December.

Upon making the post-mortem examination we found a dilatable stricture of the urethra, extending from just behind the glans backward about eighteen lines, and a cartilaginous stricture about six lines long at the membranous portion, where ulcerations through the walls of the urethra were discovered. The muscular walls of the bladder were excessively hypertrophied, and the cavity extremely small; at the upper and posterior part of its right side was a hernial dilatation equal in size to that of the bladder itself; the walls of this dilatation were very thin, and consisted simply of mucous membrane, and thickened peritoneal covering. Each of the ureters was dilated to the size of the urethra. The kidneys were healthy. There was an osseous deposit about six lines in diameter in the spleen, but none in the heart or arteries.

Meningitis in a Patient who had had Delirium Tremens.—DR. LENOX HODGE presented a specimen of arachnitis. The brain was deeply injected throughout; the arachnoid was thickened and opake; its cavity contained about six fluidounces of serum, while the sub-arachnoid space was nearly or entirely empty.

W. T., from whose body this brain was taken, was admitted into the hospital on the fifth of January, for a fracture of fibula. Being an habitual drunkard, the symptoms of delirium tremens soon appeared, became complicated with those of meningitis, and he died on the evening of the eleventh.

DR. STILLÉ inquired whether there had been any symptom indicatory of the commencement of the inflammatory disease, and also whether the delirium was positively that of mania a potu. Had the patient the hallucinations peculiar to delirium tremens?

DR. HODGE replied that the patient was known to have been a hard drinker, and was said never to have consumed less than a pint daily. He had had hallucinations from the first, although he evinced no fear, and spoke of never having had delirium tremens.

Digitized by Google

DR. STILLÉ felt by no means satisfied that the man had had delirium tremens. Persons are often supposed to have delirium tremens who have in reality inflammation of the brain. Men are admitted into a hospital in whom after accidents, or otherwise, delirium is a prominent symptom. They come from a class of population who all drink more or less, and this fact is deemed sufficient to make out a diagnosis of delirium tremens. Many also are supposed to be insane, who are in reality laboring under meningitis. It becomes thus of the greatest practical importance to distinguish the delirium of inflammation of the brain from that produced by other causes.

DR. GROSS thought that delirium tremens might give rise to inflammation of the meninges. It did not seem to him of such great importance, as regards the treatment, to diagnose an inter-current meningitis. Depletives could in neither case be employed; anodynes would be the best remedies.

DR. HEWSON agreed with Dr. Stillé as to the overrating of the occurrence of delirium tremens in hospitals. He referred to the fact that meningitis was not a rare cause of death in the hospitals of Paris, while it is well known that delirium tremens is an affection there not often met with.

DR. PACKARD, alluding to the post-mortem appearances in delirium tremens, said that two cases occurred when he was resident in the hospital, in which congestion supervened with a fatal result; at least, this condition was detected by post-mortem examination in one of them, and the other case was remarkably similar. Both were in veteran drinkers; both had lasted somewhat over a week; in both there was great depression of spirits and dread of death, and extreme irritability of stomach. In both the symptoms were ameliorating, when suddenly violent convulsions, with screaming and frightful delusions came on, and proved fatal, in one case in twenty minutes, and in the other in four hours.

An autopsy upon the former showed congestion of the dura mater, pons varolii and choroid plexuses, and a good deal of effusion beneath the arachnoid. No important phenomena were noticed in the other viscera, except patches of inflammation on the inner surface of the stomach.

Strangulated Hernia; Omentum Hypertrophied and Mistaken for a Diseased Testicle—DR. ADDINELL HEWSON exhibited a portion of omentum which he had had occasion to remove in an operation for strangulated hernia about ten days previously. The specimen was somewhat curious in itself, and the circumstances attending the case made it of peculiar interest. The patient from whom it was removed was a

Digitized by Google

German, aged about thirty-eight years, who had been the subject of a scrotal tumor for over two years. When this tumor first made its appearance, the patient's family physician supposed it to be an omental hernia. Subsequently the presence of a portion of intestine was recognized as composing a part of the tumor. This became strangulated, and two surgeons saw the case, but failed by the taxis to effect its reduction. As, however, the symptoms were not then urgent, they postponed operating, and in their absence the intestine returned. This all happened about six months after the first appearance of the swelling in the scrotum. The scrotal tumor, however, remained, and had increased much in size since its first appearance. It was hard, nodular, irregular in form, although somewhat pear-shaped, and presented unmistakable signs of the existence of fluid in its interior.

The patient then consulted, but at different periods, two other surgeons, who gave their opinion that his case was one of hernia, complicated with diseased testicle, and he was tapped three times by two of the four surgeons who had then seen him, for the removal of the fluid contained in the scrotum. The quantity drawn at either of these operations never amounted to more than a drachm or two, and was clear and straw-colored. The patient wore a truss very constantly from the first appearance of the hernial protrusion of the intestine, but in spite of this the gut again became incarcerated on two different occasions, and on both these occasions after it had resisted all efforts at reduction with the taxis, it returned of its own accord. In the former of these attacks it was incarcerated twenty-four hours, and in the latter about seventy hours, but at neither time were the symptoms urgent; there was never any stercoraceous vomiting.

On the occasion on which Dr. Hewson operated, the symptoms of strangulation had lasted over seventy-five hours, and the indications for the operation were well marked. The scrotal tumor was then large, about four inches in diameter, pear-shaped, and smooth, having lost the irregular form which it had possessed, and on opening the sac, the large mass formerly supposed to be a tumor of the testicle, was found to be a portion of omentum which had undergone fatty hypertrophy, and was adherent at one point to the coverings of the testicle.

The edge of this portion of omentum was very nodular, and formed a complete ring around the intestine. Some of the masses of fat were here as large as the testicle. Dr. Hewson remarked that it could thus be seen how readily a mistake could be made under such circumstances, especially as the imperfect English of the patient could not aid much in supplying the facts or the history of the case so necessary for accuracy in the diagnosis.

Digitized by Google

Fatty Liver.—DR. HALL exhibited, for DR. HOYT, a fatty liver removed from the body of a man aged fifty-two, who had been subject to attacks of bronchitis and of jaundice. The bowels were habitually constipated, and the stools dark and offensive. Ten days prior to death there was incessant vomiting. On post-mortem examination, the lungs presented no evidence of tubercle, but exhibited evidences of having been affected with bronchitis. The liver was markedly fatty; the other viscera were healthy. The intestines and peritoneum were deeply dyed with bile.

WEDNESDAY EVENING, January 26th, 1859.

Vice-President, DR. STILLÉ, in the Chair.

Fibrous Tumor on the Walls of the Abdomen.—DR. GROSS exhibited a tumor, partly of a fibro-plastic, and partly of a colloid nature:—

E. H., eighteen years of age, first noticed, thirteen months ago, a movable, firm, inelastic tumor, about the size of a hen's egg, just underneath the skin of the abdomen to the left of the umbilicus. During the early part of last summer it had increased to the size of a large orange. It grew from above downward, was not accompanied with enlargement of the subcutaneous veins, and did not give rise to pain or any inconvenience. At the time of the operation the tumor was about nine inches in length, of a solid and inelastic feel, and slightly movable. The linea alba was curvilinear, having been pushed over to the right side. The general health of the patient had always been good. On the twelfth of January the tumor was removed at the Clinic of the Jefferson Medical College, chloroform having been administered. It was found to be very firmly adherent to the muscular structures of the abdomen, which were atrophied and spread over its external surface. Great care was required to detach it from the transverse fascia. The main arterial supply was at its lower portion, from an enlarged branch of the superficial epigastric, which required a ligature. Several points of the interrupted suture were applied to the opposed sides of the muscles, and to the integument. These, with adhesive strips, a compress and roller, constituted the dressings. At the present time the wound is nearly healed.

Examined by Dr. Packard, under a magnifying power of 472 diameters, there were seen—

1. Colloid masses of variable size, generally irregularly oval in shape; outline dark; contents very slightly granular, and showing bright oval spots like nuclei clustered together.

Digitized by Google

2. Exquisitely fine pale granular cells, nucleated, with double vesicular nucleoli; often elongated.

3. Coarser cells darker colored, with large nuclei, sometimes with many nuclei. These cells were arranged in masses, with fine fibrous tissue intermixed.

4. Very fine fibro-plastic cells, with large nuclei, and one or more nucleoli.

Myeloid Tumors of the Abdomen, involving the Head of the Pancreas; Perforating Ulcer of the Stomach.—DR. DARRACH presented, for Dr. Levizey, specimens of myeloid tumors, with Dr. Levizey's account of the case. The case from which the accompanying specimens were removed was a patient of Dr. Hiram Corson, of Montgomery County, who has furnished the following notes of the case. The abdominal distension had during life been recognized as caused by the pancreatic tumor.

George Cramer, aged twenty-three, who had always enjoyed good health, with the exception of an attack of intermittent fever about two years ago, began to be slightly jaundiced in June last, and about that time discovered a small tumor of the size of a hickory-nut in the right iliac region. The jaundice steadily increased, but he continued to work up to August, when the lump became irritated by the ends of the sheaves while he was feeding a thresher. His physician directed him to poultice the tumor, and in a few days plunged a lancet into it, supposing it to be an abscess. Poultices were continued two weeks longer, and occasionally the swelling was probed, yet there was never any discharge from it.

The patient still continued to work until October, when he was treated by another physician for two weeks, with mercurials for disease of the liver. Then he came under Dr. Corson's care, who made the following note of the case on November 9th, 1858:—

He is deeply jaundiced; has a tumor in the right iliac region as large as a big orange—lobulated and solid; skin over the tumor discolored in spots, being red and purple, with the fine branches of blood-vessels ramifying over patches of it; the cicatrix of the puncture is a little elevated, with a very fine skin over it, which seems as though it were not connected with the parts below; the right side over the liver is larger than the left; dullness a little higher than usual on this side of the thorax; on a level with the umbilicus, and near to the lower margin of the liver, is a distinct, hard body, giving no resonance, though there is a narrow line of resonance between that and the liver. The other tumor appears to be entirely external. He complains much of the left knee; there is great pain at the inner condyle, with some swelling just above it; the urine is very dark, and colors muslin a deep yellow. He is costive, with no appetite, and gets

Digitized by Google

but little rest. The mercurials were continued, with opiates at night, and blisters over the internal tumor and region of the liver, and a cathartic pill occasionally. His stools are light-colored.

November 27th.—Stopped the mercurials a week ago on account of sickness and loss of appetite, which has since returned; the bowels have been moved once or twice daily; blisters have been well kept up, and there is a lessening of the fullness over the liver; urine unchanged; skin very yellow; external tumor double the size and greatly mottled; left knee still painful, and swollen on the inside. He takes but little nourishment, but has not vomited since he was first seen; sleeps well under one-quarter to one-half a grain of morphia; he cannot leave the bed; is much emaciated; has a full pulse of a 104 at all times.

December 5th.—Patient is better; skin is more natural; pulse, which has been 104 for weeks, is now only 96; tongue clean and natural; thirst for cold water very constant; with a good appetite. Ordered no medicine but morphia at night; bowels moved every day; and the stools are of a much darker color.

1859, January 1st.—Appetite voracious for the last two weeks; permitted him to eat as much and what he pleased; pulse 104; external tumor growing rapidly, and covered with fine, vermilion-colored branches of blood-vessels, in patches; the tumor in the abdomen can now be distinctly seen, elevating the parietes for about three inches.

January 16th.—Appetite still inordinate; complains of much pain in the knee, but sometimes has pain in the abdomen, and then the knee is easy; sleeps pretty well; bowels moved once or twice daily; is frightfully emaciated.

January 22d.—For the last two days he has been quite easy, but died at twelve o'clock to-day. About twenty hours before death he had inward spasms, with difficult breathing, and seemed to suffer very much.

Autopsy twenty-four hours after death. Body excessively emaciated; the external tumor in the iliac region was found to extend from a little above the anterior superior spinous process of the ilium to the pubes, and toward the middle of the abdomen about four inches across.

In dissecting up this tumor it was found to be resting upon the external oblique muscle, and adherent only by connective tissue to that structure. On making a section of this growth an appearance similar to that of soft marrow was presented, with here and there patches of a pinkish hue. Under the microscope this structure was found to consist of fat, with other cells, characteristic of myeloid tumor, (as described by Paget.) Some of these cells were shown, by means of acetic acid, to contain a nucleus, nearly filling the cell, and with one or more nucleoli.

The internal tumor, which had been recognized through the integu-

Digitized by Google

ments, was found occupying a part of the umbilical and right hypochondriac regions. It was attached along its lower margin to the transverse colon, above and posteriorly to the duodenum; the latter was found very much thickened. This tumor also involved the head of the pancreas, and was adherent to the omentum and surrounding structures. Examined by the microscope it presented the same appearance as above mentioned. The right lobe of the liver was found enlarged, very much congested, and infiltrated with bile. The gall-bladder was distended to two or three times its natural size, and filled with bile; its duct being large enough to admit the index finger with ease. This distension was probably caused by the pressure of the pancreatic tumor.

Firmly attached to the lobus Spigelii was found a third tumor, about two inches in diameter, and of a much darker color than either of the others, but microscopically the same.

The consistence of the pancreas was denser than normal. Upon opening the stomach an ulcer, which had perforated all of its coats, was found upon its posterior wall, a little below the lesser curvature, and nearly midway between the cardiac and pyloric orifice. An enlarged gland upon the outer surface of the stomach, and near the ulcer, acting as a valve, probably prevented any escape of fluids into the cavity of the abdomen; the patient never having shown any symptoms of peritonitis, and no evidence of the same was discovered upon dissection.

The kidneys and spleen were very much congested, but presented no other abnormal appearance. The knee was not examined, but from the symptoms of the patient, it may fairly be inferred that the same disease existed in the inner condyle. Heart and lungs healthy. Brain not examined.

DR. DARRACH spoke of the views of Paget and Lebert, who compared myeloid tumors in their structure to the marrow of bone. Paget refers to a tendency shown by them to occupy the same seat as epulis. Dr. Darrach thought that in this case the tumors had formed previous to last June, and caused the jaundice by pressure. The disintegration of the liver-cells may perhaps have had something to do with the death.

DR. GROSS spoke of the equivocal position of myeloid tumors in nosology, and expressed a belief that they would be ultimately placed among encephaloid growths. The ulcer in the stomach, he thought, partook of the same character as the mass in the pancreas. He moved that the specimen be referred for examination to a committee.

Double Pregnancy—one Tubal, the other Uterine.—DR. PACKARD presented a specimen of tubal pregnancy, sent to Dr. Hodge in 1849, by Dr. Craghead, of Danville, Virginia:—

Digitized by Google

The woman was a negress, aged thirty-five. She had had symptoms of an ovarian tumor; these suddenly became aggravated by the occurrence of collapse, and she aborted, discharging a well-formed fœtus of somewhat over three months. Two days afterwards she died.*

At the post-mortem examination, "the whole abdominal cavity was found filled, anteriorly, with coagulated blood, and posteriorly with serum, which had proceeded from the rupture of some of the vessels of the left Fallopian tube, now greatly enlarged, and converted into a membranous sac, containing a fœtus of the same size as the one delivered *per vias naturales.*"

Intracapsular Fracture of the Neck of the Femur; Fracture of the Trochanter Minor.—DR. LENOX HODGE exhibited an intracapsular fracture of the femur:—

H. F., aged seventy years, having fallen while going down the stairs of the Merchants' Hotel, fractured the neck of his femur, and was admitted into the Pennsylvania Hospital, on the 11th of December, 1858. He lived for five weeks and three days, and died from the effects of a diarrhœa on the 18th of January, 1859.

An autopsy showed the fracture of the neck of the femur to be within the capsule, except for a short distance at one point. The trochanter minor also had been fractured at its base. This last had united, and was surrounded with callus, though not perfectly consolidated; in the other case there had been no attempt at union. The specimen thus exhibits at once the difference in the action of nature when the fracture is intracapsular and when it is not.

Inguinal Hernia; Death from Peritonitis.—DR. JAMES HUTCHINSON, in presenting the specimens, said:—James Mackay, aged twenty-seven years, had been the subject of a reducible hernia in his left groin for a number of years. About the close of November, while engaged in lifting heavy barrels, it became strangulated, and after suffering for twenty-four hours he applied to a surgeon, who placed him under the influence of chloroform and succeeded in reducing it by taxis.

Ever since the man has suffered from severe pains in his abdomen, accompanied with vomiting and constipation. He entered the hospital six weeks after.

At the time of his admission into the hospital a small firm tumor occupied the inguinal canal, and some fullness was observable in the course of the cord below. His pulse was seventy-two, and even during the

* Case reported in Am. Journal for 1850.

Digitized by Google

paroxysms of pain it never at any time exceeded ninety. The features wore a pinched expression. He vomited incessantly. His bowels were readily acted upon by enemata, which invariably afforded relief, and which brought away large quantities of fæcal matter, which was on one or two occasions ribbon-shaped.

During the past week his symptoms had decidedly improved. The vomiting had entirely ceased, and the pain was present only at rare intervals. Suddenly, on Sunday evening, he was seized with the signs of peritonitis, and death took place in a few hours.

An autopsy was made eight hours after death. The abdomen was somewhat distended with gas which had escaped into the cavity of the peritoneum. Upon cutting down upon the course of the cord, a small piece of omentum was found in the inguinal canal; it was, however, not at all strangulated. The abdomen, when opened, was found filled with fæcal matter, which had escaped from the jejunum. The omentum was united to the abdominal parietes, just outside of the internal ring, and bound down with it a portion of the small intestines, so diminishing its caliber that a large-size urethral bougie could hardly be passed through it. Just above the constricted portion was a small ulcer, by means of which the perforation had taken place.

DR. GROSS gave a further history of the case. He had succeeded in reducing the hernial tumor, although it had been strangulated for several days, by placing the patient under one grain of morphine and employing chloroform. The man was in good health for three weeks afterwards, when he commenced to complain of some abdominal tenderness, for which he was sent to the hospital. Dr. Gross further stated that since the introduction of anæsthetics he seldom used the knife, even when strangulation had existed for thirty hours.

Digitized by Google

WEDNESDAY EVENING, February 9th, 1859.

Vice-President, DR. STILLÉ, in the Chair.

Pseudo-Membranous Laryngitis in an Adult.—DR. ALBERT H. SMITH presented a specimen of pseudo-membranous laryngitis, in which the false membrane had been moulded into a cast of the trachea and ramifications of the bronchi.

Louisa Jones, aged twenty-two, single, native of Canada, domestic, was admitted into the Pennsylvania Hospital, December 23, 1858, with chronic bronchitis and amenorrhœa. She had had a cough for about three months, not very severe, and not increasing; she suffered with violent headaches, and had not menstruated for four months. When admitted, she complained of pain in the chest over the sternum; of headache; coughed considerably, and expectorated tenacious mucus; had mucous râles in the lower posterior part of both lungs, with sonorous and sibilant râles above and in front; percussion was normal over the whole chest. There was no marked emaciation; her appetite was tolerably good. She slept badly, but had no night-sweats.

She was put upon treatment for the bronchial affection, and also in reference to the restoration of her menses. She improved considerably in her general health; increased in flesh, her appetite improved, and the chest symptoms diminished, though there still remained some sonorous and mucous râles.

On the nineteenth of January, she complained of great soreness of her throat, with difficulty of swallowing, which had been coming on for several days; but as she had frequently had attacks of the same kind, she thought it would pass away, and did not mention it. On examining the throat I found considerable enlargement of both tonsils, the right being much the larger. The usual means were taken to reduce the inflammation: the tonsillitis appeared to be running through its regular course. The day following this attack she menstruated. On the twenty-first, the swelling had increased; she swallowed with great difficulty, and at times had dyspnœa, although not violent. The tonsils almost occluded the pharynx and fauces; they were still hard. A lancet was plunged into them, but no pus escaped. The chest symptoms were in no respect changed. On the twenty-third, the difficulty of breathing had increased; the tonsils completely closed the fauces. A very deep incision was made with a scalpel into the substance of each tonsil; a free flow of blood took place, but no pus. There was still no increase of the physical signs in the chest, so far as could be detected on careful examination. In the evening, she told

Digitized by Google

me she felt much better; her breathing was much more free, and she had swallowed some soup. I did not at this time examine her lungs, as I had thus far had no reason to suspect anything more than a severe tonsillitis. About three hours afterwards, while I was absent for a short time from the hospital, my colleague, Dr. Hutchinson, was called to her with the statement that she was suffocating; he went, but before he reached her she had expired. Nothing could exceed my surprise, on returning an hour later, than to be informed of her death.

Autopsy, made eighteen hours after death.—The trachea and œsophagus were cut across the middle and carefully dissected up as far as the posterior nares; the tongue and pharynx were removed with the tonsils. These last were found enlarged so much as to close almost entirely the air-passages, the right being as large as a walnut. Lining the pharynx posteriorly to the tonsils, and resting upon them, were large flakes of membranous exudation, at least one-sixteenth of an inch in thickness; they could, however, be removed with great facility. Passing downward, we found the upper surface of the epiglottis invested with the same exudation, and a band of firm membrane passing from it to the pharynx posteriorly, and preventing it from closing. The under surface was also coated with exudation, and on opening the larnyx and trachea, we noticed a continuous membrane investing the whole of the larynx, becoming in the trachea a perfect tube-cast that could be readily separated from the mucous membrane, which was highly injected. On further examination of the portion of trachea which had been cut off, this cast was found to extend, without any interruption or break, into the secondary ramifications of the bronchi.

The lungs were entirely free from tuberculous deposit, but slightly emphysematous above; the other organs of the body were perfectly healthy.

Case of Sanguineous Apoplexy of Ventricles and Subarachnoid Space.—DR. ALBERT H. SMITH presented a specimen of apoplexy.

Ann Jones, aged seventy, colored, native of Philadelphia, cook, was conveyed to the Pennsylvania Hospital, on the afternoon of January 29, 1859, by two policemen, who had found her in the street in a state of insensibility. As was afterwards learned, she was a woman of remarkably vigorous constitution, her friends having no recollection of her ever having been sick; she was a widow, with eight children living; had been in the habit of going out as cook, and left the house where she boarded on the morning before her attack, in apparently perfect health. Nothing further could be ascertained of her until she fell suddenly while walking in the street, and was immediately brought into the hospital. She was a woman of strictly temperate habits in every respect.

When admitted, she was lying motionless, except the quick heaving of

Digitized by Google

her chest; completely comatose, and not giving the least indication of consciousness on being shaken or loudly called. Her skin was cool and dry; her pulse forty, very irregular, full but compressible, occasionally intermittent, with constant variation in its force; respiration forty-five per minute, regular in rhythm. Her pupils were contracted to a point, and were entirely insensible to light. There was no strabismus, nor facial distortion; and not the least stertor. Her breath had a peculiar vegetable odor, somewhat narcotic.

Her stomach was thoroughly washed out—an emetic of sulphate of zinc acted promptly; a purgative injection also operated readily; but she remained in the same condition as before. While being cupped on the back of the neck, she gaped, but gave no further evidence of consciousness or muscular power.

On the following day she was still in a profound coma; not the least sensibility or consciousness: while being bled from the temporal artery, she gaped a second time. Her pulse was sixty, full, but weak, quite regular; respiration thirty, regular; action of heart normal; no symptoms of pulmonary affection. After the abstraction of about six ounces of blood, her pulse rose very considerably in strength, and until eighteen ounces were taken continued so, when it fell to a natural condition. Her rectum and bladder required artifical evacuation. On the third day, there was no change, except that once, on being pinched, she moved all of her limbs and rolled slightly over; she also swallowed some beef-tea poured into her mouth; the pulse, respiration, and the general symptoms remained unaltered. On the fourth day, there was some stertor; spastic rigidity of the flexors of the arm and hand on both sides; no other irregular muscular action. Pulse sixty, and natural; respiration also natural. She had the appearance of one enjoying a tranquil sleep.

On the fifth day, there was no change.

On the sixth, her condition was greatly altered; her skin was cold and clammy; her pulse 120, very weak; stertor marked; froth about her lips; she had involuntary evacuations from her bowels and bladder. After I saw her in the morning she gradually sank until three o'clock P.M., when she died.

Autopsy.—On removing the calvaria, the dura mater was found quite healthy; there was no effusion, either sanguineous or serous, in the arachnoid cavity. The arachnoid was itself in places opake and thickened; the subarachnoid spaces, in the sulci and at the base of the brain, were filled with dark liquid blood, amounting in quantity to about two ounces; the pia mater was greatly injected. On cutting into the substance of the brain it was found firm and healthy. Both ventricles were distended with coagula, filling completely their cornua; the two ventri-

Digitized by Google

cles communicated, the septum lucidum being ruptured. There was great injection of the surfaces of the ventricles, but no lesion of either thalamus or corpus striatum. There was no other abnormal condition of the brain.

The other organs gave no evidence of disease; a moderate amount of atheroma in the ascending aorta was observable.

Cancer of the Hand.—DR. LENOX HODGE presented a cancer of hand, which was amputated by Dr. Peace, before the class at the Pennsylvania Hospital.

The patient from whom it was removed is a man of about fifty-five years of age. He states that about seven years ago he noticed what he supposed to be a wart, growing on the back of his right hand, at the base of the first finger. It gradually increased for two years, when it had become half an inch in height and as large as the end of his finger. He applied to a surgeon, and had it removed. The wound healed in three or four weeks, and remained well for twelve months, when the lower part of the cicatrix began to ulcerate. The ulcer continued to spread, he says, under all applications, till it extended, on the back of the hand, from the third finger to the thumb, and around on the palm beneath the first finger.

The history thus appears to be that of epithelial cancer, and its microscopical examination corresponds with what Mr. Paget describes as belonging to that form of cancer.

WEDNESDAY EVENING, February 23d, 1859.

Vice-President, DR. STILLÉ, in the Chair.

DR. HALL exhibited a specimen of tubercular deposition in the lung, following typhoid fever.

DR. LA ROCHE stated that such results, following low fevers, were more frequent in the negro than in the white. During an epidemic of typhoid fever at the Walnut Street Jail and Almshouse, many years ago, it was found that in all negroes dying of the fever, tubercular deposits existed in the lung.

DR. KELLER spoke of the difficulty of distinguishing cases of acute phthisis from typhoid fever. As a diagnostic sign he alluded to the different smell. The peculiar odor of typhoid fever has been noticed by different observers. Several years ago his attention was arrested by the odor of patients who suffered from acute tuberculosis. He has since found this odor almost invariably present. Its character is very different from that of typhoid fever, yet it cannot be exactly described. It is very peculiar and very constant.

Digitized by Google

Cancer of the Bladder and Other Organs.—DR. DARBY presented, through DR. WOODWARD, several specimens of internal cancer.

CASE I. *Cancer of the Bladder; Single Kidney.*—Nancy K., aged sixty, born in Ireland, married, and moderate in habits, was admitted into the Philadelphia Hospital on November 11th, 1858.

The history given by the patient was rather complicated, yet the following points are reliable: She was admitted into the hospital five years previously, where she remained for a year or longer, suffering from an affection of the bladder and kidneys. She was exhibited to the clinical class at that time, and treated for hæmaturia. After leaving the hospital in the same condition in which she entered it, she resided in the city, without any abatement of symptoms, and was readmitted in almost a moribund condition. Patient complained of intense burning in hypogastric region, great thirst, and disorder of the whole digestive organs. The expression of countenance was marked by intense suffering; the skin was dry, with a dull-yellow hue; tongue thickly coated; pulse weak, soft, and thread-like, with ninety pulsations to the minute. She passed constantly from the sexual organs a thick, dark-colored fetid fluid, and in such quantities as to cause a change of clothing three or four times daily. Her bowels had not been moved for ten days prior to her entrance, and then by the use of a purgative. The stomach was irritable, scarcely retaining the lightest farinaceous articles. Above the pubes there was prominence which was hard and resisting to the touch.

A vaginal examination was attempted, but from the pain given, and weakness of the patient, was discontinued. The symptoms, taken together, induced me to diagnosticate cancer of the uterus and bladder.

The treatment was palliative and supporting, anodynes, milk-punch, with lime-water, cold medicated cloths applied over the pubic region, and the bowels moved by enemata. In twelve days after being admitted, she died. In eighteen hours after death, a post-mortem was made, which corroborated the diagnosis.

Post-mortem examination.—The lungs, at two points immediately opposite, one on the right, the other on the left lung, presented small, yellowish spots the size of a pea, which exuded, when cut, a thick fluid, having, when placed under the microscope, the usual cancer-cells; the remaining part of the lungs was healthy. The heart, stomach, liver, spleen, pancreas, and kidney were healthy. There was only one kidney with its supra-renal capsule; no trace whatever existed of either of these organs on the left side; and no vessels running from the aorta, which was taken out as proof that these organs did not exist on the left side. The intestines adhered together from inflammatory action produced by pressure of the cancerous mass, which filled the whole pelvic cavity, as well

Digitized by Google

as being situated on the lower lumbar vertebræ. The bladder was thickened, and a massive vascular papillary growth, springing from its walls, projected into the cavity. The lymphatic glands of the mesentery were converted into soft pulpy tumors of moderate size, which were in some parts distinct, in others less so.

The vesical walls, the papillary growth in the bladder, and the enlarged mesenteric lymphatics, all more or less soft and brain-like to the eye, permitted a thick creamy juice to exude, when cut surfaces were scraped. In this juice the following elements were detected, by Dr. Woodward, who kindly examined it :—

1. Innumerable granules, chiefly Aschersonian vesicles, of variable size.

2. Free nuclei in comparatively small numbers, of great size and dimly granular, with one, two, or three nucleoli.

3. Innumerable cells of varied shape, containing one, two, or more nuclei, already described. These cells contained often a number of large Aschersonian vesicles, and were more granular than the nuclei.

These elements could be plentifully obtained from all parts of the morbid masses, and, taken in connection with the general appearances of the new formations, justify us in regarding the case as one of medullary cancer.

CASE II. *Cancer of the Uterus.*—Amanda C., a Philadelphian by birth, married and temperate, was admitted into the Philadelphia Hospital, November 12, 1858. Patient was forty-six years of age.

She had been treated in several hospitals in this city, and had been in this house three or four times, in different wards, in the last four years. This case was transferred from the venereal ward to the surgical, in January, 1859. The history of the case is as follows :—

For five or more years she had been suffering from uterine complaints, and had several times, in hospitals, been treated for affections of the bladder and womb, with only temporary relief. Several months previous to her last entering this hospital, she had passed from her uterus constantly a dark fetid liquid, which caused much annoyance on account of odor, quantity, and pain. She was unable to work, from pain in stooping, and could not sleep unless she took a dose of laudanum before retiring. The general aspect of the patient was anæmic, with a dirty-yellow hue of the whole surface and also of the conjunctiva. The expression of face indicated mental anxiety and pain, the skin was dry, the pulse weak, pulsating over eighty to the minute, tongue coated, and the alimentary canal deranged in function. The stomach was in such a state as to permit little to remain on it, and the bowels so torpid, as only to be roused by purgatives or enemata. Soon after she entered the ward, a per-vaginam exami-

Digitized by Google

nation was made, which told the same tale that she had given; and, taking all the symptoms, and recollecting at the same time the similarity in almost every respect to the case which had but a short time since died, I again diagnosticated cancer. A similar treatment was adopted, and in a short time a similar result took place. Prior to her death, she suffered much from abdominal dropsy; and when, thirty hours after death, I made a post-mortem examination, more than two gallons of fluid were collected. This effusion was produced by the pressure of the cancerous masses of the abdominal viscera upon the veins. These cancerous masses, wherever found, presented the usual characteristics of the nuclei and cells, so often described.

The liver was in a state of fatty degeneration, and the nodules in it exhibited the usual anatomy of cancer. The kidneys were also in a state of fatty degeneration. The pancreas appeared normal; so did the spleen. The mesenteric lymphatics were cancerous. The uterus was the same, and so broken down in its structure, as to tear when being taken from the cancerous mass, which filled the whole pelvic cavity, and which had caused, by its pressure, the fæces to be retained in hardened masses, and gangrene of parts of the colon. The stomach was much inflamed from pressure upon it; this accounts for its highly irritable state. The left lung was highly congested, particularly the lower lobe; and immediately beneath the pleura, in connection with the fibrous layer of that membrane, were a number of thin bodies, one-fourth to three-fourths of an inch in diameter, one-eighth to one-fourth in thickness, around which the pleura was slightly puckered. These bodies presented the anatomy of cancer. The right lung appeared healthy, and so did the pleura; yet the touch revealed nodules varying in size, the longest about one-fourth of an inch in diameter. These nodules were soft and pultaceous, and exhibited fat granules and angular nuclei, undistinguishable from those of tubercle.

DR. WOODWARD made some remarks in connection with these specimens. The fatty degeneration observable in the liver is not an unusual accompaniment of cancer. To this fatty degeneration may be owing the peculiar cancerous color. The cancerous cachexia is not constant. It is very frequently absent in external cancers. Indeed, it does not appear until a few weeks prior to the death of the patient. It is most marked in internal cancers, especially those of the liver. It is, therefore, not the cancer itself, but the fatty state of the liver, which occasions the peculiar color which is supposed to indicate the cancerous cachexia.

Kidneys of Different Size.—DR. LENOX HODGE exhibited two unsymmetrical kidneys.

J. W., aged forty-five years, was admitted into the Pennsylvania Hospital with a fracture at the base of the skull. He died on the third day

Digitized by Google

after his accident. In making the post-mortem examination, we found the right kidney to be double the normal size, while the left one was no larger than a Lima bean. Both kidneys were in their natural positions; both ureters were normal in position and size; and tubular throughout their whole extent. Every part of the body was well developed and symmetrical, except the kidneys. The urinary secretion was carried on as if both kidneys were in perfect action; there was apparently no difference, either in quantity or quality.

The small kidney was referred for microscopical examination to a committee.

Aneurism of the Arch of the Aorta.—DR. BRINTON exhibited a specimen of aneurism of the aorta, presented by Dr. Hay, United States Navy.

The patient, a Swede, aged sixty-four, had been admitted into the United States Naval Asylum on the eighth of December last. A large pulsating tumor, which had existed for sixteen years, was observed in the supra-sternal fossa, overlapped on either side by the edge of sterno-cleido-mastoid muscle. The patient, who was weak and prostrated, complained of pain in the tumor, and suffered much from vertigo and repeated asthmatic attacks. During the latter part of December his symptoms became much less marked, and he appeared comparatively comfortable. In the early part of January the pain in the tumor returned, and became aggravated, so as to produce a violent burning sensation. Constant and violent vomiting ensued; coming on often without effort on the part of the patient; the substances vomited, were frequently mixed with blood.

During the last days of January these symptoms increased, and the man suffered from repeated attacks of vertigo. He then gradually sank, and died from exhaustion on the eighth of February.

On post-mortem examination, a large aneurism of the arch of the aorta was revealed; the arteria innominata was much enlarged and sacculated; the calibre of the left carotid and subclavian was increased, and the walls of these vessels were greatly thickened. The dilation of the aorta extended down to the diaphragm, a portion of the tumor projecting into the abdominal cavity. At this point the bodies of the vertebræ had undergone partial absorption.

Considerable pressure had been exerted by the tumor upon the œsophagus; and the pneumogastric nerve of the left side had been flattened out for an inch in extent, so as to render it probable that its function had been much interfered with.

DR. BRINTON drew the attention of the Society to this fact, and referred to a case of section of this nerve, during the performance of the operation of extirpation of the parotid gland by Dr. M'Clellan, in which no injurious consequences resulted.

Digitized by Google

WEDNESDAY EVENING, March 9th, 1859.

The President, DR. LA ROCHE, in the Chair.

DR. ALBERT H. SMITH exhibited several specimens of softening of the brain. One case had during life been attended by pain on motion, but not the slightest feeling was evinced on irritating the skin. A history of the cases was promised for a future meeting.

Congenital Fissure of the Sternum.—DR. DA COSTA read the following paper on the case of MR. GROUX, who had presented himself at a former meeting of the Society:—

The recent visit of Mr. Groux to this city enabled me to study some points connected with the action of the heart, which I beg leave to lay before this Society. The subjoined observations were made on five different occasions, some alone, others in the presence and with the aid of several medical friends.

Mr. Groux is the well-known instance of congenital fissure of the sternum. His history has been so often described that I shall not repeat it here.

The fissure is of a V shape, and covered with skin. At its upper portion, near the second rib, and extending downwards, may be seen a distinctly pulsating mass, which has been thought by some to be the auricle, by others the ventricle, by others again the aorta.

The latter view to me seems untenable. During a full expiration a tumor protrudes through the fissure, the upper part of which is clear, or rather somewhat tympanitic on percussion; at the lower part, corresponding to the seat of distinct movement, there is absolute dullness, and a sense of resistance to the percussing finger. Now, if the parts be normal, is it possible for the aorta to be thus displaced?

The correctness of the second opinion, whether it be ventricle or auricle, is more difficult to determine. I believe the pulsating mass to be auricle, and base the opinion—

First. On its peculiar undulatory movement.

Secondly. On its position, which hardly corresponds to the ventricle.

Thirdly. On the difference in the sound heard over it and the part lower down.

Fourthly. On the time of its beat not being the same as that of the apex, between the fifth and sixth ribs.

Digitized by Google

Sounds of the Heart.—Presuming then this to be the auricle, the part below it the right ventricle, the one felt beating above it to be the aorta, I instituted comparative observations on the sounds at these different parts, some with an ordinary stethoscope, others with a small glass stethoscope with a flexible tube, and with this adjusted in a Cammann's stethoscope.

At the *aorta*, with a small glass stethoscope placed in the fissure, two distinct sounds are heard. The first is dull, and more like a continuous vibration; the second, a sharp and accentuated sound. Placing my finger immediately below the stethoscope, two vibrations, or if such an expression be permissible, two sounds, are *felt*. The first and longest vibration corresponds to the first or long sound; the second impulse communicated to the finger is short but well defined, and corresponds to the short, flapping second sound.

If the sounds of the aorta be compared with those of the pulmonary artery, it will be found that the second sound of the former is far more distinct than the second sound of the latter listened to in the first and second intercostal spaces near the fissure. The first sound over the two arteries is much alike. That of the aorta seems, however, longer, and is of lower pitch than that of the pulmonary artery.

This diversity between the sounds over the aorta and pulmonary artery is not owing to the absence of the bone permitting the stethoscope to be applied almost immediately to the aorta. To be sure of this, pieces of India-rubber, and then of bone, were placed in the upper part of the fissure. The character of the sounds remained the same, although those of the aorta were not quite as marked as before. The conclusions from this is evident. It is the sound itself which is different, and it is not its passage through the thoracic walls which determines the usual difference in the sounds perceived over the aorta and pulmonary artery.

Over the left *ventricle*, immediately above the apex, the first sound is dull, but marked, the second is ill defined. There is not any material distinction to be recognized between the sounds of the two ventricles. The first sound of the right ventricle listened to at the lower part of the fissure is clearer and less weighty than that of the left ventricle. The first sound at the apex of the heart and that of the aorta, as heard in the fissure, are much alike, excepting that the first sound of the aorta seems duller, and more like a vibration. This comparison was instituted by using two flexible stethoscopes, each retained at its respective place.

If a small stethoscope be placed over the upper part of the point which is thought to be the right auricle, a sound of very peculiar nature is perceived. This *auricular sound* is not always alike. At times it is

Digitized by Google

similar to a soft, rather musical murmur. At other times it conveys to the ear the idea of liquid, as of the stream of a fountain bursting. Or, again, it may be imitated by filliping with the middle finger. Some of this difference is probably owing to the amount of pressure exerted by the stethoscope. The general character of this auricular sound may be thus expressed: it is a continuous sound, on the whole ringing and high pitched. Although continuous, it is not, however, alike at its commencement and at its end—one is of a lower note than the other, and at its termination a click is heard.

This auricular sound stands in marked contrast to the sounds of the surrounding parts. Below it is heard the dull, lower pitched, booming sound of the ventricles. Above it the aorta sends forth its flapping second sound; not unlike that of the auricle, but lacking the somewhat metallic ring this possesses, and, as far as my comparisons went, not of as high a pitch.

There are many points about this sound of interest, and worthy of careful consideration. It is thought to be an absolute demonstration that the movements of the auricles yield an appreciable sound. I confess, although it is heard exactly over the seat of what may be presumed to be the auricle, that I am by no means fully convinced that it is caused by the movements of the auricle, or of the blood in it. I am not quite sure that it is not a valvular sound produced at the tricuspid orifice, and heard so distinctly, because, owing to the malformation, the stethoscope can be placed directly over, or quite near to, the seat of its production. It has, indeed, very much the flapping character of a valvular sound.

The sharp click with which the sound terminates, seems to me hardly to belong to it. It is heard synchronously with the drawing in of the skin over the part supposed to be the auricle. To test if such a sound might be produced at other parts, by the sudden removal of the small glass stethoscope, DR. J. F. MEIGS, with whom several of the examinations of Mr. Groux were made conjointly, applied a small glass stethoscope with flexible tube over several parts of the chest and neck. A sound precisely similar was produced by its sudden withdrawal from the skin.

Effects of the Respiration on the Heart.—The effects of the acts of respiration on the position and sounds of the heart are precisely similar to what I have often observed in other persons. In a full *inspiration* the first sound over the ventricle is lessened, not much over the right, (at the lower portion of the fissure in the sternum,) but very much over the left; the so-called auricular sound disappears entirely. The impulse moves inwards and downwards toward the median line, where it is perceptible to the finger, and also by the distinct motion of pieces of adhesive plaster

Digitized by Google

stuck to the skin. This change of position may be verified by percussion. Near the median line, below the border of the ribs, and below the lower part of the fissure, the previously tympanitic sound becomes dull; but over the seat of previous impulse, between the fifth and sixth ribs, the sound is clear.

In a fixed *expiration* the percussion dullness over the whole heart enlarges. The pulsating mass in the fissure seems to swell. The beat of the heart is felt somewhat higher up, and moves upwards from intercostal space to intercostal space. It is not easy to explain these facts. They are, however, not peculiar to Mr. Groux; I have more than once studied them in lean persons. The probable explanation seems to me to be this: the changed position of the heart in a full expiration causes its beat to be perceived somewhat above its usual seat, and over a larger space. Independently of this, I have been led to conclude from clinical observations, and as the result of vivisections, that during a forced expiration the heart increases in size, and is distended with blood. I have further found that the ventricles are the first to swell. These causes acting together would seem to account for the change of the beat, and its apparent gradual movement upwards.

Impulse of the Heart.—With reference to the much-vexed question of the impulse of the heart, whether produced by the systole or diastole, the phenomena presented by Mr. Groux are susceptible of very varied interpretation.

If a flexible stethoscope be placed in the fissure over the aorta, and a finger be applied to the apex beat, it certainly appears, as far as the touch goes, as if the dull first aortic sound corresponded in time to the impulsion against the finger. But the sphygmoscope shows an undeniable difference in time. The blue fluid over the left ventricle, and the red over the aorta, do not rise synchronously. Repeated observations, made by Dr. Meigs and myself, convinced us of this. It seems to me not unreasonable to suppose that the *two* vibrations, which may be felt with the finger, communicate to the fluid a peculiar double movement,—one from the rush of blood, the other from the flapping of the semilunar valves,—which differs from the single motion of the ventricles. This is rendered still more probable by closely watching the columns of the liquid. The one over the ventricle moves straight and with directness; the one placed on the aorta in a wavy, more broken manner. Whether this explanation be adopted or not, the double vibration over the aorta must certainly be taken into account in reasoning on the results obtained by so delicate an instrument as the sphygmoscope, before we pronounce from its indications either in favor of the systolic or diastolic theory.

The question of the impulse did not, however, engage my attention as

Digitized by Google

closely as the points above enumerated. There is so much to be studied in the case of Mr. Groux, and so much care is required in that study, that I preferred to occupy the opportunities I had of examining him in inquiring into some matters that did not appear to me to have been fully described, but which had in connection with other researches engaged my attention. These observations are, of course, only accurate, provided the position of the heart and of the large arteries is the same in Mr. Groux as in other persons. There is no reason to doubt this. Still, in every case of a similar kind, it may be made a question, whether, if Nature has omitted a sternum, she is not likely to have altered the relations of the parts in the cavity of the chest.

WEDNESDAY EVENING, March 23d, 1859.

Vice-President, DR. STILLÉ, in the Chair.

Case of Transposition of Viscera, met with in a patient who died of Phthisis.—Reported by DR. ALBERT H. SMITH.

Joseph Brown, aged thirty, native of England, ostler, entered the Pennsylvania Hospital, on March 3d, 1859. He was emaciated, extremely prostrated, and had marked lividity of the lips and face generally, presenting altogether the appearance of a man almost in articulo mortis. Upon examining him, a loud cavernous respiration, with gurgling, was found at the apex of the left lung, and an absence of respiratory sound at the lower part on that side. Percussion and inspection gave also evidence of an extensive pleuritic effusion, so great as to produce a very marked protuberance posteriorly, and an obliteration of the intercostal spaces. The right lung presented no morbid sign, except a rather rude respiration at the apex. The sounds of the heart were very feeble, but as the patient was so prostrated no very accurate examination was made of the organ, the disease in the lungs being thought sufficient to account for the symptoms. It was, however, remarked that the liver seemed greatly contracted; increased dullness on the left hypochondria was observed, but attracted no particular attention on account of the enormous serous effusion on that side.

Under the use of powerful stimulation he rallied a little; but at no time sufficiently to have warranted a surgical interference for the removal of the fluid in the pleura. On the twelfth of the month he died.

Autopsy.—On opening the thorax the first point of interest was the excessive amount of effusion in the left pleura. There was complete collapse of the left lung, and the whole contents of the thorax were forced over upon the right side of the median line.

On carrying the incision through the abdominal parietes, attention was

Digitized by Google

called to the liver lying upon the left side of the abdomen; a further examination showed that there was a complete transposition of all the thoracic and abdominal viscera, from the innominate artery down to the rectum. The left lung had three lobes, and contained a large cavity in the apex; its pleura was covered with effused and organized lymph. The right lung had two lobes. The heart lay with its apex directed to the right side; the mitral valve and aorta were upon the right, the arch of the latter curving over upon the same side, and sending out the innominate on the left side of the arch. The venæ cavæ were both upon the left side. In the abdominal cavity, on the right side were found the spleen, stomach, descending colon, sigmoid flexure, and rectum; on the left side were the liver, ascending colon, and cæcum. The larger lobe of the liver was upon the left side, though there was much less disparity between the two lobes than usual.

As the examination had to be conducted rapidly, the position of the thoracic duct was overlooked.

DR. HEWSON mentioned a case of similar transposition of the viscera, that had come under his notice. At the autopsy no appreciable cause of death was detected.

Case of Aneurism of the Aorta near the Diaphragm, rupturing into the pleura.—DR. ALBERT H. SMITH next exhibited a specimen of aneurism of the aorta.

Archibald Wilkinson, aged twenty-eight, native of Ireland, waiter, entered the Pennsylvania Hospital, March 11, 1859. The history he gave of himself was as follows: About eighteen months since he was in perfect health, having been so for ten years, previous to which he had suffered from an attack of what he called disease of the liver. At the period first mentioned he began to experience loss of appetite, indigestion, occasionally shortness of breath after violent exercise, headache, with a vague sense of uneasiness referred to the epigastrium. These symptoms did not at any time interfere with his occupation, which was not one attended with any great fatigue, until about six months since, when they increased with so much vehemence as to require him to abstain from all exertion. About this time the feeling in the epigastrium became a positive pain, of a sharp, paroxysmal character, much more severe at night. All of the symptoms above mentioned were aggravated; he became emaciated, his appetite left him, he passed sleepless nights, suffered from great mental depression, and was altogether extremely miserable.

When admitted into the Hospital, he was quite feeble, emaciated, having a sallow complexion, and a very haggard, anxious expression of face. He complained of pain in the epigastrium, as mentioned above, and also of

Digitized by Google

occasional pains in the loins and down the legs. He was obstinately constipated. Auscultation and percussion detected no abnormal condition of the lungs or heart. The liver extended considerably below the ribs, and was slightly tender on pressure. In the epigastrium was found, by moderate pressure, a large pulsating tumor, quite apparent to the eye on account of the general emaciation, and both from its producing a prominence and from its pulsation being felt immediately over the vertebral column. On placing the ear over the tumor a very loud murmur could be readily heard, extending for a short distance above the pulsating mass, and downward as far as the bifurcation of the aorta. The urine was highly charged with oxalate of lime crystals.

By means of palliatives his condition was greatly improved; his appetite increased, he slept well, and stated that he felt more comfortable than he had felt for many months. On the morning of the nineteenth, eight days after admission, he was sitting at the head of his bed shaving himself, having used no greater exertion than that of dressing slowly, when he suddenly groaned, rose up from the chair, and fell immediately. He was placed upon the bed, and I saw him about two minutes after. His respiration had then ceased entirely, the pulse at the wrist was not perceptible, though the impulse of the heart could be felt distinctly for more than five minutes after I saw him. Galvanism and powerful stimulation failed to resuscitate him in the least.

The autopsy was made about twelve hours after death. On opening the thorax, both lungs were found completely collapsed, and floating in about a gallon of bloody serum. Raising the right lung, we discovered a firm coagulum of red blood which had formed an exact mould of the pleural cavity, and was so thoroughly coagulated that it could be lifted out entire and weighed; its weight was a little over four pounds and a half. There was no hemorrhage into the peritoneum. The entire thoracic and abdominal viscera were then carefully removed, and the course of the aorta exposed. Just at the position of the diaphragmatic crura was found a sac extending about five inches in length from the lower part of the eleventh dorsal to the upper portion of the third lumbar vertebra, being thus bisected by the diaphragm and constituting a thoracico-abdominal aneurism. On the right side, near the summit of the sac, was an aperture the size of a half dime, through which it had discharged the contents of the aorta into the right pleural cavity. The aorta was then carefully dissected away from the arch to the iliac bifurcation, the diaphragm being detached and removed with it. Over the last dorsal and first two lumbar vertebræ its coats were entirely obliterated, and the bodies of these bones were absorbed to about one-sixth of their extent, the intervertebral substance remaining unaffected. The aneurism was a

Digitized by Google

false, sacculated one; the channel of the aorta continued without change in its calibre except at a point over the first lumbar vertebra, where there was an opening about half an inch in diameter into a sac—which could contain over eight ounces—extending in both directions above and below the orifice of communication. The disease had originated in the inner coat, the external being unimpaired except at the point of rupture, around which the walls were attenuated. The aorta, in its entire course, was studded with patches of atheromatous deposit. The heart was free from any evidence of disease, as also were the lungs. The liver was somewhat enlarged and congested. The colon, from about the middle of the transverse portion down to the sigmoid flexure, was narrowed to a size less than that of the small intestines; there was slight thickening of the coats but no further evidence of disease; above the position at which the diminution of calibre began, the colon was distended to about twice its normal size.

The patient had been, during his whole stay in the Hospital, free from all excitement or exertion; the action of his heart was very tranquil, and the operation he was going through at the time of his death could not, certainly, have increased its force or frequency. The rupture was evidently caused by the contraction of the diaphragm over the middle of the tumor during the act of respiration.

DR. STILLÉ drew attention to the increasing frequency of aneurism. The cause of this is perhaps to be referred to the increasing frequency in the use of alcoholic drinks as suggested by Huss.

Small Cancer of the Mammary Gland.—DR. GROSS presented a cancer of the mammary gland, not larger than an English walnut, which he had removed from a patient sixty-four years of age. The disease had existed apparently for about two years. The tumor was hard and dense, but contained under the microscope the elements of cancer. Dr. Gross drew the attention of the Society to the small size of the cancer. He had met with but few instances of such small cancerous tumors of the breast.

DR. WOODWARD stated that several of such cases had come under his observation.

Calcareous Deposits on the Pleura.—DR. WOODWARD exhibited a pleura loaded with calcareous deposits, or as it is more usually termed, an ossification of the pleura. The membrane was more than the one-eighth of an inch in thickness, and the deposit of calcareous matter involved its entire substance. A microscopical examination revealed the elements of connective tissue, and numerous granules. On the addition of acetic acid, a free escape of carbonic acid took place.

Digitized by Google

Tubercle deposited upon the Mucous Membrane of the Colon and Ileum, in the Mesenteric, Meso-colic and Meso-rectal Glands, and in the Pineal Gland.—Presented by DR. PACKARD.

T. R. W., aged nearly six years, was attacked with dysenteric symptoms on the twelfth of March. I saw him on the fifteenth. He had been liable to attacks of this kind, or as his mother expressed it, "his bowels had been weak" from early infancy.

The child was always very smart and precocious; had a very large head, light hair, pale blue eyes, and a clear complexion; his mother presents the same physical appearances.

A tendency to stupor which showed itself during the first day or two of my attendance, I ascribed to a mixture containing opium, which had been given him to check his diarrhœa. His pulse ranged from 130 to 150 in the minute; his stomach was irritable to an excessive degree, and his bowels were moved about once in fifteen or twenty minutes. No tympanites existed, nor was there any notable tenderness at any portion of the abdomen. Some gurgling was at times produced by pressure over the right iliac fossa.

The stools were bloody, small, and full of lumps like flesh-washings; there was more pain just before than during their expulsion.

The excessive irritability of the stomach and rectum, which lasted throughout the whole course of the disease, precluded the use of internal remedies. Active counter-irritation to the extremities, and fomentations to the abdomen, were the chief available means.

The symptoms amended somewhat for a day or two; the stools became more natural and rather less frequent, and the slight headache which had troubled the child passed off. No diminution of the irritability of the stomach and rectum could, however, be perceived, and there was a good deal of restlessness and even delirium at night.

At my morning visit on the eighteenth, he seemed a little better in every way; but at noon I was sent for, and found him in a strong convulsion, his surface pale and cold, and his sight gone; pupils dilated and somewhat unequal. By active stimulation and counter-irritation, he was brought out of this state, but sank and died in about three hours.

With the assistance of Dr. Wurts, I made the autopsy, forty-three hours after death: Body very much emaciated. *Head* and *abdomen* only examined.

Skull very large, and well-shaped. Bones thin, and almost entirely without diploë. Dura mater adherent to the calvarium. The brain was large and heavy, and much congested, as were also the arachnoid and pia mater; but no abnormal condition of any portion of it was noted, except the very great softness of the pineal gland. The ventricles con-

Digitized by Google

tained a very little bloody serum, and about f℥ij escaped from the sub-arachnoid space. The fifth ventricle was extremely large.

The colon being laid open, its inner surface presented a reddish tinge throughout, owing to the diffusion over it of minute points of vascularity. Its appearance was also somewhat villous, from a soft deposit with which it was covered. Similar conditions were observed in the ileum, and the increased vascularity was especially noticeable in the glands of Peyer.

The lymphatic glands of the mesentery, meso-colon, and meso-rectum, were in a state of great enlargement.

Upon placing under the microscope portions of the pineal gland, of the deposit alluded to as found on the mucous surface of the colon and ileum, and of the mesenteric glands, the peculiar corpuscles of tubercle were at once detected.

Nothing abnormal was observed in any of the other organs.

The hygienic circumstances by which this child had always been surrounded were very favorable; he was well clothed and fed, and in every way well cared for; no disease of any kind seems to have prevailed either in his father's family or his mother's. An older child died several years ago at two years of age, with symptoms which I judge from the account given by the parents to have been analogous to those in the present case; and a younger one is said to be liable to similar attacks of diarrhœa.

The very excessive irritability of the entire alimentary canal, from the outset to the close of the disorder, does not seem to me to be accounted for by the lesions discovered after death, although it would of course have been amply explained had the brain been more extensively diseased.

Intra-uterine Fracture of the Clavicle.—DR. KELLER reported the following case.

Mrs. H., of Philadelphia, twenty-seven years of age, became pregnant for the fifth time about the twentieth of December, 1857. Although not robust, she is not of a weakly constitution, and enjoyed, as previously, good health in the first months of her pregnancy.

On riding out in a light carriage, toward the middle of April, she met with an accident. One of the hind-wheels broke off at the axle, and she, leaning forward, fell upon the front wheel so that she injured herself externally on the right side of the abdomen.

She experienced, however, no further disagreeable consequences, and on the first of May felt, for the first time clearly, the motions of the child. In the middle of June she had, without any apparent cause, a severe hemorrhage from the womb, which lasted one day and then ceased entirely.

During the last two months of her pregnancy she felt frequently unwell, and often suffered from pains resembling spasms of the womb. On the

Digitized by Google

twenty-first of September, after several hours of normal pains, she was delivered of a healthy girl. Three days afterwards, the nurse pointed out to me a striking swelling on the neck of the child, which, upon careful examination, I recognized as a completely consolidated fracture of the middle of the clavicle, of which the exterior half stood upward and outward, joined behind in an obtuse angle to the rest of the bone. In an erect position of the body only a very slight deformity was visible, but when the head was much turned it became very apparent.

Considerable discussion followed the report of this case. It was suggested whether the swelling might not have been a morbid growth involving, or springing from the bone.

DR. KELLER could positively affirm that such was not the case. The child was in excellent health, and the deformity so precisely like that resulting from a fractured clavicle that there seemed to him no room for doubt.

DR. PACKARD spoke of the exceeding rarity of such fractures. He could find but one case of intra-uterine fracture of the clavicle reported, that referred to by Malgaigne.

DR. GROSS mentioned the instance placed on record by Glockengiesser, where one hundred and thirty fractures existed in the same fœtus.

Report of the Committee on the Small-sized Kidney exhibited by DR. HODGE.—The Committee appointed at the last meeting but one of the Society, to examine the specimen exhibited by Dr. Lenox Hodge, (*see page* 202 *of Proceedings,*) would respectfully report that they placed a portion of the small body, concerning the renal structure of which doubt existed, under the microscope; and that they found in it the tubular character of a normal kidney.

JOHN H. PACKARD,
WILLIAM A. HAMMOND.

Digitized by Google

WEDNESDAY EVENING, April 13th, 1859.

Vice-President, DR. STILLÉ, in the Chair.

DR. HUTCHINSON exhibited a specimen of fracture of the parietal bone with rupture of the middle meningeal artery, accompanied by extensive extravasation of blood upon the surface of the brain.

Depressed Fracture of Skull.—DR. LENOX HODGE presented a specimen of depressed fracture of the skull. The man, from whom the specimen was taken, died a few hours after he was brought to the Pennsylvania Hospital, suffering from the effects of a railroad accident.

The base of the skull was fractured, directly across from the petrous portion of one temporal bone to the other; and a depressed fracture of about two inches in length existed in the parietal bones, crossing the sagittal suture, a little above the occipital bone. This specimen shows the tendency of the internal table to exhibit a more extended fracture, and a more marked depression than that indicated by the external table. To test the reality of this difference, it was suggested to me to take a plaster mould of the injury of the external table. I did so; and the difference appeared still more marked, when an elevation was compared with an elevation at the same time, and not an elevated surface with a depressed surface at different times.

The Secretary presented, for DR. JOHN K. KANE, a specimen and the history of a *case of Mitral Disease, accompanied by a musical sound, together with hypertrophy of both ventricles, without dilatation, and perhaps even with contraction of the cavities.*—John O'Brien, a white boy, aged seventeen years, was a native of Philadelphia, and had always resided there. For some months back he had been an inmate of the House of Refuge, from which institution he had been discharged on account of illness. About seven years before he had a severe inflammatory rheumatism; ever since then had been subject to palpitations of the heart, and also to attacks of dropsy.

When I saw him, for the first time, on the fourth of March last, he was complaining of cough, pains in the abdomen, and dysentery. He was lying in bed, very pale, with a hot, dry skin, and had as many as from ten to thirteen stools per diem. The discharges were composed of blood and mucus, with little or no odor. His abdomen was slightly tender on pressure, but not swelled; his face and eyelids, however, were puffy, and his penis and scrotum were highly œdematous. The heart's action

Digitized by Google

appeared tumultuous and irregular, but the pain in the abdomen and extreme weakness were such, that it was not until three days afterwards that I was enabled to make a critical examination into the state of that organ. The abdominal pain and dysenteric discharge ceased almost immediately under the influence of calomel and opium; but they were followed by an enormous effusion of serum, the penis and scrotum becoming tense with fluid; the eyelids more puffed; the legs œdematous; and the abdomen much distended.

On the seventh of March, the patient appearing better and stronger, I availed myself of the opportunity to examine into the condition of his thoracic viscera, and obtained the following results:—On inspection, I found great bulging of the left side, the intercostal spaces being widened, but not bulged. A little below the axilla of the left side there was a distinct depression of about three inches in diameter. The impulse of the heart, described more particularly hereafter, was also observable. Auscultation detected subcrepitant and coarse sibilant râles throughout both lungs. Percussion produced a clear sound over both lungs as low down as the fourth rib; but below this the sound became dull over both. The dullness, however, was more marked, and the resistance to the finger greater, on the left than on the right side. The cough was at times severe. The expectoration was thick, and of a whitish color. Owing to the great amount of effusion it was impossible to define the heart's limits by percussion, except to the right superiorly, where a distinct dullness was perceptible at the third interspace, three-fourths of an inch to the outside of the right border of the sternum. The impulse was tumultuous, strong, and wavy, and caused such a fluctuation in the mass of fluid contained in the abdomen as made it distinctly visible throughout its whole extent. It was most marked, however, at a point three inches below, and a little to the outside of the left nipple, where two distinct impulses could be seen and felt, one slightly above and a little after the other. The rhythm was exceedingly irregular; the average number of beats to the minute was one hundred and fifty-six. On listening over the left side a peculiar blowing sound was heard, a prolonged whiff, winding up a with a clear musical note, a sol. This sound, or rather these sounds, were loudest at the point of strongest visible impulse, leading to the belief that the mitral orifice was the seat of their production; they could be heard, however, with slight loss of clearness at the aortic cartilage, and more faintly over the whole of the heart's extent. They were apparently coincident with the systole, but the heart's action was so tumultuous and irregular, that it was impossible to say, with certainty, that such was the case. It was equally impossible to determine whether the sounds heard at the aortic cartilage were altogether transmitted from the mitral valves, or whether there was not also some aortic

Digitized by Google

disease. I rather inclined to the latter opinion. Careful auscultation over the third left cartilage and ensiform appendix gave no reason to suspect any valvular disease on the right side of the heart. In both places a clear first and second sound could be distinguished, together with a faint transmitted murmur from the left side. There were no arterial or venous murmurs. The pulse at the wrist was so feeble and irregular that I was unable to ascertain whether it coincided with the heart's impulse or not. The patient complained of inability to lie except on his back, and though he never had pain over the region of the heart, he had frequent palpitations, attended by a sense of suffocation. His urine, which was scanty, and of a pale straw color, assumed a thick curdy appearance on being subjected to the action of heat or nitric acid. His gums were swollen, of a pale blue color, and apt to bleed. His tongue was coated at the centre with a yellow fur, the edges being slimy, and of a bluish tint. His appetite was capricious and weak, and he often suffered from nausea. This last was, no doubt, due in part to the quantities of acidulated liquids which he was in the habit of swallowing, and for which his thirst appeared insatiable. My diagnosis was hypertrophy of both ventricles, together with mitral insufficiency and aortic constriction. I thought it probable also that there were old pericardiac adhesions, and there was certainly coexistent Bright's disease of the kidneys.

My friend, DR. DA COSTA, who was kind enough to visit the case with me two days afterwards, was of the same opinion, but suggested that there might also be constriction of the mitral orifice, as well as insufficiency of its valves.

The treatment of this case was necessarily limited, owing to the weakness of the patient, and his tendency to nausea. A variety of diuretics were tried and discarded. Most of them merely sickened him, while those that were free from this objection appeared to lose their efficacy after a few days. I finally fell back on lemon-juice and the simple carbonated water of the shops, which seemed to be quite as effective, and were certainly much more palatable than any others. With regard to sedatives to allay the heart's action, the same difficulty existed,—digitalis and aconite caused emesis before affecting the heart. Belladonna plasters placed over the cardiac region would influence it favorably for a few hours, but after that they lost their influence. As a temporary relief during palpitation, I found a rag wet with chloroform, and applied over the heart, beneficial. Pains in the lower limbs, referable to œdema, were treated by bandaging, and rubbing with a chloroform liniment. Warm baths, simple expectorants to relieve his cough, and nitromuriatic acid as a tonic, with, now and then, a mild cathartic; these made up the general treatment which I adopted. The symptoms varied but little during the first three weeks of

Digitized by Google

my observations; of course, the amount of œdema was less on some days than others, but it was not until the twenty-third of March that I saw any marked change in the patient's general condition. On the morning of this day, when I paid my visit, I found him dull, sleepy, and feverish; his face, which had all along been pale, was flushed, and his eyes glazed. The action of his heart was more than usually violent, and the blowing sound, with its musical termination, remarkably well defined. He slept heavily all that day until about six in the afternoon, when he was taken with a profuse bleeding at the nose, which lasted half an hour, and was arrested with difficulty. He seemed relieved after this, and when I paid my evening visit, at half-past seven o'clock, he expressed himself as feeling more comfortable than he had done for some days past. His skin was pleasantly cool and moist, and his heart beating more tranquilly. He slept well that night, but on the following morning had several attacks of weakness and partial syncope. When I saw him, however, about ten A.M., he appeared better, his pulse was not weaker, and his heart was more tranquil than usual. He said he felt well and hungry. On listening to the heart's sounds, I was struck by the fact that the musical note, which had remained constant, and which had been more than usually marked the day before, had gone entirely. It never returned. The blowing sound, however, remained, and continued not perceptibly altered in pitch until the end of the case. The patient continued better until the third day after this, when he had a recurrence of the attacks of weakness. From that time he grew weaker, and his dropsy steadily increased. On the third of April, his nurse informed me that he had involuntary evacuations from his bowels. On the morning of the fourth of April, I noticed him picking at his bedclothes in a nervous, undecided manner. That evening I was sent for in a hurry. I reached the house at eight o'clock, and found him very weak, gasping for breath, and complaining of dreadful pain in his limbs. It was evident from his expression of countenance that death was coming on. He fell asleep, however, under the influence of anodynes, and continued sleeping until about one A.M., when he awoke, exclaiming that he was dying. At about two A.M., he again fell into a doze, which continued until it lapsed into death, at five o'clock in the morning of the fifth of April.

A post-mortem examination was made five hours after death, in which I was assisted by DR. DA COSTA and one of his students. There was great general emaciation, but owing to the large amount of dropsical effusion, it was not until we cut into the integuments that it became evident. Before being opened the body was much swelled, and the legs discolored. On opening the chest a quantity of serous fluid escaped. Both lungs were much compressed, the left more than the right, and old resistant

Digitized by Google

adhesions were found throughout the whole extent of both pleuræ. The pericardium was so adherent to the pleura of the left lung that it was very difficult to separate them. On removing the heart in its pericardium from the body, the two surfaces of the pericardium were discovered to be universally adherent to each other, and on cutting into the heart itself, both ventricles had the appearance of being *concentrically* hypertrophied. Further examination of the organ was postponed until post-mortem rigors should have time to subside. On the examination being continued, sixty hours after death, we found the wall of the right ventricle to be as much as one and one-third inches in thickness, its columnæ carneæ being enormously developed. On measuring the transverse diameter of the cavity of the right ventricle at its widest portion, we found the distance from wall to septum to be one and one-third inches. The walls of the left ventricle were not so extensively hypertrophied as those of the right. They were much more so in the neighborhood of the mitral orifice than elsewhere. A measurement taken just below this point gave as much as three-fourths of an inch in thickness, while lower down they measured not quite half an inch. The columnæ carneæ, too, though larger than normal, bore no proportion to those of the right ventricle. The greatest transverse diameter of the left ventricle from wall to septum was one and three-quarter inches. The pulmonary and tricuspid valves and orifices we found to be normal. On examining the mitral opening we found the orifice itself constricted, and the valves thickened and insufficient. The aortic orifice was constricted, and its valves, though insufficient to close it, were considerably thickened. Both auricles were apparently normal, though clots of considerable size were found in both; the right being almost entirely filled by a non-adherent clot, while the left contained a large adherent clot of elongated shape which had its origin directly at the mitral orifice.

The symptoms in this case have been detailed.

The post-mortem examination having verified the diagnosis, it might seem a work of supererogation to designate the particular indications which led to the different diagnostic conclusions. I may venture, however, to invite attention to two points, which seem to me to be worthy of more than a merely passing notice. The first, the fact of two impulses being visible at the point of apex beat taken in connection with the extensive agglutination of the pericardial surfaces. There were other reasons which led me to suspect the existence of pericardial adhesions. The fact of the præcordial interspaces not being bulged, while there was evidently so great an amount of effusion into the cavity of the thorax. The extreme lowness of the point of apex beat, notwithstanding the great abdominal distention, and the knowledge of the previous attack of inflam-

Digitized by Google

matory rheumatism already referred to, followed by palpitations, all looked in that direction; the strong double impulse settled the point to a certainty. The second point, for which I would ask consideration, is the musical sound which was produced at the mitral orifice, and which so suddenly disappeared. The action of the heart was so tumultuous that it was impossible to say whether it was coincident with the systole or diastole of the ventricles, and yet its existence caused Dr. Da Costa to suspect constriction of the mitral orifice, as well as disease of the valves. The reason he gave was, that in all the cases of purely cardiac musical sounds which had come under his notice, constriction had been present. The post-mortem results showed this actually to be the case. I am, therefore, constrained to believe that the musical note, which was of very short duration, was not a mere termination of the regurgitant blowing sound, but rather a distinct sound caused by the blood passing through the constricted orifice, and coincident with the diastole of the ventricles. What was its mechanism, and why it ceased, it would be difficult to say. Perhaps a shred of vibratile lymph was its cause, and this being suddenly swept away, or gradually thickened by fresh deposits, the sound was no longer produced. Another hypothesis equally plausible and equally insusceptible of proof, is, that the sound was produced by the resisting edges of the constricted orifice vibrating in the current of the blood, and that these, for some reason, (increased thickening, for instance,) lost their musical resonance. Perhaps the adherent clot found after death in the left auricle, was the cause of its cessation, either by altering the direction of the current, or otherwise.

The heart was referred, for further examination, to a committee.

WEDNESDAY EVENING, April 27th, 1859.

Vice-President, DR. STILLÉ, in the Chair.

Pericarditis, and alteration of the Valves of the Heart.—DR. HALL exhibited a specimen of Pericarditis, accompanied by changes in the valves, removed by him from a patient of Dr. Martin; the man was about fifty years of age, and had suffered for years from rheumatism.

The symptoms were those usual to the disease. The physical signs were as follows:—

Dullness over the region of the heart, the limits much increased, and the sound flat. Friction sound, with a thrill to the hand or ear, below the left nipple. A murmur during both systole and diastole, was heard loudly over the heart and arteries, and moderately over nearly the whole anterior part of the thorax and in the carotids. The normal

Digitized by Google

sounds were both absent or entirely obscured by the murmur. This was heard most clearly over the aortic valves, and from there it was transmitted down toward the apex.

Post-mortem examination.—The head was not examined. There was a large effusion into the right pleural cavity, with bands of highly organized lymph lining the pleura. The lungs were highly congested at their base, but were otherwise healthy. The pericardium was distended, with about five ounces of amber-colored serum; there were one or two small patches of lymph upon the pericardial surface of the heart. Measurements taken on the spot showed the heart to be affected with eccentric hypertrophy, being enlarged in both diameters. The aortic and mitral valves were thicker than natural, but no decided disease appeared—not so much as was expected. A very small patch of atheromatous deposit was found on one of the curtains of the aortic valves. The right side of the heart was healthy. There was no disease of the kidneys.

The blowing sounds over the aortic valves were, Dr. Hall thought, to be accounted for by the presence of considerable dilatation of the ascending aorta, producing an inaccurate closure of the valves. There was not sufficient change in the structure of the valves to have originated a murmur. Nor was it caused by impoverished blood, since the man did not look in the least degree anæmic.

Multilocular Ovarian Cyst.—Presented by DR. HUTCHINSON.

The patient had been tapped during life and an enormous quantity of a tenacious albuminous fluid discharged. The cyst filled the whole abdomen. It sprang from one ovary; the other was healthy, but perhaps somewhat harder than natural.

Report of the Committee on the Heart, presented by DR. KANE.—The committee appointed to examine the specimen of supposed concentric hypertrophy of the heart, presented to the Society at its last meeting by Dr. John K. Kane, respectfully report:—

That owing to the fact that the specimen above mentioned had, when submitted to examination, been a lengthened period in alcohol, and was, moreover, greatly mutilated by previous examinations, the committee hesitate to express a decided opinion from personal inspection and measurement. Taking, however, into consideration the careful measurements made by Dr. Kane and recorded in the paper accompanying the specimen in question, and comparing them with numerous measurements made by other observers of normal adult hearts, there does not seem scarcely a doubt of the existence of concentric hypertrophy in the case under consideration.

Digitized by Google

The committee would refer to the following table of M. Bizot,* showing the capacity of the human heart:—

LEFT VENTRICLE—MALE.

AGE.	LENGTH.	BREADTH.
1 to 4 years	20 lines.	31 lines.
50 to 79 "	36 "	56⅜ "
Average, from 15 to 79 years . .	34 4/61 "	54 8/61 "

LEFT VENTRICLE—FEMALE.

1 to 4 years	18½ lines.	29⅝ lines.
50 to 79 "	31 "	49½ "
Average, from 15 to 89 years . .	31 1/30 "	48 23/30 "

RIGHT VENTRICLE—MALE.

1 to 4 years	20½ lines.	47½ lines.
50 to 79 "	37⅓ "	87 "
Average, from 15 to 79 years . .	57 14/61 "	82 11/61 "

RIGHT VENTRICLE—FEMALE.

1 to 4 years	18⅞ lines.	44⅛ lines.
50 to 79 "	35 11/15 "	76 "
Average, from 15 to 89 years . .	34 "	76⅜ "

WILLIAM A. HAMMOND,
ROBERT P. HARRIS.

WEDNESDAY EVENING, May 11th, 1859.

The President, DR. LA ROCHE, in the Chair.

Gunshot Wound of Neck.—Presented by DR. LENOX HODGE.

J. McC., about thirty years of age, was brought to the Pennsylvania Hospital on the afternoon of Friday, April 29. He had a gunshot wound of the neck. The wound of entrance was on the middle line in front, and over the lower part of the larynx. There was no wound of exit. Respiration had already ceased, but his heart was still beating, the pulse being full and slow, about thirty in a minute. The surface was pallid. A small clot of blood lay on his chest.

Artificial respiration appeared to produce no effect. Thinking that there might be some impediment to the passage of air through the larynx, I enlarged the wound downward, and inserted a tracheotomy-tube. Through this we could readily force the air, but still failed to restore the respiration.

---

* Cyclopedia of Anatomy and Physiology, art. *Heart*, vol. ii. p. 586.

Digitized by Google

Upon making the post-mortem examination we found that the ball having fractured the cricoid and thyroid cartilages, had passed directly through the larynx and œsophagus, and struck the body of the sixth cervical vertebra; then glancing a little to the right it had torn away a portion of the bone, passed between the transverse processes of the sixth and seventh cervical vertebræ, and lay imbedded in the muscles on the back of the neck. Upon opening the larynx, we saw that in addition to the fractures the mucous membrane was much torn from its attachments, and fell like a valve; and that several small coagula of blood were present. The trachea and bronchia contained no coagula, but a little fluid blood. The membranes of the spinal cord were deeply congested where the ball passed near them, but there seemed to be no solution of continuity. In examining the other organs, we saw nothing worthy of note in this connection.

The point of special interest in the case is, to determine the exact cause of death; was it the injury to the larynx or to the spinal marrow, or both, conjointly, or perhaps still other causes which occasioned it?

DR. HAMMOND stated that a case had come under his notice in New Mexico, where a slug fired from a smooth-bored gun in the hands of an Indian, at a distance of about two hundred yards, split upon the anterior portion of the thyroid cartilage, into two pieces of unequal size, which passed under the skin and made two orifices of exit. One of these was a little posterior to the left ear; the other on the right side, about an inch from the cervical vertebræ. The exact shape of the slug could not be determined, but as Indians are in the habit of chewing their slugs into shape, he judged from those he had seen which had been thus formed that it was an irregular ovoid, three-quarters of an inch in the long, by half an inch in the short diameter. Dr. Hammond further stated that Indians shoot with small charges of powder, which might tend somewhat to account for the fact of the ball not having entered the cartilage. He also alluded to a case reported to him by another medical officer of the army, in which a musket ball had split upon the nasal bones, the pieces entering the eyes.

DR. LA ROCHE made the following communication:—

The medical profession of this city have very lately sustained a severe loss by the death of Dr. Henry Bond, who for about forty years enjoyed among us the well-merited reputation of a judicious practitioner and honorable and high-minded gentleman. He died on the fourth of May last, in the seventieth year of his age.

As Dr. Bond was not a member of this Society, I should not have called attention to the circumstance of his death, had not the disease under which he labored and which finally carried him off, and particularly the morbid

Digitized by Google

appearances discovered on inspection of his body, presented some points of interest.

For some twelve or fifteen years prior to his death, he labored under the usual symptoms of hypertrophy and valvular disease of the heart. About eight or ten months ago, while walking in the Washington Square, he fell to the ground under an attack of apoplexy, and was thence carried to his house, where, under the use of judicious remedies prescribed by Drs. Bell and Hoyt, who in my absence from home were summoned to his assistance, he soon recovered his consciousness. The consequence of the attack was paralysis—almost complete—of the whole left side of the body, as also the organ of speech. From this condition—in which I found him at my first visit with Dr. Bell, who continued to attend him—he in a great measure and rather rapidly recovered; sufficiently so, indeed, to be able to raise his hand and arm with a certain degree of facility, and to walk in and out of doors without assistance, and with little more than a moderate drag of the affected foot. The muscles of his face presented slight evidence of the nature of the disease. His articulation was somewhat thick, slow, and indistinct; the pitch of his voice low, and the force of the sound so feeble as to require the closest attention on the part of those near him to enable him to be understood. His mind appeared clear, though giving evidence from day to day of a tendency to a gradual loss of strength.

On election day he walked out alone to cast his vote, and passed the day as usual, without indicating any sign of increasing disease. He played a game of backgammon with a friend in the evening, remained in conversation with the family until after ten o'clock, when he retired to bed. The next morning, between six and seven o'clock, he was found by his servant, dead on the floor of his chamber. He was lying on his left side, near the bed. His extremities were cold, but relaxed. On the forehead, just over the left eye, was a cut and contusion, surrounded by blood, evidently produced by his striking, in falling, the edge of a bureau situated near the bed. The clothes on the latter were scarcely deranged.

The autopsy was made thirty hours after death, by Dr. Brinton, in presence of Drs. Bell, Wood, Coates, Condie, C. P. La Roche, and myself, and revealed the following appearances:—Occipital protuberance uncommonly prominent, with corresponding thickness of bone. The entire surface of the brain exhibited great venous congestion. The arachnoid membrane, especially toward the summit of the brain, was decidedly opake, with effusion beneath it of a serous fluid, and in patches, of a semi-gelatinous matter. The vessels at the base of the brain were all more or less ossified. In cutting into the substance of the brain, the medullary matter became immediately covered with innumerable small spots of red blood.

Digitized by Google

The choroid plexus was considerably congested. A large amount of serous effusion—probably two ounces—was contained in the lateral and other ventricles. The hippocampus major of the right side was unusually large, infiltrated with fluid, and decidedly softened. The velum interpositum was strongly injected with blood. The substance of the medullary portion of the anterior lobe of the right side of the cerebrum was considerably softened and injected with a pus-like fluid, the softening extending as far back as the descending cornua. The cerebrum was large in size and firm in texture; the convolutions were uncommonly deep. The cerebellum was, compared with the cerebrum, uncommonly small in size; it was congested, but less so than the cerebrum. The cartilages of the ribs were ossified. Old adhesions of the left lung to the costal pleura were discovered. Considerable effusion into the cavity of the pericardium existed. The right auricle contained a very large amount of fluid blood. The heart was much above the medium size, and on its surface were to be seen large deposits of fatty matter. The coats of the aorta exhibited ossific deposits. The left ventricle was considerably hypertrophied and thickened; the right nearly natural. The semilunar and mitral valves were, especially at the base, thickened and ossified.

The changes found in the heart confirmed fully the opinion which had long been expressed of the nature of the disease of that organ under which Dr. Bond labored so many years. Those found in the brain were sufficient to account for the attack of apoplexy and paralysis. In consequence of not finding in the latter organ any marks of recent disease of a kind calculated to explain the sudden death of the patient, and in view of the nature of the morbid changes in the heart and of the unusual accumulation of blood found in the right auricle and surrounding vessels, several of those present at the autopsy were inclined to look to that organ for the immediate cause of death.

WEDNESDAY EVENING, May 25th, 1859.

Vice-President, DR. STILLÉ, in the Chair.

Four Cases of Wounds of the Liver.—Presented by DR. GEORGE C. HARLAN.

CASE I.—The specimens on the table were taken from a man killed yesterday afternoon by a fall. He fell from a height of three stories from a ladder. At the time of his admission into the Hospital he was entirely insensible, the respiration was labored, the pulse frequent and full, the pupils contracted, and blood was flowing freely from both ears. There was no reaction, and he died in about half an hour.

Digitized by Google

A post-mortem examination revealed an extensive fracture of the base of the skull, involving the occiput on both sides of the foramen magnum and the petrous portion of both temporal bones. On the left side of the occiput the separation was wide enough to allow the blade of a large scalpel to be readily introduced into the fissure. There was some blood at the base of the brain, but no clot. The blood had continued to flow from the ear for some time after death. There were lacerations of the cerebellum corresponding in position and extent to the fissures in the occiput. The liver was also injured. There was a laceration on the upper surface of the right lobe, about four inches in length and one-eighth of an inch in depth, presenting an irregular, granular appearance. There were two or three ounces of effused blood in the peritoneal cavity, but no external marks on the abdomen. This is the fourth case of rupture of the liver that has occurred in the Pennsylvania Hospital within the last two months, and as illustrating the frequency of this injury in hospital practice, it may be worth while to give a brief account of the three others.

CASE II.—A few weeks ago an old man was admitted into the Hospital, with injuries inflicted by a railroad accident. The accident occurred at Paoli, twenty miles distant, and when he reached the Hospital he was very much exhausted, and almost pulseless. Though terribly injured he was perfectly conscious, and complained most of dyspnœa and pain in the abdomen. He died in about an hour. Several ribs were found to be broken, the right lung was torn, and there were compound fractures of the leg and arm. There was upwards of a pint of effused blood in the peritoneal cavity. The liver was ruptured in more than twenty places. The lacerations were from an inch to four or five inches in length, and their greatest depth was about a quarter of an inch. They had occurred principally on the right lobe, and occupied both the upper and under surfaces. No signs of external injury of the abdomen were detected.

Of the other two cases, one occurred in Dr. Hutchinson's ward, and he has furnished me with the following notes:—

CASE III.—A man was brought to the Pennsylvania Hospital during the last week of March, having met with serious injuries in consequence of his wagon and a train of cars having come into collision. The man was evidently dying at the time of his admission, about an hour after the accident had occurred, and no very thorough examination was attempted. Death took place in less than three-quarters of an hour.

An autopsy made thirteen hours afterwards revealed an extensive fracture of the skull, also of the three lower true ribs of the left side. The peritoneal cavity contained about four ounces of blood. Upon the upper surface of the left lobe of the liver, at its extreme border, was a stellated rupture, about three-quarters of an inch at the deepest part. The dia-

Digitized by Google

phragm was not ruptured; nor was there an external injury in the region of the liver.

For the notes of the fourth case I am indebted to Dr. Hodge:—

CASE IV.—Bernard Bradley, aged twenty-one, was run over by a cart. He had, when first seen, a fractured humerus, and stated that the wheel had also passed over his body. He complained of pain across the abdomen, but had no mark of contusion; no crepitus of the ribs was found. He was very drunk, and had walked in with the assistance of police officers. He was admitted between three and four o'clock A.M.; vomited frequently during the morning; sank suddenly, and died about half-past three o'clock P.M.

Post-mortem examination.—Brain showed nothing worthy of notice. In the cavity of the peritoneum were several ounces of bloody serum; in the pelvis handfuls of clots. The liver was lacerated and contused on its under surface near the gall-bladder.

The experience of the Hospital decidedly confirms the opinion that the liver, next to the brain, is the viscus most likely to suffer from falls and contusions; a fact that its size and weight will readily account for. The prognosis is, of course, always very unfavorable. Where the injury is extensive, it will most probably be followed by fatal depression, on account of the sympathy existing between the abdominal viscera and the other parts of the system by means of the great sympathetic. The three sources of hemorrhage—the hepatic artery, hepatic vein, and vena porta—increase the danger of death before reaction. If the patient should be fortunate enough to pass that stage, he is still subjected to the risk of violent peritonitis, and must overcome the difficulties that the secretion of a gland always presents to the healing of a wound in its tissue. These considerations make recovery appear almost like a miracle, and have induced some surgeons to believe that none but the most superficial wounds of the liver ever heal, and that others are necessarily and invariably fatal.

This is certainly true as a general rule, but numerous decided exceptions are recorded by various authors.

The subject appears, at different times, to have excited a good deal of attention, and experiments have been made on the lower animals. Among others, Dr. Monro, of Edinburgh, removed portions of the liver from rabbits, without permanently injuring their health. The wound cicatrized, as in other parts of the body. Guthrie, in his Commentaries, speaks of three cases, terminating favorably, in which protruded portions of the human liver were excised. Another is mentioned, in Thompson's work on the Liver and Spleen, in which more than three ounces of the organ were removed, and the patient got well. Dr. Smith, of Maryland, reported, in the

Digitized by Google

North American Archives, (vol. i. page 385,) the case of a man, whose liver was wounded by a dagger, made by grinding the point on a common table-knife. Unpleasant symptoms subsided on the fourth day, and the man recovered. Hennen, in his Military Surgery, records a case in which a musket-ball entered between the eighth and ninth ribs behind, two and a half inches from the spine, and passed out in front, between the seventh and eighth ribs, four and a half inches from the sternum. Hemorrhage from both wounds lasted three days, and the posterior continued to pour out a bilious discharge for nearly six weeks. In three months from the time of the accident the patient was in almost perfect health.

The recovery of two other cases is recorded, in which bile was discharged from the wound, in one of which a musket-ball could be felt buried five inches deep in the organ. The man lived several years, though his health was bad, and purulent and bilious matter was constantly discharged from the wound. Dr. Thompson refers, in the work above quoted, to a case of gunshot wound of the liver, in which the patient died some time afterwards of a different disease, and it was found that the ball had passed through the left lobe, about three inches from its lower border.

In nearly all the above cases the injury was followed by jaundice, and in several the characteristic pain in the shoulder was present. How soon the jaundice appeared is not mentioned.

When the gall-bladder is wounded, death is almost inevitable from the constant flow of bile into the peritoneal cavity. Thompson mentions one authentic case of recovery. The patient died of thoracic inflammation two years afterwards, and a bullet was found in the gall-bladder.

In all the cases referred to above, there were external openings. As lacerations from concussion and contusion can only be certainly recognized by examination after death, there is an entire want of statistics in reference to the possibility of their recovery. The want of an exit for the discharge is an unfavorable circumstance, and as they are hardly likely to heal by first intention, their only chance is probably in the formation of an abscess and of peritoneal adhesions.

It may, however, perhaps be possible for recovery to take place even without these adhesions. Dr. Nicol, an English army surgeon, located for some years in India, found, in many instances, cicatrices on the surfaces of the liver, which, in his opinion, must have occurred from the bursting of abscesses into the cavity of the abdomen. Hennen has also seen several similar cases.

Several members of the Society alluded to cases in which they had had positive evidence, or thought it exceedingly likely that the liver had been wounded and the wound cicatrized.

Digitized by Google

Rapidly Recurring Encephaloid Cancer of the Left Breast.—Dr. S. W. GROSS presented a specimen of cancer of the breast, from an unmarried servant woman, forty years of age, whose menstrual functions were performed regularly.

It was removed yesterday morning by Professor Gross, and was the fourth operation which has been performed for the same disease in the last twenty months. In the first three operations the gland was but partially removed, leaving the greater portion as the nidus for the new formations. About two years since the first tumor made its appearance, and was extirpated at the expiration of four months. The second soon began to develop itself, and was removed in nine months. In a few weeks the third tumor commenced to grow, and was excised in seven months, and the specimen on the table was removed four months and a half after the last operation.

All of these tumors were tuberculated, firm, and compressible, and inclosed in an imperfect cyst, formed by the condensation of the surrounding cellular tissue. There was no retraction of the nipple, and no involvement of the neighboring lymphatic glands. The subcutaneous veins were enlarged, and the tumor was the seat of sharp, shooting pains, extending to the shoulder.

The woman's general health has always been excellent; she has always made good recoveries from the operations, and there is no cancerous disease in her family.

Physical examination showed that the tumor was encephaloid, which was confirmed by the microscope, a great number of very large cancer-cells being present.

The points of interest in this case are, the rapid recurrence of the cancer; the non-involvement of the lymphatic glands; the absence of the cancerous cachexia; the good health of the patient; and the non-appearance of the tumors at the cicatrices of the former operations.

DR. WOODWARD said that he was much interested in the case which had just been detailed to the Society, and had especially noted the fact of the absence of the symptoms of the cancerous cachexia in this rapidly recurring cancer. The so-called cancerous cachexia is often absent, both in cases of scirrhus, and encephaloid. Cancers may be observed, from time to time, possessing the attributes of malignancy in a terrible degree, running a most rapid course and speedily terminating fatally, but in which none of the so-called cachectic appearances occur at any time. As a general rule, when cachexia exists, there is more or less disease in important internal organs, cancerous infiltration, fatty degeneration, and the like.

On page 201 of the Proceedings, his remarks would seem to indicate that he attributed the cancerous cachexia exclusively to fatty degenera-

Digitized by Google

tion of the liver. He desired in this place to correct any erroneous impression which might arise from the perusal of that paragraph, which only in part represented his views.

Undoubtedly disease of the liver plays an important part in *some cases* in the production of the appearances called cachectic; we are not yet in a condition to say that it does in all. Nor can we overlook the part which the diseased state of other internal organs, as the mesenteric and other lymphatic glands, the intestinal canal, the lungs, etc. may play in creating a cachexia.

It is necessary to observe the utmost care in such investigations as the present, lest a generalization, based upon a limited number of facts, be overturned on a wider survey. But we are placed in this position: the cancerous cachexia so-called is not constant; cancer may exist without it, and that in any degree of severity; nor are these rare exceptional cases; they are exceedingly numerous, every surgeon can recall them from his own personal observation; and hence is inevitably and logically drawn the inference, that the cachexia is not *necessarily* the companion of cancer; that it is an *accident*, and not an *essential;* and if an accident, we are driven to look beyond the carcinomatous disease to the complications and to the disturbed functions of involved organs for its cause.

If these views be correct, it legitimately results that the diagnostic value of the cachexia is very small. The fact of its absence will not prevent the surgeon from diagnosing cancer in many cases. But it has been said that *when present* the cachexia invariably indicates cancer. This assertion at once starts the question, is the cachexia so peculiar that it can unhesitatingly be called cancerous, *apart* from the evidences of a local cancer? It is to be regretted that this question must be answered in the negative. There is no one symptom belonging to this cachexia that may not be met in other diseases; and in patients free from cancer, but suffering from various chronic diseases, and especially from painful diseases of internal organs, a train of symptoms occasionally arises so exactly imitating the so-called cachexia as to lead to errors in diagnosis even by experienced physicians and surgeons.

The question of cancerous cachexia, and its cause, or causes, was further discussed by several members of the Society.

DR. DARRACH stated that he had had several times occasion to notice that the cancerous cachexia is well pronounced when the lymphatic glands are the seat of the disease.

DR. PACKARD remarked that from some cases which had come under his observation, the cachexia accompanying cancer seemed dependent, in part at least, on the degree of influence directly exerted by the local disease upon the function of blood-formation.

Digitized by Google

Thus in several cases of small cancerous deposits stricturing the œsophagus or pylorus, and in this way interfering essentially with the supply of alimentary material, the cachexia was very marked. In several others, the rectum being the seat of disease, this symptom was but slightly developed. When, however, extensive formations of cancer take place in the rectum, and especially when they increase rapidly,—when a drain is thus established upon the blood already formed,—the cachexia is apt to be well-pronounced.

Small or slowly-growing cancers, so seated as to interfere with the function of blood-formation, as for instance in the stomach, liver, or lungs, seem, therefore, to be attended with a more marked cachexia than those seated elsewhere. But if the latter are very large, and abundantly nourished, they have a like effect, perhaps, however, owing in great measure to their drafts upon the whole mass of blood. A remark made a few minutes since by Dr. Darrach, that the cachexia is generally well-pronounced when the lymphatic glands are the seat of the disease, seems to afford obvious support to the idea suggested.

Dr. Packard would of course by no means assert that a mere deficiency of blood-material, or a mere drain upon the fully-formed blood, is by itself assignable as the cause of the cachexia in cancer. Whether there is added to either a specific element, and in what that specific element may consist, are questions not yet answered; meanwhile the circumstances mentioned have perhaps some weight, if they are in accordance with general observation.

Digitized by Google

WEDNESDAY EVENING, June 8th, 1859.

DR. HEWSON in the Chair.

DR. DARRACH exhibited a specimen of extensive post-mortem digestion of the stomach, which occurred in a case of tubercular meningitis.

Tubercle of the meninges of the Brain and of the Kidney.—DR. HUTCHINSON said: The specimens which I present were removed from the body of a German, aged twenty-six, who died yesterday afternoon.

He was admitted into the Pennsylvania Hospital, on the 19th of March, for phthisis, which had not then advanced to the stage of softening. Shortly after his admission he complained of difficulty in passing his water. Upon examining the urine it was found to be albuminous, and to contain pus and blood-cells in great abundance. He also complained of pain upon pressure in the region of the kidneys.

He suffered much from severe headache, and from the first evinced a decided tendeney to sleep. There was also pharyngitis, but I could see no ulceration

The history of the case is rather imperfect. Two years ago he had been caught in a severe shower, and thoroughly drenched. This circumstance had given rise to a severe cough, which had afterwards assumed a chronic form. He had had night-sweats, and had been losing flesh for some time previously.

His condition did not improve under the ordinary treatment for phthisis. The urine deposited pus and blood, even more copiously than at the time of his entrance into our wards. The pulse was very frequent. No diarrhœa occurred. Ten days ago there was a marked increase of the pain in his head, and delirium set in. During the delirium he was exceedingly restless, and uttered almost constantly short, quick cries of pain. Five days ago he became semi-comatose, and on Sunday complete coma supervened.

Death took place on Tuesday.

The autopsy was made fifteen hours after death. The head was first examined. There was found a slight congestion of the membranes of the brain, and an effusion of four ounces of serum in the ventricles. Tubercles of the size of a pin's head were deposited in the pia mater, especially on each side of the pons Varolii and in the fissure of Silvius. Upon opening the lateral ventricles the septum appeared to be incomplete. Miliary tubercles were scattered through the lungs in great abundance. A small cavity was detected at the top of the right lung.

Digitized by Google

The left kidney was somewhat larger than normal, and presented a "bosselated" appearance; its whole structure was destroyed and converted into a series of tuberculous abscesses—some of them sufficiently large to contain a walnut. These abscesses showed no tendency to communicate with the abdominal cavity. The right kidney was rather enlarged, and contained a few minute tubercles in its cortical substance. The left ureter was considerably dilated. The bladder was thickened, and had its mucous membrane slightly roughened. I could discover no tubercles either in the peritoneum or in the mesenteric glands. The right testicle had undergone tubercular degeneration.

In two other cases which have happened recently in the hospital, the left has been the kidney affected; and, in referring to M. Rayer's work, I find that out of sixteen cases, the disease has attacked both kidneys six, the left seven, and the right only three times.

In none of these cases did tubercular meningitis exist as a complication.

Fatty Kidneys in Typhus Fever.—DR. HUTCHINSON continued: I also present two other kidneys removed from a patient, who during life presented the symptoms of typhus fever, and after death some of the appearances of that disease. One kidney is found to be uncommonly enlarged, double the ordinary size; the other to have undergone complete degeneration. Under the microscope nothing but oil could be discovered. The urine was albuminous, and contained free oil.

The patient was under treatment only a few days. Nothing satisfactory could be learned in regard to her former history, but she seems to have been well two weeks previous to her admission here.

Considerable discussion followed the exhibition of both these specimens.

DR. PACKARD had noticed tubercle corpuscles and some fibrous tissue and spindle-shaped cells in the tubercular kidney. The fibrous tissue and the cells were in the walls of the abscesses.

DR. WOODWARD subsequently reported more particularly on the structure of the walls, and stated that they were mainly composed of unsoftened tubercular matter. The spindle-shaped cells he believed to belong to the lining of the tubuli uriniferi.

Partial Fractures of the Ulna.—Presented by DR. LENOX HODGE.

Frederick Trump, aged fifteen, while at work in a machine-shop, had his left arm caught by the band, and was twice carried around the shaft. His arm was torn completely off, about three inches below the shoulder-joint; the skin and tissues around the shoulder were much lacerated.

Digitized by Google

Amputation was performed by Dr. Norris, through the joint; and the patient recovered without a bad symptom.

Upon examining the arm we found that there were, besides the fracture of the humerus, a fracture of the radius, and two partial fractures of the ulna.

The ulna, with its partial fractures, I exhibit to you to-night. The upper is situated at the juncture of the upper and middle third; the lower is in the middle of the lower third of the bone. They both involve the periosteum on the anterior surface, pass obliquely and for a short distance longitudinally upward; the fibres that remain unbroken are bent, so that the whole bone is curved forward. In this specimen there is no *angular* deformity, and when covered by muscles, fasciæ, and skin, would furnish, not the symptoms of partial fracture, as usually given, but of bent bones. "Pain and loss of power in the limb, its preternatural curve, which could be increased or diminished optionally, and the disposition in the bones, when straightened, to return to their flexed position, unattended by crepitus, or that circumscribed projection which a displaced fragment of bone would produce."* So that in a case like this there would be nothing left to guide us, in forming a diagnosis, but the age of the patient. Indeed, the accident might occur, if the blow or fall were sudden and severe, even in children under two years, and then the partial fracture could not be distinguished from the bent bone. It may be that this has really happened in some instances where the injury was regarded as a bent bone. And since some fibres of the bone must have given way if the curve is reproduced when the force that straightened it is removed, it would perhaps be more accurate and simple to classify, as Dr. Hamilton does,† bent bones as a mere division of incomplete fractures.

Within a few weeks several cases of incomplete fractures have been brought to the Pennsylvania Hospital. One was that of a clavicle of a boy, eight years of age; the curve was forward and downward; was unattended by crepitus or angular deformity. The boy had fallen down, several steps, and had at the same time fractured his humerus. The deformity of the clavicle could be but partially removed. Another was that of the forearm of a boy of fifteen years of age, who had fallen down five weeks after a fracture, which he describes as "having gone clean through." The arm was perfectly straight, he says, until he fell. When brought to the hospital, both bones were *curved* very much backward. The middle of

---

* Remarks on certain Injuries of the Bones in Children. By John Rhea Barton, M.D. American Med. Recorder, Jan., 1821, p. 11.

† Report on Deformities after Fractures. By Frank Hastings Hamilton. Transactions American Med. Association, 1855, p. 421.

Digitized by Google

this curve was about an inch and a half above the wrist. The bones could be straightened, but a part of the deformity had a tendency to return. The present incomplete fracture occupies about the same position as the previous complete fracture. There was but little callus present; so little, indeed, that a previous fracture would not probably have been suspected. This case is mentioned as being analogous to, though perhaps not strictly identical with, an incomplete fracture of *bone*.

This morning, a boy, sixteen years of age was brought to the hospital, with many severe injuries, received by being carried twice around a shaft in a steam marble works. His left forearm is curved forward, on the radial side, gradually throughout its whole length, and bent forward, on the ulnar side, angularly, at about two inches above the wrist. There is no crepitus perceptible, neither in the radius nor ulna. The ulna, indeed, presents the signs of a partial fracture, while the radius exhibits those usually attributed to a bent bone. But owing to the age, and the specimen exhibited to you, I am led to consider them both as partial fractures.

To these I would add another injury, caused by a cart-wheel passing over the forearm, in which the radius was broken, and the ulna presented all the signs of an incomplete fracture. The ulna was bent strongly toward the radial side, but could be straightened. There was a marked tendency toward reproduction of the deformity when the counteracting force was removed. No crepitus could be elicited; there was no increase of mobility except to and from the radial side. There was an angular projection in the upper third of the bone. The man is twenty-six years of age, and apparently healthy and well developed. I have not found a similar case recorded as occurring in an adult; and even Dr. Barton says:* "That a partial fracture cannot occur in a healthy adult, is very possible." Yet there seems to be no good reason why it *may* not occur. The rapidity and force with which the blow is given, the extent of surface to which it is applied, might, it would seem, be so varied as to sever all the fibres or only a portion of almost any given substance. And there are instances recorded† even of old persons (where the earthy constituents preponderate still more) having had partial fractures of the neck of the femur. In the above-mentioned case, notwithstanding all our efforts, there is still now (at the end of five weeks) a perceptible bend toward the radius.

---

* Amer. Med. Recorder, Jan., 1821, p. 14.

† Guy's Hospital Reports, second series, vol. ii. p. 347. American Jour. of Med. Science, April, 1857, p. 306. Fractures of Neck of Thigh-Bone, by R. D. Mussey, M.D. Or, as quoted by Dr. Packard in the American edition of Malgaigne's Treatise on Fractures, Philadelphia, 1859, p. 552. In the case recorded by Dr. Mussey, the patient was only forty-two years of age.

Digitized by Google

The exhibition of this specimen led to some remarks by Drs. Hewson, Packard, and Hall, on the diagnosis between partial fracture and bent bone.

Severance of Cervix Uteri during Labor.—DR. KELLER said: It will be remembered that at a former meeting of the Society, (see page 17 of its Proceedings,) I presented a specimen of a torn-off neck of the uterus. I wish, to-night, to add some additional particulars of the case, and especially to record the fact that the patient has since been delivered of a healthy child, without difficulty.

Mrs. P., twenty-eight years of age, from Bohemia, after having suffered for almost two months from violent spasms of the womb, reached the normal term of her pregnancy. Having been sent for on the 19th of September, 1857, at seven o'clock P.M., I found the vaginal portion of the cervix uteri opened for about an inch and a half, and presenting forward and upward, and rigid, and about an inch long. I prescribed unguent, belladonnæ, and endeavored at every pain to draw down the uterus, in order to bring it into the right axis. Being greatly fatigued I left the patient, leaving word to send for me as soon as any difficulty should arise.

Next morning I was called for, and heard that she had been delivered, at two A.M., of a dead boy, and that at the sexual parts a particular tumor had formed. On examination I found the whole vaginal portion of the cervix uteri torn off, and only suspended by a pedicle protruding from the vagina. Upon consultation it was decided to lay a ligature round that part of it which was undetached, and then to cut it off. This was done without causing the slightest bad symptom.

The patient did not even get the milk-fever, and felt so well, that after a few days, she left the bed, in spite of my remonstrances; in consequence of this, a hemorrhage took place several times, which, however, soon stopped. The ligature came away after four weeks.

At the beginning of April, 1858, Mrs. P. was suffering from anæmia, and I was obliged to remove a bleeding wart from her breast by ligature. About this time she became pregnant again, and was tolerably well until about the end of December, when she was again attacked with spasmodic pains of the womb. On examination, I found the inner os uteri closed.

On the 3d of January, 1859, early in the morning, she had natural labor-pains, and when I examined her, at one P.M., I found the inner os uteri —around the rim of which I could carry my finger—opened. The waters burst at two A.M. She was soon after delivered of a full-grown female child. The after-pains, which were very severe, were increased by her carelessness, in consequence of which she was for eight days suffering most terribly in head, limbs, and body, so severely that she had even to

Digitized by Google

send for me at night-time. Yet she recovered very fast, and she and her child were, when I saw her last, (May 30th, 1859,) in a perfect state of health.

WEDNESDAY EVENING, June 22d, 1859.

Vice-President DR. STILLÉ, in the Chair.

DR. HALL exhibited a femur, with partial fracture through the great trochanter and without the capsule, taken from the body of an adult.

DR. PACKARD presented a preparation of a larynx and trachea, completely invested with a smooth and delicately formed false membrane.

Scirrhus of the Rectum.—DR. LIVEZEY read the following:—

L. J., aged fifty-three, had always enjoyed good health up to his last illness, except that he complained of some irritability of the stomach, which he attributed to dyspepsia. In December last, he was attacked with pain in the lower part of the pelvis, along the course of the ureters, accompanied by pain upon pressure over the region of the kidney. He suffered at the same time from retention of urine. He was treated by a practitioner in the country by means of diuretics, and other articles, for what was supposed to be spasmodic stricture of the neck of the bladder, with an irritable or inflamed condition of that organ. The catheter was frequently used to draw off the urine. The bowels were costive; injections being required to procure a stool. In this way he remained for several months, sometimes improving, so that he could pass his urine without difficulty; at other times suffering from a relapse, when the same symptoms were presented in an aggravated form.

I saw the patient in April; he then complained very much of the irritable condition of his stomach; and about this time he had a slight hemorrhage from the urethra. Early in May he came to the city and seemed much better, although some slight œdema of the face and feet had occurred. The urine presented a straw-colored appearance, was found to be highly albuminous, with a sp. gr. of 1009; but presented nothing abnormal under the microscope. At this time a physician was called in consultation, and pronounced the case, upon careful examination by the rectum, one of cancer of the prostate gland. A few days later the patient had a return of profuse hemorrhage from the urethra. The irritable condition of stomach was increased and persistent, almost every thing being rejected, at one time even stercoraceous matter was vomited. The patient gradually became weaker until he was unable to leave his bed; the hemorrhage from the urethra recurred, and he complained of pain in and around the pelvis and lower extremities. To use his own

Digitized by Google

expression, he felt as though his joints were being torn asunder. He died on the 2d instant.

Autopsy, forty-eight hours after death.—Rigor well marked. Discoloration over the lower part of abdomen; body much emaciated; no abdominal effusion; intestines congested externally; no softening or mammillation of the mucous membrane; and no thickening or rigidity of pyloric extremity of stomach; the mesenteric glands were free from disease; the bladder was empty and contracted, its muscular coat was hypertrophied, its mucous membrane slate colored, and exhibiting signs of chronic inflammation; the prostate was enlarged about one-fourth its natural size; its internal structure was of a pale, yellowish bacony appearance. Vesiculæ seminales were healthy; the meatus was dilated. The kidneys were enlarged and quite flabby, the left one congested, but not pale or waxy looking. The pelves of the kidneys were very much distended. The rectum, about two inches above the anus, was involved in a body of cartilaginous thickening, which cut with an evident jarring to the knife. The diseased portion encircled about two-thirds of the circumference of the intestine, and extended upward about four inches; it was firmly connected with the posterior wall of the bladder, but did not appear to penetrate deeply into its structure. Under the microscope the prostate presented amorphous masses of colloid. This was tested for starch, but none was found; the cells were paler than natural. The nodular mass presented bands of fibrous tissue; but owing to the length of time that elapsed before the examination was made, it was impossible to speak definitely as to the nature of the cells. The pain in the lumbar region and the uniform diffusion of the blood through the urine, made it probable that the hemorrhage came for the most part from the kidney, at the same time that the occasional occurrence of clots in the urine, and the pain on pressure over the bladder, together with the post-mortem appearance of changes of structure in that organ, would seem to show that some at least of the blood was derived from the bladder.

Strangulation of the Intestine.—DR. F. G. SMITH presented, through DR. STILLÉ, the following account of a case of strangulation, with a drawing illustrative of the lesion:—

On the 19th of April, 18—, I was called to see Mr. A. W. D., who was said to be affected with a sudden attack of bilious colic, and found him suffering from constipation, nausea, restlessness, and great pain in the bowels, of a spasmodic character, but without abdominal tenderness on pressure. The usual anodynes and aperients were at once employed, but without any decided alleviation of the symptoms.

On the 20th, the nausea, griping, and restlessness had increased in

Digitized by Google

violence, and distressing hiccough, with tenderness on pressure in the right iliac region, had supervened. The symptoms of local inflammatory action led to a resort to venesection, with no apparent effect, however, but that of a temporary abatement of the spasmodic pain. A few hours afterwards the pulse had become very feeble, and rated 120 beats to the minute; the singultus continued, the tenderness on pressure was increasing, and the bowels were still unmoved. Under these circumstances, a consultation with Prof. Jackson was requested, and further depletion, this time by leeches over the seat of pain, was determined on, together with the rapid administration of mercurials, with a view to their constitutional effect.

In the evening, but little improvement was observed, except in a slight lessening of the local tenderness. Early the next morning, I found him sitting on the close stool, to which he had resorted, in a vain attempt at an evacuation of his bowels. He was then pulseless, and notwithstanding immediate and most active stimulation, both externally and internally, his death followed within half an hour after he had risen from his bed. It may be stated that on the day of his attack, he had eaten rather heartily of stewed cherries; this had created some uneasiness in his bowels, on account of which he had gone to stool, and while straining was suddenly seized with a sharp pain. Domestic remedies were used for the removal of this pain, throughout the night, without effect.

Autopsy twenty-six hours after death.—Present, Drs. Jackson and J. Neill.

In the cavity of the abdomen the small intestines were found to be distended with flatus, and injected, but not inflamed. Having been traced in the direction of the ilio-cæcal valve, about twelve inches of the intestine were ascertained to be completely strangulated.

The strangulation was produced in this manner: Near the termination of the ileum there was an attempt to form a supplementary cæcum, which resulted in a blind pouch communicating at a right angle with the ileum; from this abnormal pouch to the true cæcum there extended a fold of mesentery, under which a portion of the ileum had insinuated itself. During the efforts at stool, this portion of ileum probably ruptured the extended membrane, and was carried twice through the opening by the peristaltic action of the bowels. As the gut had a disposition to straighten itself, the band of membrane was twice carried around the intestine, thus most effectually strangulating it. The mode of strangulation may be demonstrated by tearing a slit, about three and a half inches long, near the edge of a piece of muslin, and then through the opening passing twice a piece of tape, doubled upon itself so as to represent a knuckle of intestine. It will be found, upon pulling on the two extremities of the tape

Digitized by Google

so as to render it tight, that the edge of the muslin will embrace the tape instead of occupying its first position, thus clearly showing the manner in which the intestine was strangulated in this unfortunate gentleman's case. The strangulated portion was highly injected, but not inflamed.

The case is presented to the Society as an item of experience in a class of cases always interesting, notwithstanding their almost invariable fatality.

The Society then adjourned until September.

WEDNESDAY EVENING, September 14th, 1859.

The President, DR. LA ROCHE, in the Chair.

Expectoration of Bronchial Casts.—DR. GROSS exhibited a complete cast of a bronchial tube, with its ramifications, expectorated by a patient of Dr. James E. Reeves, of Virginia, and read Dr. Reeves's history of the case:—

Mr. J. P. T., aged thirty-five, height five feet ten inches, average weight one hundred and fifty pounds—in early life and for nine years a teamster, subsequently a dry-goods dealer—suffered a severe attack of enteric fever in the year 1853, and for twelve years, ending in 1856, was an immoderate whisky drinker. From this time he began a more temperate life, from compulsion; for during the last two years of his debauchery his health had markedly failed. He had not, as far as he could recollect, suffered from acute bronchitis.

February 23d, 1858, he requested my opinion respecting certain symptoms under which he labored, which had harassed him, with little variation, for more than a twelvemonth. These were, wandering pains in the chest and right hypochondrium; shortness of breath; frequent disposition to clear the throat, with slight huskiness of the voice; palpitations of the heart; heat and dryness of the skin; occasional flushing of the cheeks; costiveness of the bowels, and impairment of the strength and appetite.

Auscultation revealed no morbid sounds, except at the lower part of the lungs.

I advised thorough pustulation of the chest, and alteratives, under which treatment improvement seemed to follow. But on the 15th of March the patient went on military parade, the fatigue of which caused a return of his uneasy sensations, and from this date cough became more urgent. On the following day, while on the street and suffering a fit of cough, he brought up, without premonition, about two ounces of bright blood. The next day, about the same hour and at the same place, hæmoptysis re-

Digitized by Google

curred; eight ounces were lost. From this time up to 10th of April—when the last and most alarming hemorrhage occurred, and with it the expulsion of the casts—he continued, at intervals of from three to six days, to bring up blood in gushes; the smallest quantity brought up at any one time was two ounces; the largest, thirty; the aggregate amount lost being not less than one gallon and a half. After the second hemorrhage the blood was less florid, and frequently mixed with black coagula. As above remarked, with the expulsion of the casts the hemorrhage ceased, save an occasional bloody sputa; and from that time the patient began to improve. At present he is in the enjoyment of good health, having very much increased in flesh.

For the arrest of the hemorrhage, lead, alum, dilute sulphuric acid, gallic acid, and other astringents were used, but were of little benefit. After-treatment: Chest kept sore with tartar emetic ointment; frictions to the entire surface, night and morning, with a salt towel; small doses of morphia; cod-liver oil; syr. of iodide of iron; and milk-punch.

DR. GROSS referred to a similar case described by John Hunter.

The specimen was referred, for microscopic examination, to a committee.

Digitized by Google

WEDNESDAY EVENING, Sept. 28th, 1859.

The President, DR. LA ROCHE, in the Chair.

Chronic Thickening of the Peritoneum, occasioning a Friction Sound.—DR. HUTCHINSON remarked on this case as follows:—

Daniel Smith, aged 66 years, a native of Germany, a ragpicker, was admitted into the Pennsylvania Hospital August 12th. We could learn very little of his history; but he asserted most positively that he had been sick for only six weeks, and that, previously to that time, he had been able to follow his usual occupation. His son has since told us, that twenty years ago it was thought he had phthisis, but that he entirely recovered, and has since then enjoyed good health.

At the time of his admission he was exceedingly emaciated and pale. He stated that he had become so during his illness. His pulse was always over 100, and in the evening it frequently ran up as high as 120. His skin was harsh, dry, and hot. His tongue slightly coated and dryish. The percussion was abnormally clear over all parts of the chest, except between the scapulæ; on the left side it was slightly dull; on the right, more so. A mucous râle was heard at the lower part of the right lung; in all other parts the respiration was normal. There was no cough, excepting toward the close of his life. The abdomen was drawn in, but not irregularly nodulated, as it usually is in tubercular peritonitis; it was tender to the touch, and imparted a sensation of doughiness to the hand. When the hand was passed over the abdomen, so as to cause one surface of the peritoneum to rub against the other, a grating sound was heard, and on one occasion a full respiration was sufficient to produce it; grating was also felt distinctly by the fingers. Percussion over the region of the liver indicated rather a diminution of its size. The spleen was not enlarged. He had one or two passages from his bowels daily, which were small and whitish. The urine was natural. The treatment adopted was entirely of a supporting nature. He was removed from the hospital three days before death, and died September 25th.

An autopsy was made eight hours after death. The head was not examined. *Thorax.*—Both lungs were found bound to the parietes of the chest by old adhesions, the right completely so; they were studded with large irregular masses, which were found in some cases to inclose a cretaceous substance; in the neighborhood of these nodules, and in other parts of the lungs, there was a deposit of carbonaceous matter. A similar deposit had taken place in the bronchial glands. The only healthy portion of the

Digitized by Google

lungs was the lower lobe of the left lung. The heart was of normal size, and presented no traces of disease, with the exception of a slight ossific degeneration of the aortic valves. *Abdomen.*—The peritoneum was found to be very much thickened, having in the median line a thickness of a quarter of an inch; on its surface were numerous minute elevations, about the size of a millet-seed. The whole of the small intestines were glued together. The liver was so adherent to the diaphragm that some force was necessary to separate it from its attachments. It was found somewhat smaller than natural, and had upon its surface bodies similar to those seen upon the peritoneum; the finger could readily be passed through its substance. The pancreas, stomach, and kidneys were healthy. There was but a small amount of effusion into the cavity of peritoneum. The deposit in the lungs, when submitted to microscopical examination, was believed to be tuberculous; its being cretaceous, and surrounded by a carbonaceous substance, gave rise to the opinion that it had been deposited twenty years before his death.

I may state, as bearing on the case, that Bennett, in his "Lectures on Clinical Medicine," says, "Nothing is more common than to see chronic tubercles surrounded by black pigmentary matter." Rokitansky also notices the association of black pigment with old tubercle.

Digitized by Google

WEDNESDAY EVENING, Oct. 12th, 1859.

Vice-President, DR. STILLÉ, in the Chair.

Chronic Gastritis, Duodenitis, and Colitis.—DR. J. F. MEIGS exhibited, through the Secretary, specimens of these disorders; accompanying them were these notes of the case:—

William C., aged 22, born in Ireland, a hackman in Philadelphia; had been in this country five years. Never sick in bed before last spring; but once, while in Ireland, had had a pain in the breast. Went to Cuba about March 1st, to work on the railroad from Havana to Matanzas; was taken sick with severe fever three days after arrival; was delirious, and very sore over stomach. He was cupped on breast and back of neck, and well purged and vomited. He was sick ten days before he went into the hospital, where he lay about two months; in the hospital he had chills and fever, and a little diarrhœa. Started for home about the end of May. During last half of passage was very sick; had severe diarrhœa for two weeks. Landed at Philadelphia 19th June, where he lay at a boarding-house, very sick. He had chills, and was cured; then seized again, and entered the Pennsylvania Hospital July 14th; was treated in hospital; went out much better, after two weeks, and did pretty well until Thursday, August 18th, when, late in the day, after dinner, he threw up his meal and a *large quantity* of dark blood; entered hospital again Monday, August 22d.

Condition on admission.—Very pallid and unhealthy looking; just the aspect of chronic intermittent; not emaciated, but somewhat thinned; quite able to walk about; no fever; no pain, except in epigastric region, where there was decided tenderness, without tumor. He had at this time very slight diarrhœa: ordered him quinine and iron, diet of arrow-root and milk, and to lie abed. But he grew gradually worse, ejected almost everything at times from the stomach, and then would pass two and three days without vomiting. The diarrhœa was moderate at first; stools thin, like gruel, containing flocculent, feculent matter, floating in liquid; color yellowish and brownish; no mucus noticed; no tenesmus; no griping; no blood at any time seen in the stools; at no time indeed was there the characteristic slimy and bloody discharge of dysentery. Tongue generally clean; never much furred; smooth, soft, and moist, until toward the end. It was never red, glazed, nor shining; but smooth, and at times rather polished; no aphthæ nor exudation. At no time had he any violent fever, yet there was at times a slight febrile irritation; no sweatings. Nothing, either dietetic or medicinal, exerted any positive control over the symp-

Digitized by Google

toms. Milk, mixed with lime-water, and containing small quantities of brandy, was tried after the arrow-root gruel with milk had failed. Beef tea, chicken soup, meat of chicken, mutton chop, all failed in turn; toward the last, yolk of egg in wine, with small quantities of beef essence, suited best. After the quinine and iron, he was treated with creosote, with bismuth and chalk, with kino and opium, and laudanum enemata, with tannin, were used. When he had been in the house two weeks, he became decidedly, though never deeply, jaundiced. This subsided, and disappeared about two weeks before his death; still, the urine never contained bile, and the stools were never clay colored. When he entered there was decided enlargement of spleen; it could be felt, jutting three or four inches from beneath the left margin of the thorax, and the dullness over the left hypochondriac region was augmented beyond its natural area, but the size of the organ diminished after about two weeks treatment. We also found unusually strong pulsation of the abdominal aorta; and a hard body could be felt across the aorta, just above and to left of umbilicus. Dullness was observed under the right margin of thorax. There was also a well-marked systolic mitral murmur.

Autopsy.—The lungs were healthy. The heart not altered in structure, even the mitral valves being quite healthy, and showing that the mitral murmur, heard during life, must have been the result of the anæmic state of the blood. Stomach very much dilated; its mucous coat thickened and softened, and deep in color; no large ulcerations, but a few small, superficial ones, such as are called by Rokitansky hemorrhagic erosions. Duodenum very considerably dilated, and all its coats, especially the mucous, thickened, and the latter also softened, but presenting no ulcerations; the lower extremity of this intestine was found to be fastened to the edge of the liver and to the gall-bladder, by quite strong adhesions. Pancreas enlarged and hardened, but not scirrhous, nor exhibiting any appearance of recent inflammation. Spleen natural. Liver decidedly enlarged, with its lobular structure extremely well marked; it presented the appearance called nutmeg. Kidneys presented nothing remarkable. Small intestines healthy. Large intestines extensively and most seriously diseased. The cæcum showed an advanced condition of inflammation and ulceration. The ascending and transverse colon exhibited the same appearances, in a somewhat less advanced degree. The descending colon and the rectum presented a mucous membrane deeply inflamed and ulcerated; the color dark, deep red, with very numerous ulcerations, while between the ulcerations portions of mucous membrane retained their natural structure, except that they were deep red in color, and thickened. The appearances here seen were such as Habershon has described; large portions of the mucous membrane being lost, the remaining portions looking like small polypoid formations.

Digitized by Google

The most interesting feature of this case was the singular latency of the colitic disease, so far as any dysenteric symptoms went. The patient had neither pain in the intestine, soreness to the touch, mucous, or bloody stools. There was, I am sure, at no time, though the stools were repeatedly and carefully examined, any appearance of mucus, blood, or pus; nor a complaint of pain, nor tenesmus, nor straining. There was severe diarrhœa toward the last, but no dysentery, and the gastric symptoms, as exhibited by hæmatemesis, and almost constant vomiting, were most severe and prominent. In fact, the gastric symptoms predominated so much from the beginning, and throughout the case, that attention was drawn away from the intestines as the chief seat of disease. The severity of these symptoms was due, no doubt, to the extensive changes which had taken place in the stomach and duodenum, both of which organs exhibited thickening, with softening of the mucous membrane, and very considerable dilatation. This diseased condition, especially the dilatation, were probably due, in part at least, to the adhesions which fastened the lower end of the duodenum to the liver and gall-bladder. These adhesions interfered with and impeded the peristaltic movement of these two viscera, and thus gave rise to inverted action, and assisted greatly in the production of the frequent and severe vomiting.

The diagnosis might have been in all probability made, had proper attention been given to the history of the case. The origin of the attack in a hot climate, where intestinal diseases and complications are frequent, ought to have directed more careful observation to the large intestines, in spite of the predominance of the gastric symptoms, when, perhaps, a still more minute examination of the stools might have revealed deposits of pus, or shreds of false membrane.

DR. GROSS did not think it possible that a mucous surface as diseased as the one on the table should not have secreted pus.

DR. KELLER believed that the patient had been seized at the onset of the attack with dysentery, and not with fever, as reported.

Report of Committee on a Plastic Cast of the Bronchial Tubes.— The committee to whom the specimen of plastic exudation from the bronchi, exhibited by Dr. S. D. Gross at the last meeting but one of the Society, was referred for examination, beg to submit the following report:—

Examined microscopically, the structure was found to consist of very fine fibres, arranged nearly parallel to one another, and having a slightly wavy course, (ordinary areolar tissue.) Nuclei were abundantly distributed along the bands so formed, and some free nuclei were also present.

A small number of non-ciliated epithelial cells of the squamous variety, probably from the bronchial tubes, were also observed.

Digitized by Google

The committee compared this case with the analogous ones collated by Dr. Peacock, in the Proceedings of the London Pathological Society, vol. v., and with those published by the same gentleman, in the London Medical Times and Gazette for 1854; and they regard this specimen as quite remarkable for its size and perfectness.

Fig. 9.

Fig. 10.

The drawings accompanying the report show the cast as it appeared to the naked eye; and its fibres, dotted with nuclei, as exhibited by the microscope.

JOHN H. PACKARD,
WM. KELLER, } *Committee.*

DR. PACKARD then presented a paper "On the Pyogenic or Suppurative Diathesis," the reading of which was deferred until the next meeting.

Digitized by Google

WEDNESDAY EVENING, Oct. 26th, 1859.

The President, DR. STILLÉ, in the Chair.

DR. PACKARD read the following paper:—

ON THE PYOGENIC OR SUPPURATIVE DIATHESIS.

The above term has been preferred to those which have from time to time been applied to the affection now to be discussed, as being least open to the charge of prejudging the matters at issue. The name by which it is most commonly designated, *pyæmia*, expresses a theory not universally received; and so also does that of *purulent absorption*, or *resorption of pus*, both of which have found advocates. All these titles are significant of the changes in opinion which have taken place in regard to the character of the disease. And we shall find that these changes have been due, not to the discovery of fresh facts, but to the different constructions placed upon observations entirely analogous to one another. For here, as in all other arguments upon matters not within the limits of mere abstract truth, the great point is to arrive at the exact relations of cause and effect. Owing, however, to the complicated conditions to be considered, this inquiry is peculiarly difficult in physiology, and still more so in pathology.

In order to study to the best advantage the subject now before us, we shall in the first place survey the facts at command, and then the views and theories hitherto based upon them; lastly, we shall seek to define the conclusions derivable from this examination.

The essential pathological condition to be investigated is, the occurrence of suppurative inflammation, generally at several points, in some organ or organs distant from the seat of a local inflammatory disorder; the former phenomenon being generally observed in one or more of the viscera, and without any apparent local cause, while the latter is apt to subside more or less completely, as if by a shifting or metastasis of the inflammation to a new locality.

Thus after an amputation, the discharge of pus from the stump is very apt to cease if this condition is set up; if it occurs in a puerperal woman, the lochial flow is diminished or altogether suspended. But such is not always the case; sometimes the suppuration still continues at its original seat, or is changed only in quality. However this may be, the pus deposited secondarily is apt to be quite healthy in its character; its formation is very rapid.

Phlebitis is a very common, if not an invariable element of the disorder;

Digitized by Google

it commences at the part primarily affected, and extends to a greater or less distance along the vein, usually, however, throughout its whole length. It manifests itself in the same way as when idiopathic.

Now the secondary inflammations of the viscera may stop short of suppuration, simply because death takes place at too early a period for this stage of the local process. But they inevitably terminate in it, and not in resolution, if life lasts long enough; the lymph effused is not plastic, but *pyogenic* in the true sense of that word. Another peculiarity consists in their circumscribed character; they do not tend, however near to one another, to inosculate. Each focus, like a boil on the skin, has its own centre from first to last. Of all the organs, the lungs are most commonly attacked in this way, and next perhaps the liver; the brain sometimes, but less frequently, and still more seldom the spleen. Cases are upon record in which abscesses were found in the kidneys, and one or two in which the heart was the seat of irregular purulent formations.

The general symptoms are those of irritation with debility. In some cases, there are no evidences of serious derangement of the system, until the chill which is apt to precede the febrile movement. But sometimes this symptom is only noticed after several days of depression of spirits, malaise, and gastric derangement; or even after signs of pulmonary or hepatic congestion have declared themselves decidedly. The chill may be of any grade and duration, and may or may not recur. The fever which ensues either has from its commencement, or takes on subsequently, the typhoid type; the pulse becomes excessively rapid, the face dusky, the abdomen meteoric; the teeth become covered with sordes, and the tongue dry and brown, or else smooth and red. Delirium is almost always, perhaps invariably present; it may be of the low and muttering kind, but sometimes there is wild excitement. Toward the last there is frequently vomiting of dark-brown matter, probably altered bile, which is ejected without much effort, often apparently without consciousness. Death seems to result from general exhaustion, much as in other cases of a typhoid type.

Two symptoms are sometimes observed in these cases, in a marked degree, without any condition being discoverable to account for them. At a very early stage of the disorder, even before the chill comes on, there may be acute pain, like that of rheumatism, about one or more of the joints; the wrist is often its seat. This pain may be premonitory of an abscess at the part, but is by no means invariably so. At a later period there may be an extremely marked jaundice, which is occasionally due to suppuration in the liver, but does not certainly indicate it.

The following notes of cases may serve to illustrate the sketch now given:—

Digitized by Google

CASE I.—*Purulent infection following a blow upon the toe; death on the eighth day. Autopsy.*

William Jones, aged 14, born in Philadelphia, was employed as errand-boy about a market-house. On Friday, June 11th, 1859, he struck the great toe of his left foot against a brick.

The skin was not broken, and he did not complain much until the following day, when the foot became intensely painful, red, and swollen. On the 13th he became delirious.

Leeches were freely applied to the foot, and a wash, composed probably of lead-water and laudanum.

On the 16th he was seen by my friend Dr. Dunton, to whom I am indebted for these notes. His left foot was of a livid-red color, hard, and much swollen, but cool. The limb above was hot, and there were patches of redness here and there in the course of the internal saphena vein; another patch of redness existed at the outer side of the right foot. He was delirious, with a hot skin, and a rapid and compressible pulse; his tongue was moist, but thickly coated; he had some cough, and frequent green liquid stools.

Lead-water and laudanum were applied locally, and he was ordered a mixture of Spts. Mindereri and Tr. Opii Camph., with a diet of milk and beef tea.

On the 17th, his left foot had assumed a dark-purplish color, as had also the spot on the right foot. A thick hard cord could be felt in the course of the internal saphena vein. He was much more delirious, and more prostrate; his diarrhœa was checked. He complained of pain in the left side when moved.

Additional stimulus was ordered, and Quiniæ Sulph. gr. j., every two hours.

He, however, sank steadily, and died very quietly at 10½ P.M. By the kindness of Dr. Dunton I assisted at the autopsy, seventeen hours after death. Body muscular and well developed; rigor mortis well pronounced. Both feet swollen and congested; the swelling extended up to the groin of the left side. Hypostatic congestion over nearly the whole of the posterior or under surface of the body and limbs.

On taking off the skull-cap, the dura mater was found somewhat adherent to its inner surface. Some bloody serum flowed out when the ventricles were laid open. The brain-substance was normally consistent, that of the left hemisphere somewhat congested.

Thorax.—Croupous lymph in both pleural cavities. The lungs presented, near their surfaces, foci of inflammation, of all sizes below that of a walnut; at the centres of a few of these suppuration seemed to be commencing. Heart healthy; normal clots in both cavities.

Digitized by Google

Abdomen.—Viscera and veins entirely normal.

The *left leg* was very carefully examined in reference to the state of the veins It was œdematous, and the internal saphena vein and its tributaries were distended with puruloid matter, their coats thickened and reddened. Here and there a very small vein was found filled with a red blood-clot; but, as a general rule, the distending substance was a yellowish matter, varying in consistence from that of pus to that of an ordinary clot. At the central portion of the vein was a clot about fifteen inches in length, tapering gradually at either extremity, and apparently breaking down into pus. At the point of entrance of the saphena vein into the femoral, a firm clot blocked up the passage completely. The femoral vein was perfectly healthy. A small collateral vein to the saphena, arising from it about two inches below its termination, and emptying into it again just at the latter point, was perfectly healthy, containing a red clot extending its whole length.

Just at the metatarso-phalangeal articulation of the left great toe was an abscess, laying bare the bone, but apparently not entering the joint.

CASE II.—*Secondary abscesses following amputation; death on the twenty-third day. Autopsy.*

This patient was a very muscular negro man, aged about 30. His right thigh was amputated by Dr. Norris, at the Pennsylvania Hospital, on the 24th of December, 1856; the operation was rendered necessary by a gun-shot fracture. A ligature was placed upon the vein.

After his death, the lungs were found full of small abscesses and foci of congestion; the heart very large, and the coronary veins distended; the liver very large, and universally congested; the spleen soft. On raising the pelvis, pus and blood flowed from the right iliac vein, apparently coming from both the femoral and the gluteal veins. During life, he had complained greatly of pain in the *left* shoulder-joint; but this was found to be perfectly healthy.

CASE III.—*Secondary abscesses following amputation; death on the twenty-seventh day. Autopsy.*

This patient was also a colored man, aged 35, whose feet had been frosted. His right leg was amputated January 21, 1857, by Dr. Peace, at the Pennsylvania Hospital. A great many ligatures were necessary, and one was applied to a vein.

After death, the lungs were found full of abscesses. The right femoral vein and its tributaries, except the saphena and the anterior tibial, were distended with pus. Although the skin and tissues were intensely yellow, the liver was perfectly healthy.

In this case, as well as in the last, the symptoms of purulent infection were manifested within twenty-four hours after the ligature came away

Digitized by Google

from the vein, which was in this case found to be patulous; its condition in the other was not noted.

The left popliteal vein was also full of pus; but it must be remembered that the left foot was also frost-bitten. Circumstances prevented a very thorough examination being made.

CASE IV.—*Abscess of the Liver following amputation; death on the twenty-first day. Autopsy.*

Michael McGorry, aged 21, had his wrist so badly crushed and luxated as to require amputation, which was done by Dr. Neill, at the Pennsylvania Hospital, August 3, 1856. Symptoms of purulent infection declared themselves in a few days, and he died on the 24th, three weeks after the operation.

A post-mortem examination showed a purulent deposit in the liver while the lungs were entirely healthy. The brain was congested, and there was some serous effusion in the ventricles. One kidney was very large and pale.

Dr. Hall* reported to this Society, in October last, a case of purulent infection following upon amputation of the upper arm. At the autopsy, pus was found in the veins of the stump; sero-purulent liquid existed in considerable quantity in the pleuræ and pericardium; the lungs were studded with small abscesses; the spleen was of a bright-red color, and at its lower portion presented a mass of gangrene the size of an egg; liver healthy.

CASE V.—*Purulent infection (?) following amputation; death on the sixteenth day. Autopsy.*

George Stouffer, aged about 30, an American farmer, was admitted into the Pennsylvania Hospital, July 25th, 1855, suffering from chronic disease of the left knee. For this his thigh was amputated by Dr. Pancoast, on the 1st of September. On the fourth day the stump was attacked with erythema. This was checked in a day or two; but on the eighth day each forearm became the seat of similar inflammation He now began to sink; he had several attacks of almost suffocating dyspnœa, from inability to throw off the mucus which collected constantly in his throat; and chemosis occurred to an extreme degree in both conjunctivæ. The stump shrank up very remarkably, and he died on the sixteenth day. He had had no marked chill at any time.

At the autopsy, tuberculous deposits were found in each lung, but no other visceral disease. On the back of each forearm, just above the wrist, was a subcutaneous abscess full of healthy pus.

---

* North Am. Med -Chir. Review, Jan., 1859, p. 96, or Proceedings of Path. Society of Philadelphia, p. 147 of the current volume.

Digitized by Google

CASE VI.—*Purulent infection following amputation; death on the tenth day.*

Sarah Ann Bush, aged 45, was admitted into the Pennsylvania Hospital on January 7th, 1856, for compound comminuted fracture of both bones of the left leg, close to the ankle. She was in the habit, according to her statement, of taking ʒiss of laudanum daily.

Amputation was performed by Dr. Peace, the same evening. Of course, it was absolutely necessary to administer opium in large doses, on account of her previous habits.

No bad symptom occurred until the seventh day, when she complained of great pain in the right wrist. The next evening she had a chill, and on the next day (the ninth after the operation) she became jaundiced. Stimuli were now given freely.

On the 17th, (the tenth day after the operation,) I was called to her early in the morning; found her with an anxious countenance and a tympanitic abdomen; the jaundice was extreme. Ordered an enema of turpentine; the other stimuli to be continued. At ten o'clock I was again called, and found her dying; vomiting up immense quantities of bile and undigested food, which flowed both from the nose and mouth, without any straining or effort.

Her friends would not allow any post-mortem examination to be made.

The foregoing cases are presented as exemplifying the course of the disease of which we have now to study the pathology. They are not all so complete as they might, or, perhaps, should have been—but it is one design of this paper to call attention to the subject, and to induce the pathologists of this country to give it more consideration than it has hitherto obtained; and the least full of the above records is still not without value in regard to some special point.

It is well known that abscesses in various parts of the body are apt to follow certain affections, such, for instance, as enteric fever; these local sequelæ usually occur at the surface, and seem to be a result of some specific influence of the preceding disease upon the blood. Of the extent and importance to which they may attain, the following case will be illustrative:—

CASE VII.—*Abscesses following enteric fever; recovery.*

Israel Braddock, aged about 35, a colored porter, came under my care in the latter part of September, 1858. His symptoms were at first such as might have indicated bilious-remittent, but in a few days they became clearly those of enteric fever. My friend Dr. Dunton attended him in consultation with me; he was for several days extremely ill, but at length showed signs of amendment.

During the seventh week of his disorder, he one day complained of pain

Digitized by Google

in the region of the left scapula. Upon examination, a very distinct fluctuation was perceptible at the spot; and an incision gave exit to an enormous quantity of thin but healthy pus.

Soon after this, he was removed to the Pennsylvania Hospital, where he remained until spring; several other abscesses of large size formed about his thighs and in his back, and it was for a long time doubtful whether he could survive the drain thus established upon his system. He, however, eventually regained his full health and strength, and was discharged cured.

We sometimes see abscesses form, after injuries of the extremities, at more or less remote points. These may be due simply to the inflammation of a lymphatic gland in direct connection with the part affected, although even then it becomes a question *how* the sympathetic action is induced; or they may be, to all appearance, independent of any such anatomical relation. Thus I have seen an enormous formation of pus, so large that it could hardly be ascribed to glandular inflammation, in the groin of a man whose toe had been crushed between two wheels; there was no free suppuration at the seat of injury.

But there are cases in which suppuration occurs secondarily, after injuries which would seem inadequate to such a result; of these the following case affords an example:—

CASE VIII.—*Purulent deposits following a slight injury of the knee; hectic fever, and death.*

George Bradshaw, aged about 45, was brought to the Pennsylvania Hospital, January 4th, 1856, having the day before slipped on the ice and strained his right knee. He had spent the night at a house close by where the accident happened, having been unable to walk; but there was no evidence of any injury to the joint. The thigh was slightly swollen, and somewhat erythematous.

He was a very large, stout Englishman, and had lived heartily, although, according to his statement, not intemperately.

It became evident, a few days after his admission, that an abscess was forming at the outer side of the thigh. This was freely opened, and exit given to a large quantity of pus. After this, several other abscesses formed, and were opened at different points along the thigh; then one occurred behind the knee; and, lastly, openings had to be made on each side of the leg. The orifices remained patulous, shreds of dead areolar tissue came away, and the discharge was very profuse. His strength began to give way, in spite of stimuli and nourishment; hectic fever set in at about the 1st of March, and on the 4th of April he died.

No autopsy could be obtained; but there had not been, from first to

Digitized by Google

last, the slightest indication of any other lesion than these abscesses in the intermuscular areolar tissue.

Let us now inquire into the opinions of authors upon the subject with the elucidation of which we are especially engaged at present. It would not be worth while to notice at length the speculations of those who wrote before the time of Harvey; but the following passage, from the introduction to the Second Book of Paré's Works, shows that that great surgeon had observed and reasoned upon these so-called metastatic abscesses:—

"Besides, also, which furthermore argues a great putrifaction of humours, many had Abscesses in parts opposite to their wounds, as in the left knee, when as the right shoulder was wounded; in the left arme, when as the right Leg was hurt. Which I remember befell the King of *Navarre*, the Duke of *Nevers*, the Lord *Rendan*, and divers others. For all men had nature so overcharged with abundance of vicious humours, that if it expelled not part thereof by impostumes to the habite of the body, it certainly otherwise disposed of it among the inner parts of the body; for, in dissecting dead bodies, wee observed that the Spleene, Liver, Lungs, and other Bowells were purulent, and hence it was that the patients, by reason of vapours sent from them to the heart, were troubled with continuall feavers."

Now, there are various ways in which the occurrence of secondary suppurations may be accounted for.

1. An explanation has been sought in the idea that when the head is injured by a blow, a fall, or a concussion of any kind, a like concussión is sustained by the liver or lungs, which may thus become inflamed, and suppurate. This view was defended chiefly, I believe, by Richerand; it is entirely set aside by the fact that in many cases no concussion whatever is sustained; as, for instance, when an amputation is the starting-point of the disorder.

2. The solidists, Desault, Bichat, and others, ascribed the phenomena in question to *sympathy;* a term which, although convenient, and sometimes even indispensable, is too vague to be of much value here.

3. The admixture of pus with the circulating blood, as a cause of metastatic abscesses, was I believe first mentioned by Boerhaave. His idea was that the pus became changed in quality by confinement, and that it eroded the extremities of the veins and lymphatics, so as to gain access to their interior. This idea of *pyæmia* has always obtained more or less favor among pathologists, but its acceptance does not close the discussion of the subject, since the greatest difference of opinion may still exist both as to the source and the mode of action of the pus. It is with these questions that we have now to deal.

Digitized by Google

But the very first inquiry to be made is, "What effect has pus upon blood when mixed with it?" To obtain an answer to this it is unnecessary to go beyond the experiments of Sédillot, who repeatedly injected large quantities of pus into the veins of dogs, without any marked effect; for if pus had the coagulating agency ascribed to it by some, or the absolutely poisonous action ascribed to it by others, the results must have been by no means negative. It is well known, also, that many writers maintain the possibility of the removal of even large deposits of pus by absorption; although it is difficult to perceive how any positive evidence of such an occurrence can be obtained. Very few surgeons, probably, will agree with Cruveilhier, when he goes so far as to say:—

"The absorption of pus, like that of all secreted liquids, is so much a part of nature's plan that I do not believe there is a single instance of the termination of inflammation without it."

On physiological grounds, however, the idea of any true absorption of pus may be rejected. Absorption is the entrance of any substance in the liquid form through a membrane, without any solution of continuity in the latter. Now, as Sédillot remarks, pus without corpuscles is not pus at all, and it is physically impossible for a pus-corpuscle to pass through the sound wall of a vein or of a lymphatic; while the experiments of this author have shown that the liquor puris is destitute of any injurious effect when introduced into the blood.

Pus, however, like all other animal matters, is subject to decomposition; and authors have asserted that its injurious effects are due to its putrescent state when taken into the blood. Two facts have a certain amount of weight against this idea; in the first place, metastatic abscesses do not always follow the injection of other putrid matters into the veins of animals, although typhoid symptoms and death are induced; in the second place, all the phenomena of pyæmia may occur in a case where the primary suppuration retains its laudable character. Hence it is necessary to seek the rationale of purulent infection elsewhere than in the mere admixture of pus with blood, or in the putrid condition of the former liquid.

A mechanical theory which has been advocated by some high authorities, is embodied in the word *metastasis; metastatic* abscesses being supposed to be caused by a transference of pus-corpuscles mixed with the blood to an interior organ, where they act as obstructions in the capillaries. Cruveilhier, having abandoned his original idea of the tubercular character of these secondary deposits, adopted the one just mentioned, and became, perhaps, its chief exponent. He introduced mercury in substance into the femur of a dog; some time afterwards he found it in the animal's lungs, each globule of mercury forming the centre of a small

Digitized by Google

abscess. When injected into the mesenteric vein, a like effect was produced in the liver. Hence he inferred that pus was similarly disposed of, and defended the following proposition :—

"Any foreign substance introduced bodily into the venous system, when its elimination by the emunctories is impossible, determines visceral abscesses exactly similar to such as supervene upon wounds and surgical operations, and these abscesses are the result of capillary phlebitis of those viscera."

The same view was defended by Mr. Simon, of London, as late as 1850. But it is entirely set aside by some considerations, the chief of which are, that it does not account for secondary abscesses in the areolar tissue, or in joints; that an organic cell would not, by lodging in a capillary, cause such an extensive interruption of the collateral circulation, whatever might occur if a foreign body were to lodge in like manner; and that such a theory leaves unexplained the rapidity, gravity, and peculiarity of the general symptoms.

Looking, however, at the clinical aspects of the subject, what evidence is there of the introduction of pus into the circulating blood in these cases? Here we must inquire whether pus can be detected, either by the naked eye or with the microscope, in the blood; for if so a great step may be gained. In the second of the cases already detailed, blood mixed with pus was seen to flow from the iliac vein. Piorry asserts that pus may even be detected in the blood drawn from pyæmic patients in venesection. But in the case just alluded to, the mixture of the two liquids was probably simply mechanical, and caused at the moment; Legallois, Dance, Sédillot, and others affirm that under other circumstances they could not be distinguished from one another.

Nor can we attain to any greater certainty by microscopic examination. Lebert's opinion, that there exists a visible difference between the pus-corpuscle and the colorless corpuscle of the blood, is entirely opposed to that of Virchow, Donné, and I believe of most other authorities on the subject. That the two cells are identical is by no means assumed, but only that they cannot be distinguished from one another with any certainty by their visible properties.

But admitting the *possibility* of the entrance of pus into the blood, does it *probably* take place in these cases?

To obtain an answer to this question we must first ascertain the source from which the pus might be derived. The idea of a simple transference of the pus from the part primarily affected has already been set aside, as well as that of a true absorption of it; but may not a small portion be taken up by an open vein, by what some writers have called a process of aspiration? Some cases would seem to favor this latter supposition,

Digitized by Google

which is, however, entirely overthrown by a single instance related by Bennett, in which the primary disorder was acute articular rheumatism.

Breschet, in 1817, first advanced the idea that a suppurative inflammation of the veins might furnish the pus by which the mass of the circulating blood was contaminated; and the convenience of this theory has recommended it in the eyes of many. Cruveilhier, indeed, goes so far as to say "*La phlébite domine toute la pathologie.*" Tessier, on the contrary, says that the word phlebitis has been a veritable nursery of error; affirming that whenever a vein is inflamed and suppurates, its communication with the rest of the circulatory apparatus is cut off, either by adhesive inflammation at its cardiac extremity, or by a plug of coagulated blood at the same point. Of the truth of this statement, the first of the cases I have detailed affords evidence; it is only one of a great many which are upon record. Moreover, in Bennett's case, before alluded to, all the symptoms of the so-called pyæmia occurred, but the veins were found, at the post-mortem examination, to be quite healthy. Bérard speaks of analogous cases. Tessier affirms positively that phlebitis is present in only five or six out of every ten cases of purulent infection, and argues strongly against the possibility of any relation of cause and effect between the two morbid conditions. In this opinion he is supported by Velpeau.

Phlebitis, on the other hand, does not by any means invariably cause metastatic abscesses. Duplay gives a series of eight cases in which the umbilical vein was inflamed, in children from two to twelve days old; peritonitis and icterus were constant symptoms, but there were no visceral abscesses, which he says do not ever occur in this form of disorder. In more advanced life, cases are not unfrequently met with in which the veins are inflamed, but no purulent infection ensues.

From the foregoing review of the opinions which have been advanced concerning the disorder in question, we see that neither transference nor absorption of pus can be accepted as the primary morbid phenomenon; and that phlebitis, although apparently offering a more substantial basis for theory, does not really stand the test of rigid examination. Authors have, therefore, been obliged to allege some additional cause for the symptoms observed, besides the mere admixture of pus with the blood. But this idea has so firmly seated itself in the minds of many, that they still allow it fundamental importance; thus Lebert assigns three periods to the disease: that of the formation of pus within the veins; that of the mixture of pus with the mass of the blood; and that of the pyogenic diathesis. Others again, having in view the analogy between the disorder in question and those caused by certain animal contagions—the plague, glanders, etc., speak of the blood as *poisoned;* but they still either express or imply the idea that it is the pus which constitutes the poison.

Digitized by Google

From what has been said, I think it will appear that there are defects in all the theories and hypotheses as yet put forth, in explanation of the occurrence of multiple abscesses after local injuries and surgical operations. Peculiar difficulties exist in tracing the phenomena of the disorder under consideration, so that the temptation is very strong to accept the most convenient doctrine, perhaps without sufficiently rigid scrutiny. It is probably for this reason that so many writers have defended views which a calm and impartial examination shows to be untenable.

Where, then, are pathologists of the present day to stand in regard to this most important affection? I beg to offer some considerations which may tend to a solution of the problem, although it may well be doubted whether its entire comprehension is within the power of the human mind.

In the first place, it is useless to attempt the task of accounting for the localization of such morbid actions as are due to constitutional causes. Thus the variolous poison gives rise to multiple abscesses in the skin; we know that such is the case, but we cannot go back of this fact. Nor can any one explain the mode in which the disease is communicated, when there is no actual contact between the person affected with it and the person receiving it. And so, also, that more strictly contagious disease, the glanders, is transmitted probably in the form of a material poison; but how or why that poison gives rise to the peculiar symptoms of the disease, no one can tell. It may be by a self-propagating power possessed by the poison, or by a catalytic influence upon the blood at large.

Again, after that clearly specific disease, enteric or typhoid fever, it is well known that abscesses are apt to occur here and there, without any local cause being assignable for them.

The simpler and much more frequent instance of boils and carbuncles may be adduced, as showing the effect of some inappreciable agent, (called, for the sake of convenience, a condition of the system,) in giving rise to suppurations apparently quite arbitrary in their choice of position. Every one knows that these may occur in persons seemingly in perfect health; and yet a tonic and stimulating regimen will often act most beneficially in such cases, showing that there was in reality a lowered and not an exalted condition of the vital powers.

Hence the process of suppuration, which may so commonly be traced to a local cause, may also be set up under the influence of agents modifying the constitution of the individual affected; whether these agents be considered as producing their effects through the nervous system, or by a taint impressed upon the circulating blood, or by altering the vital forces in amount or direction. In some cases, as has been seen, the action of a poison must be acknowledged; in others there is a state of the system at large, with which the local phenomena are obviously in connection; in

Digitized by Google

others again such a connection can be so clearly inferred as to admit of no reasonable doubt, although it cannot be demonstrated.

Now comparing these facts with those which have been brought forward with respect to secondary suppuration after surgical operations, injuries, or local inflammations, they may afford a clue to the real pathology of this affection. For here, as in the other cases mentioned—pustular skin diseases, abscesses after typhoid fever, boils, and carbuncles—there exists a constitutional state, to which the name of *purulent diathesis* has been applied. This name was first proposed, I believe, by Tessier; I would suggest the word *pyogenic* as more expressive of the idea intended.

The *purulent*, or *pyogenic diathesis*, then, I would consider as present wherever there is a marked tendency to suppurative inflammation; as is often seen in hospital residents, sailors on board ship, and others who are exposed to depressing influences. By the pathologists of the present day, inflammation is perhaps universally regarded as attended with an actual diminution of the vital powers of the part, and is known to occur more readily in persons whose health is impaired. Hence, a tendency to inflammation, and to its termination in suppuration, may be set up by the influence of any cause of such impairment; very often this agency operates for a length of time without exciting any suspicion of its existence.

An individual may be thus weakened, without losing the appearance of vigorous health. But under the additional depression incident upon an operation, or upon any serious disorder of the system, the diathesis may show itself by the development of a general typhoid state, cropping out here and there, also, in the shape of local suppurations. Such may be supposed to have been the order of things in Dr. Bennett's case, where the primary affection was acute articular rheumatism.

It may, however, be objected, that the diminution of the suppuration at the seat of injury or operation, or of the lochial discharge, when the parturient uterus is the starting-point, is opposed to the view stated. But this diminution does not always occur, and when it does, it may be accounted for by the transference of the inflammatory action to other points.

Again, it may be asked how the frequent existence of phlebitis, in these cases, is to be explained. That this is not the essence of the disorder, or even an invariable element of it, has already been argued. The inflammation of a circumscribed extent of any vein or veins may be looked upon, I think, as simply a coincidence, especially when the extreme readiness with which it takes place is borne in mind.

As to the experiments on animals, in which the phenomena of the affection we have been discussing were produced by the injection of putrid pus into the veins, they only show that this is one way in which the pyo-

Digitized by Google

genic diathesis may be set up. That it is not the only way, is shown by the many cases met with in which the pus of a stump or of a wound is perfectly healthy until the constitutional symptoms have declared themselves.

Lastly, it may be objected that the view I have advanced leaves some important points unexplained.

Thus it offers no account of the manner in which the suppurative action is localized, or of its limitation to certain circumscribed spots; and it substitutes a pathology which may seem vague and far-fetched, for one which is clear and easy of comprehension. But, as regards the first two points, this disease is only added to a very large list of those whose localization is altogether unaccountable, as well as the peculiarities of their phenomena. Who can pretend to explain why herpes zona never passes the median line of the body, or why lepra and psoriasis are so apt to attack the knees and elbows? Who can explain why vaccination causes a sore of a certain form, running a certain course? And as to the accusation of vagueness, it is set aside by the fact, that upon this theory the secondary suppurations which occur after injuries, operations, etc., are placed in the same category with those to which they are allied, instead of being left to stand by themselves, anomalies in pathology.

In view of the great frequency and fatality of secondary suppuration, it is surely surprising that the subject has attracted so little attention in this country. The idea which I have sought to defend—that such abscesses, occurring after injuries or operations, are due to a *pyogenic diathesis*, this being a state of system not without analogy under other circumstances—is, I think, a new one. If tenable, it may afford a sounder basis for prophylactic or curative measures than those which have preceded it; and in this way I hope it may be made practically useful.

A discussion then took place on the subject of pyæmia, in the course of which DR. WOODWARD remarked, that while he recognized the truth of what Dr. Packard had said with regard to the extreme difficulty of determining the existence of pus in blood as seen under the microscope—owing to the impossibility of discriminating between pus-corpuscles and the proper white corpuscles of the blood—still, in a case where these corpuscles are abnormally abundant, we can at least say that one of two conditions must be present: either the patient, from whom the blood has been drawn, is suffering under leukæmia, or there is pus mixed with the blood. To determine this the symptoms and history of the case must be taken into account, and can leave but little doubt as to the nature of the disorder. Dr. Woodward also instanced cases illustrative of the rapidity

Digitized by Google

with which pus might form, and spoke of the readiness with which, under certain conditions, it might enter into the circulation.

DR. PACKARD replied, that while he was fully sensible of the truth of all the remarks Dr. Woodward had offered, he did not think that the presence or absence of pus in the veins was of much practical importance as regards the disease in question, since it had been clearly shown that pus, when injected into the veins, does not produce pyæmia

DR. HENRY HARTSHORNE observed, that although the secretion of pus in organs distant from the seat of injury might often be owing to purely diathesic influences, without any distinct connection existing between the secreting centres, as suggested by Dr. Packard, still there were cases—and he instanced two as having fallen under his own observation—in which the neighboring lymphatics had become red and hard, first at the seat of injury, and in which this induration and redness had rapidly traveled along the course of the lymphatic vessels to a distant gland, which had suppurated. Such cases, he thought, must at least be allowed to be owing to continuous inflammation, if not to the direct conveyance of the pus from one suppurating centre to the other by means of the lymphatic vessel.

Digitized by Google

WEDNESDAY EVENING, Nov. 9th, 1859.

The President, DR. STILLÉ, in the Chair.

Morbid Growths occupying the Ventricles of the Larynx; Death from Suffocation.—DR. GROSS exhibited a larynx, in the ventricles of which were granulations. The specimen had been sent to him by Dr. H. W. Ducachet, with the following description:—

"The subject to whom the larynx formerly belonged was a mulatto man, of large frame, Felix by name, and aged about thirty-five at the time of his death. He was a coachman, living in the town of Arroyo, Porto Rico. I first saw him on the 25th of September, 1851, and his answers to the several questions I then put to him, though imperfect, will give a tolerable idea of his history before that time.

"About six years previous, while waiting for his master and family at a ball, he fell asleep on the box; it commenced to rain, and he was drenched to the skin, and contracted a severe cold, which confined him for some days to the house but not to the bed. He described his symptoms to me at that time as only those of a severe cold, with, however, a great deal of pain on swallowing. No physician was called to him then, his master not thinking him sick enough for it. He recovered, and resumed his duties at the end of a week; but from that time was never able to speak above a whisper. There was no cough when I first saw him, or afterwards, and his master assured me that the man never had had any. At the end of some months, the inability to speak loudly still continuing, medical aid was called in, but everything was tried without avail.

"When he presented himself to me he was apparently in perfect health, with a good appetite, no cough, and no pain; there was a slight hoarseness, and occasionally an 'uncomfortable sensation in the throat, which caused a desire to swallow.' I examined him thoroughly, but could discover nothing in his lungs indicative of disease; yet detected, on his taking a long breath, a hissing sound on expiration, which conveyed to my mind the impression of the existence of a stricture in the larynx, the exact position of which I was unable to determine satisfactorily to myself. I tried cauterizations internally with the nitrate of silver, and counter-irritation externally, besides many other remedies, too numerous to mention; but all without producing any amelioration of his symptoms, and finally abandoned the case, convinced in my own mind of the exceeding obscurity of the disorder.

"Once afterwards, in 1853, he applied to me, complaining, as he described it, of 'pain in his throat.' I ordered him a bran and mustard poultice,

Digitized by Google

on going to bed, and heard no more of him until the 12th of December, 1854, when I was called to him about four o'clock in the morning. I found him dying; he expired about half an hour after I reached the house. His wife told me that he had had a slight cold for several days, and had gone to bed early, with great difficulty of breathing. She gave him a foot-bath, and applied the poultice of bran and mustard to his throat, which, as she said, had given him relief during former similar attacks; but, falling asleep herself, she knew nothing of his condition until about half-past three o'clock, when she was awakened by his struggles.

"The autopsy showed his lungs to be in a perfectly healthy condition; so were all the abdominal viscera. The larynx was filled with a thick, ropy mucus, which had so wound itself around the membranous band which completely filled up the tube, as to cause the patient to die asphyxiated.

"I will add to the description given, that words could be heard tolerably well at a distance of not over three feet from him. There was not, at any time after I first saw him until his death, any perceptible increase or diminution in the strength of his voice; it was, in every sense of the word, a whisper."

DR. GROSS looked upon this as a most remarkable case. The morbid growth he believed to be coagulable lymph, the result of inflammation, and not a true polypus.

DR. STILLÉ thought the fact of the case having originated in cold pointed more toward a plastic exudation than to a polypoid growth.

DR. EDWARD HARTSHORNE stated, that in a case of laryngeal polypus which had come under his observation at the hospital, not only were the symptoms entirely different during life, but the post-mortem appearances were dissimilar. In the case to which he alluded the man had breathed for several years through a very small orifice, and had finally died suddenly from suffocation, with exactly such symptoms as attend a case of membranous croup. After death the larynx was found almost entirely closed, the orifice being scarcely large enough to admit a small probe.

Miliary Tubercle in the Lung; Tubercle of the Liver; Psoas Abscess; in a man seventy-six years of age.—DR. KELLER, in exhibiting these specimens, said:—

Mr. Ertel, seventy-six years of age, emigrated about fifteen years ago from Germany, and has since that time been employed in one of the great chemical factories in this city, where he was occupied with the manufacture of different chemical preparations. He had consulted me several times during past years for various ailments, but on the twenty-third of June of this year, for the first time, for a cold abscess of the size of the

Digitized by Google

fist, extending from the fourth to the sixth rib, on the right side, near to the sternal edge. I directed him to paint it with tincture of iodine, which he did for a short time; but not thinking that any treatment could relieve such an old and debilitated person, I soon lost sight of him. I was again called to see him on the sixteenth of October, when I found him in bed, very weak, and scarcely able to recognize me. His hands and feet were œdematous, his pulse at the wrist not perceptible. This condition had not changed on the next day. On the nineteenth day the œdema had disappeared; the pulse could be felt, but it was very feeble and irregular; the respiration was more difficult. He died during the following night. The post-mortem was performed on the twenty-second, by Dr. Packard, whose report I give:—

Autopsy, October 22.—The abscess being laid open, was found to contain several ounces of pus, and a good deal of semi-solid, cheesy matter, forming a sort of inclosure for it. The fourth rib was thickened about three inches on its sternal end; it was eroded, and could be felt at the bottom of the cavity. The sternum, with part of the aorta, was similarly affected, and fragile, like the denuded part of the rib.

Opposite this point, the lung was strongly adherent to the parietes of the chest, by means of bands of organized lymph. Toward its base, on its posterior surface, this lung was attached to the wall by a very thick and dense mass of the same character.

The right lung was congested with blood, and had miliary tubercles diffused everywhere throughout its substance; but it still swam in water. The other lung was adherent to the chest-walls by most of its surface; it was studded with miliary tubercles, and pieces of it sank instantly when dropped into water.

The two layers of pericardium were everywhere adherent, except on the under surface of the heart. The heart's substance was increased in bulk, but softened, and was found, under the microscope, to be in a state of fatty degeneration. On the left side both sets of valves were thickened, and ossific deposit had occurred in the subserous tissue forming the base of the valves. The coronary arteries were ossified to some extent.

The liver was enlarged, fatty, and anæmic, with points of tuberculous deposit here and there in its substance; one mass of this nature was of about the size of a chestnut, and seated at the under surface. Spleen soft and deep colored. Kidneys somewhat pale and flabby; on the surface of one of them was a whitish deposit, about as large as a grain of wheat, presenting no very marked microscopic characters.

The mesenteric glands were very much enlarged, hard, and converted into a white, cheesy material, exactly like that mentioned as found at the under surface of the liver.

Digitized by Google

In the right axilla three or four glands were enlarged, one to about the size of a large chestnut, the others in less degrees. These all exhibited the same change into a cheese-like material.

All these deposits, being placed under the microscope, were found to consist of small, irregularly shaped, but generally ovoidal cells, containing bright, oil-like particles, and many of them also a nucleus of comparatively large size, with one or two nucleoli.

In the psoas muscle, on the left side, there was an accurately limited abscess, laying bare a small portion of the fifth lumbar vertebra. The psoas muscle was diminished in volume, somewhat greenish in color, and of less than normal consistence. Under the microscope, it seemed to be breaking down, its elements were less distinct than usual, and appeared to be, as it were, dissolved.

Bright's Disease; Waxy Kidney.—DR. HARLAN exhibited, for Dr. Reed, a specimen of this disease, and read an account of the case:—

Frederic Smith, tailor, aged twenty, native of Germany, was admitted into the Pennsylvania Hospital, October 20th, 1859. He stated that, when about ten years old, he had had an attack of general dropsy, which yielded to rest and treatment in about three weeks, and that after his arrival in this country he had an attack which lasted about the same time, but was not followed by dropsy; his health had been good up to the commencement of the month. Since that time he has had dropsy, which he cannot satisfactorily account for; he believes it to be owing to a profuse perspiration which was suddenly checked. When examined on admission, he presented the waxy-white appearance peculiar to albuminuria. There was some effusion into the cavity of peritoneum; the urine was scanty and highly albuminous; the pulse small but regular; the tongue pale; the bowels costive and not easily operated upon; the appetite good. He was ordered to take diuretics; a diet nutritious but not stimulating, and hot vapor baths every other night.

On the seventh, Dr. Meigs showed the patient to the class. He notes: "Patient has passed about three pints of urine in the twenty-four hours. It is amber colored, specific gravity 1006 to 1008, and highly albuminous. The dropsy extends up around the loins and to the walls of the abdomen; the effusion into the abdomen is slight; there is also slight effusion into the right pleural sac. The dullness over the heart extends about two inches above the nipple, along the edge of sternum; the apex beat is feeble yet distinct. It contains small, waxy-looking casts, epithelial cells in abundance, and some blood. Heart probably pushed up by the diaphragm, as the abdomen is very considerably distended by flatus and fæcal accumulation; if any ascites, it is very moderate."

Digitized by Google

On the twenty-sixth of September, when I examined the case, the general condition of the patient had not varied much from the description given.

On the third of October, elaterium (one-eighth gr.) was ordered. This produced nausea and vomiting. As it had the desired effect upon the bowels (four to six stools in twenty-four hours) it was persevered in. The dose was repeated on the fifth, fifteenth, and eighteenth. About the fourth of October a peculiar venous congestion or stagnation was noticed in the epigastric vessels, and, to a slight extent, upon the thighs. This condition gradually increased until about ten days before death, when, simultaneously with the decrease of the œdema, the vessels were relieved.

About the seventeenth, the patient was suddenly attacked at night with torturing pains and swellings in the abdomen and thighs, which gradually extended down the limbs to the feet. It was impossible to touch his body without producing pain; and the weight of the bedclothes had to be supported by hoops. This condition, which seemed to resemble both phlebitis and inflammation of the lymphatics, was treated with Dover's powders, liniments, and bandages, and passed off in five or six days.

Following closely upon this was a decided loss of appetite. The bitart. potas. and infus. juniperi were put aside, and acetate of potas. and comp. spts. juniperi ordered instead. This was about the twenty-fourth of October. The œdematous condition daily diminished, and the abdomen, by the thirtieth of October, had assumed its natural dimensions. The swelling of the limbs was also partly lessened. The patient now refused solid food, and took milk-punch and soups; tonics did no good. On the thirtieth he was decidedly weaker, and brandy and water was ordered; after this he gradually became more and more prostrated, and died comatose on the thirtieth of November. The last six days of his life he complained of very severe pains in his bowels, and was kept but partially quiet by full doses of opium. Ten days before death a diarrhœa set in which proved intractable, and doubtlessly hastened the fatal result

Notes of post-mortem twelve hours after death. Brain not examined. Lungs have small tubercular deposits scattered through both; at top of left lung, posteriorly, is a small abscess containing a quantity of tubercular matter. The liver and spleen are normal or nearly so. Stomach and duodenum healthy. Pancreas has what seem to be tubercular matter in it; studding the internal surface of the ileum are a number of ulcerations, tubercular in character. Some of the mesenteric glands are enlarged, and, in some four or five, a hard deposit, like cast-off lime, is found. The kidneys are large and waxy. A subsequent examination showed that there was no abnormal amount of fatty degeneration, and

Digitized by Google

the whole case will perhaps most properly be regarded as the "waxy degeneration" of Dr. Todd. The amount of urine passed did not vary much through the treatment of case—from five to eight pints in the twenty-four hours.

In this case there certainly was not enough of tubercular disease to cause death. Patient died comatose, and for some hours before death his symptoms showed plainly the presence of urea in the blood. Perhaps his was one of those cases mentioned by Dr. Todd, where, although the normal amount of urine was secreted, yet the proper elimination of its elements did not take place.

During the whole progress of the disorder there seemed to be but little aggravation of general symptoms. Cough and bronchitis same throughout; pulse varied but slightly, 86 to 106; no headache; appetite generally good; amount and character of urine passed much the same; bowels operated on by medicines until the last two weeks of life. The post-mortem showed the lymphatic glands, which lay along the course of the iliac veins, very much enlarged and hardened. The pressure which these glands exert on these vessels may, perhaps, account for the great venous congestion of the external vessels of the abdomen and thighs. Certainly the amount of fluid in the peritoneum could not account for it. Though this explanation does not seem very plausible, yet it is an effort to account for one of the most singular and interesting complications of the case.

Fracture of the Anatomical Neck of the Humerus.—Exhibited by DR. LENOX HODGE. A few days ago, a muscular German, forty-three years of age, fell, about twenty-five feet, from a tree. He died the same afternoon, from injuries to his body and pelvis. The humerus gave every indication of being fractured through its anatomical neck. So it proved. The fracture extended from the tubercles above downward and inward along the neck, and below passed forward through the capsular ligament into the head. This was the principal line of fracture; at various points of its course several small fragments were split off.

Ossific Deposit in the Pleura.—DR. HODGE continued. Upon opening the thorax of the German, whose humerus has just been exhibited, we found extensive pleuritic adhesions, especially on the left side. We removed the lungs, and on the posterior surface of the left, between the pulmonary and costal pleuræ, we saw what appeared to be a portion of a rib. But, upon examination, we could detect no rib to be absent, or broken, or denuded of its periosteum. The deposit is of the consistence and appearance of bone, lies along the fissure between the lobes of the left lung, and is four and a quarter inches long, by one-half inch to three-quarter inch broad, and about one-eighth of an inch thick. It is closely adherent to both layers of the pleura, and, at its anterior extremity, seems to pro-

Digitized by Google

ject through the costal pleura, at least into the subserous areolar tissue. A small nodule of a similar deposit was found among the adhesions at the summit of the same lung.

Feeling the importance of ascertaining positively the nature of this deposit, I respectfully submit it to the action of the Society. Bone is often said to be deposited in the pleura after inflammations; but those cases in which a microscopical examination has been made, the deposits, though called ossific, osseous, or osteid,* have generally and perhaps always proved not to be true bone.

The specimen was referred, for minute examination, to a committee.

Tumor of Breast.—DR. LENOX HODGE next exhibited a mammary tumor. About three years ago, an abscess followed a contusion of the left breast of a married woman, twenty-seven years of age, and the mother of several children. The abscess opened, discharged, and the part returned, apparently, to a healthy state. One year afterwards, without any known cause, an abscess formed in the axilla of the same side. This also went through its stages and the parts returned to their normal condition. Last spring the patient gave birth to a child, which lived six days. She had plenty of milk; and, after the death of the child, her breasts dried up, without any untoward symptom. Then, however, she noticed, for the first time, a small tumor on her left breast, near the nipple, and felt shooting pains through it, especially during changes in the weather. There was no increase of size till the middle of September, when her husband died. Since then, it has increased rapidly, and become much more painful, so that, during the last two weeks, she has had almost constant pains, by night and by day. The tumor was removed this morning by Dr. Norris. It is large and hard, and with a marked retraction of the nipple. The skin is thickened, especially in points, forming hard nodules. Except, perhaps, its size, it presents the characteristics of scirrhus of the breast. A small tumor, of apparently the same nature, was found above this, and nearer the axilla. It also was removed. The axilla itself was unaffected.

DR. PACKARD stated that he had made a microscopical examination of a minute portion of the tumor, and that he had found it to consist of gland-tissue, tubes lined with epithelium, and imbedded in a fibrous stroma. He was desirous of studying it more thoroughly.

DR. WOODWARD thought the tumor resembled the lardaceous cancer described by Velpeau.

---

* Transactions of the Pathological Society of London; "Ossification of Pleura, by Dr. Bristowe, vol. ii. p. 35; "Ossific Mass deposited in the Pleura," by Dr. Hyde Salter, vol. v. p. 85; "Osteoid of the Femur, with Osteoid Growth in the Lungs, Omentum, and Diaphragm," by Dr. Hillier, M.B., vol. vi., 817. The Ostephytes, reported by Dr. J. Varise, (Archives Générales de Médecine, tome xxi. 4th S., pp. 320 and 448,) were not deposited in the pleura, but on the ribs by the periosteum.

Digitized by Google

WEDNESDAY EVENING, Nov. 23d, 1859.

The President in the Chair.

DR. PACKARD stated that he regarded the mammary tumor exhibited at the last meeting as in great measure made up of a structure similar to that of the healthy gland, with an unusually large quantity of fibrous tissue and free nuclei. The thickened and hardened portion of skin close to the nipple, examined in a section, presented a fibrillated appearance, with here and there what seemed to be coils of very fine fibres. In this mass there were also free nuclei, cells of various size, containing one or more nuclei also varying in size, and a few mother cells. Dr. Packard thought, therefore, that to the hypertrophied mammary gland there was superadded, as it were, a cancerous deposit.

DR. WOODWARD said that the portions of the tumor examined microscopically by him were small slices cut from various parts of the diseased mammary gland, and a slice from the greatly thickened and indurated skin near the nipple. In these he found the following conditions:—

Gland.—The whole stroma of the gland was the seat of an abundant new formation of connective tissue, as indicated by the presence of numerous spindle-shaped, embryonic elements. For the most part these elements were quite symmetrical and isomorphous with those of ordinary innocent connective tissue formations. When the cut surface of the gland was scraped, no creamy characteristic "juice" exuded, but the slightly turbid and richly albuminous liquid obtained presented the above elements with innumerable clear, transparent, free nuclei, and some extremely delicate dimly-granular nucleated cells.

The *nuclei*, many of which sufficiently resembled those of the healthy gland tissue, varied in diameter from $\frac{1}{200}$ to $\frac{1}{100}$ of a millimeter, or were even a little larger. Their nucleoli were sometimes dot-like, sometimes vesicular.

The *cells* inclosed similar nuclei, and were from one and a half to two or even three times the size of the nuclei.

When thin sections were carefully cut and examined it was found that though the larger milk-ducts were quite recognizable in many parts, the characteristic appearance of the gland tubules was much modified by the encroaching of the overgrown stroma. In no way could it be determined in any of the pieces examined that the lobules of the gland were hypertrophied; on the contrary, in many parts of these pieces they were almost wholly suppressed. In such sections irregular depots of small Aschersonian vesicles in great numbers could frequently be seen

Digitized by Google

in the interstices of the white fibrous bundles of the stroma. These depots were not found in all parts of any slice, but a slice half an inch square would always exhibit one or more patches characterized by the presence of many hundreds of such depots. This peculiar condition of its stroma is highly characteristic of the cancerous breast, and taken i connection with the history of the case, the external appearances of the morbid mass, and its anatomy thus far set forth, would compel the classification of this breast among the cancers.

But an examination of the *skin* which it will be remembered was continuous with the breast near the nipple, elsewhere separated from it by some normal adipose tissue, showed most significant conditions. The areolæ between the fibres of the corion were packed with nuclei and nucleated cells. The diseased skin was from one-fourth to one-half an inch or more thick. On scraping it a juice more turbid than that from the gland issued forth. In this were found, besides a few spindle-shaped elements, abundant huge *free nuclei*, $\frac{1}{100}$ to $\frac{2}{100}$ of a millimeter in diameter, containing large nucleoli, together with uni and bi-nucleated granular cells $\frac{1}{50}$ to $\frac{1}{25}$ of a millimeter in long diameter. In the diseased skin, therefore, as well as in the breast, a new formation of connective tissue was progressing But in the skin the unsymmetrical and distorted characters of the individual elements which stamp a connective tissue growth as cancer were well pronounced; not so in the breast, the whole minute anatomy of which nevertheless fully accords with the ideal of a carcinomatous affection. The difficulty of diagnosis in such cases as this arises out of the *slow development* of the individual elements as compared with the rapid and bulky growth of the whole morbid mass, in consequence of which the characters called cancerous are not profusely manifested especially in the gland tissue. And it is worthy of note that it is in cases more or less allied in minute anatomy to this, that microscopic diagnosis has most frequently failed in the hands of the heterologists.

He was therefore decidedly of the opinion that this growth was a cancer, and with all modesty, in view of the present imperfect state of our knowledge of the relation between the special anatomical characters of cancerous growth and the history of individual cases, would venture to express the conjecture that it will prove rapidly recurring and most malignant; an opinion based upon the past history of similar structural conditions observed in other cases.

DR. KELLER coincided with the views expressed by Dr. Packard regarding the nature of the tumor. He entered at some length into the question of the value of a specific cell as diagnostic of malignant growths, and alluded to the recent views of Rokitansky respecting the stroma of cancerous affections and their mode of growth.

Digitized by Google

Cancer of the Mesentery and of the Duodenum.—DR. HARLAN said:—The specimens on the table are from a German, aged thirty-two, who died in the Pennsylvania Hospital a week ago.

Unfortunately, his history previously to the date of admission is very unsatisfactory. He spoke but little English, and all that could be learned from him was that he had been employed in a sugar factory and continued steadily at his work, and in good health, up to six or eight months ago, when he began to fail in strength and flesh, and first noticed a tumor in his abdomen. It gave him but little pain until within about six weeks before he applied for admission to the hospital. Since this time he has always had pain across the abdomen varying in intensity.

At the time of his admission, on the thirty-first of October, he was much emaciated, had an anxious, haggard expression of countenance, and his skin and conjunctiva were of a deep-yellow color. His bowels were rather costive, the evacuations soft and very dark. The urine was natural in quantity, but deeply tinged with bile. In the upper part of the umbilical region, and extending into the epigastric, was a tumor apparently the size of an infant's head. It was very evident on superficial inspection, unyielding to the touch, and slightly movable. There was not much tenderness on pressure, and no tympanites, dropsy, or vomiting. The treatment was necessarily palliative, and consisted of the administration of opiates, tonics, and stimulants, and of occasional purges and injections; the latter gave most relief, and he used frequently to beg for their repetition. He became rapidly weaker and more emaciated. Toward the close of his life the pain was more intense, and the tenderness much greater, and two days before his death vomiting and slight tympanites were added to his symptoms.

A *post-mortem examination* was made fifteen hours after death. In the chest there were very firm pleuritic adhesions, but no signs of recent inflammation. The lungs were normal, with the exception of a deposition, in the lower part of the right, of the size of a small marble, and of nearly the consistence of cartilage. The abdominal viscera were almost glued into one mass by adhesions to each other and to a large tumor of the mesentery. There was a small amount of purulent fluid in the abdominal cavity. The liver, right kidney, pancreas, and spleen were apparently healthy. At the pyloric orifice of the stomach, on its inner surface, there was a tumor about four inches in diameter and an inch in its greatest thickness, with its surface depressed and its edges raised and inverted, and with some appearance of ulceration. The duodenum was firmly adherent to the liver, and a few inches from the stomach passed directly through the mesenteric tumor from side to side. This tumor, which is about six inches in its transverse diameter and four in its antero-poste-

Digitized by Google

rior, and irregular in surface when first taken from the body, had a deep-yellow color, and a consistence firmer than that of a healthy brain. There were a number of other tumors varying from the size of an orange to that of a walnut, some of them entirely surrounding the intestines and having small ulcerations on their inner surfaces. The calibre of the intestine was not perceptibly diminished by the tumors; in one instance it was decidedly increased. The left kidney contained a deposit apparently similar to the matter found in the mesentery. Specimens taken from the deposit in different parts presented the same microscopical appearances; a few spindle-shaped, but principally irregular, round, and oval cells with from one to three or four nuclei.

DR. HARRIS spoke of the extreme difficulty of making a correct diagnosis of abdominal tumors by palpation and percussion, particularly in relation to the primary seat of the disease, and related this case in proof:—

Some thirteen or fourteen years ago, I cannot say exactly when, as I have no written record of the case, I met with an instance of abdominal tumor in an Irishman about fifty years of age. The diseased growth occupied the left upper part of the umbilical region, was very hard to the touch, slightly movable, gave but little increase of pain upon pressure over what was at all times experienced, and handling it did not occasion any increased nausea. The prominence of the tumor was considerable, and the abdominal walls were lifted up above their natural level so as to make a projection as large as the half of an orange.

The prominent symptoms of the case were nausea with occasional vomiting, constant pain in the region of the tumor, entire loss of appetite, insomnia, and a red tongue deprived in spots of large patches of epithelium. Quite a number of eminent physicians saw this patient and made their conjectures as to the organ most affected by the diseased growth. Some supposed the stomach to be the chief site of the abnormal production; others seated the disease in the left extremity of the liver; another thought the spleen was the organ involved; another the pancreas; and another the left kidney. After some months of suffering the man died, and much interest was felt in the post-mortem examination on account of the various opinions which had been expressed with regard to the seat of the tumor. Concerning the nature of the malady but one opinion had been advanced, and that was, that it was cancer.

Autopsy.—The stomach was first examined and found healthy; the spleen proved to be normal in every respect; so also the liver, pancreas, and left kidney, which were all removed and dissected before the tumor was touched. The tumor itself was then particularly examined as to its attachments, and it proved to be an enlarged mesenteric gland, of an oval form, slightly flattened laterally, and nearly as large as the egg of

Digitized by Google

an ostrich. It had not given rise to any peritoneal inflammation, neither had it formed any adhesions to the viscera in contact with it. When more minutely inspected it proved to be scirrhus. The brain, heart, and lungs were not examined.

DR. WOODWARD called the attention of the Society to the difficulty in diagnosticating between abscesses in the abdominal walls and visceral tumors. He had had, not long ago, a patient under his care in whom a large swelling was felt in the neighborhood of the spleen, the true nature of which was not discovered until after the occurrence of a chill, and the evident signs of fluctuation in the mass. The tumor was for a long time hard and extremely resistant to the touch. The patient, a young woman, lost strength and flesh, and passed very uncomfortable nights. The idea was at one time entertained that the cause of all the suffering was a malignant tumor of the spleen, but rapid recovery and immediate relief from the more urgent symptoms took place after the discharge of a large quantity of laudable pus. The abscess when carefully probed was not found to communicate with the peritoneum.

DR. GROSS observed that abscesses which originated in the internal organs and opened externally might readily be mistaken for abscesses in the abdominal parietes. In doubtful cases, a careful examination of the matter evacuated was the only sure criterion as to whether or not the abdominal walls alone were implicated. He further thought, that if a surgeon were uncertain as to the nature of an abdominal tumor, it might be proper to pass an exploring needle.

DR. KELLER was of opinion that in cases of abdominal swelling even the exploring needle might be a fallacious guide, and related the following case of *distention of the bladder similating dropsical effusion, in which the bladder was punctured without evil results to the patient:*—

Mrs. B., about thirty-two years of age, and of uncommon fair hair and skin, had been delivered twice of large, healthy children, the youngest of which is now a boy three years of age. Four months ago she had a miscarriage, and was again three months pregnant when I was called to see her, on the twenty-eighth of July, on account of a sense of bearing down pain on the bladder, with an inability to pass water. I found a slight prolapsus vaginæ, and the membrane itself tense, as if some strong pressure were forcing it outward. In introducing the female catheter I had some spasmodic action to overcome, but the urine ran off freely after I had passed the whole length of the instrument. I repeated the same operation every day, and sometimes twice a day, until the first of August, when the patient assured me that she could urinate with ease. On the fourth of the month she complained again of vesical pain, and her digestion was disturbed and she had swelled feet. She showed me

Digitized by Google

half a chamberful of urine which had come from her during the night. On the left side of the pubis a large tumor could be felt; it was round, fluctuating, and of a real cystic nature. This swelling increased daily. On the twelfth of the month I examined the tumor, with a friend, to determine its true character—the tumor had grown to more than the size of a man's head; the upper end reached three inches above the umbilicus. In puncturing with the exploring needle we obtained a fluid coagulating when heated. A day or two afterwards I resorted again to the use of the catheter, notwithstanding the protestations of the patient that she was able to urinate, thinking that an empty bladder would certainly diminish the pressure on the surrounding parts. I introduced every day the catheter its entire length, and always drew off a great deal of water; after each introduction it seemed to me as if the tumor diminished. On the twentieth, I used a long gum-elastic catheter, in part to teach the patient how to use it herself and in part to see how far it would enter the bladder; its whole length entered, and more than double of the usual quantity of urine passed—in fact, nearly two small chambersful. The tumor very quickly disappeared. After this favorable result I introduced the catheter regularly myself every six hours; and for several days there was always a considerable quantity of urine passed after each introduction. By the twenty-seventh of the month the patient had perfectly recovered; she could pass her urine freely at will, and ate and slept well; the œdema of the lower extremities had entirely disappeared.

Report of Committee on Specimen of Ossification of the Pleura.—The committee to whom the specimen of bony deposit in the pleura, exhibited by Dr. H. Lenox Hodge, at the last meeting of the Society, was referred for examination, would respectfully report:—

That they found the position of the adventitious mass to correspond with the fissure between the two lobes of the left lung. The pulmonary pleura was adherent to the costal pleura, but could be dissected off; it was perfectly smooth and normal in appearance. The bony mass was enveloped in white fibrous tissue, thicker on its external than on its inner surface, the fibres being as it were radiated. As the costal pleura could not be dissected off from the inner surface of this fibrous envelope, to which, however, it could be traced, the mass seemed to be imbedded between the two layers of the pleura. Upon fracture of the osseous substance an outer compact shell was seen to inclose a cancelated structure, as in the long bones, and microscopical examination revealed the lacunæ and canaliculi of true bone.

JOHN H. PACKARD,
J. DACOSTA,
H. LENOX HODGE.

Digitized by Google

WEDNESDAY EVENING, Dec. 14th, 1859.

Vice-President, DR. EDWARD HARTSHORNE, in the Chair.

DR. DARRACH exhibited a drawing of elastic tissue found in the sputum of a phthisical patient, and spoke of the value of the microscope as an aid to diagnosis in doubtful cases of pulmonary affection. He had been enabled by its use, in the patient from whom he had obtained the sputum, to declare that a destructive disorder of the lungs was going on.

DR. MITCHELL presented specimens of cancer of the liver and lungs, and promised a detailed history of the case at the next meeting.

WEDNESDAY EVENING, Dec. 28th, 1859.

The President in the Chair.

Cancer of the Liver, Lungs, and Spleen, presenting peculiar Difficulties in Diagnosis.—DR. WEIR MITCHELL read the following:—

T. H., aged fifty-four, stationer and book vender. The patient, a person of spare habit, a hearty eater and of healthy frame—of a family generally healthy, with liability to dropsy late in life, probably from heart disease. His mother died of an affection supposed to be cancer of the face.

In the spring of 1856, I noticed on the palmar face of his hand a small wart, which was rather sore, and was soon accompanied by several others, which became prominent, and cracked, occasionally bleeding. When these tumors became half an inch or more high he consulted in succession several physicians, who pronounced them cancerous. At length, in June, 1859, he fell into the hands of a quack, who applied a plaster which sloughed off nearly two-thirds of the palmar face of the hand and laid bare the tendons. Greatly alarmed at the pain and suffering which ensued, he came to me. I employed cold water dressings only, under which the raw surface healed kindly, the hand being placed on a splint. Before the inner edge of the wound healed, a new formation of a character resembling those which had preceded it appeared on the inside of the hand. The new growth refused to heal, and was aggravated by every kind of dressing applied to it; I finally pared off the small tumor and cauterized its base.

On examination, its structure proved to be chiefly epithelial, with a firm sub-structure of simple fibrous tissue; and I was led to regard it as an epithelial formation, which outwardly and to the unassisted eye it also seemed to be. Its texture resembled that of a soft, cheesy wart, and was readily torn from base to apex; the little finger was so drawn down by the contracting cicatrice which had involved its flexor tendons that

Digitized by Google

it was quite useless, and as the epithelioma seemed disposed to extend, I consulted Dr. Brinton, who finally removed the little finger and half of its metacarpal bone. The wound healed readily.

On various occasions I had examined the patient as to his general health, and was always told that it was excellent, except that he had lost flesh from anxiety, and that he had had a slight cough for several years. Whenever at any time I examined his chest, he exhibited more or less evidence of bronchitis, but the percussion was everywhere even, and not merely clear, but uniformly resonant or tympanitic in tone. At the time of the operation, about November first, Drs. Brinton, Kane, and myself auscultated his heart, and were in some doubt as to the use of ether, because there was heard a faint mitral blowing sound. It was so trifling that it was not regarded as of enough moment to forbid the employment of the anæsthetic, which was therefore given with ordinary freedom. It will be observed that at this time the patient's bowels were regular, his digestion and appetite good, and that, up to the date of the operation, he was free from visceral pain or annoyance, and was neither jaundiced nor sallow. During the healing of the wound he complained of pain in the splenic region. This pain was very sharp, and was treated by Dr. Brinton, who blistered the region in question, and, I believe, altogether relieved him. On November twentieth he sent for me. I found him weak, with increase of his chronic coughing, especially at night. His sputa were yellow and green, like those of old bronchitis, and at no time had he any gelatinous or currant-jelly like expectoration. Upon close questioning, he complained of loss of appetite, and of having had, within two days, some diarrhœa. His tongue was thickly coated and yellow. At this time he was sent to bed and treated with stimulants and tonics, and with nutritive fluid diet. On the twenty-third, he had a rigor at 12 M., and one of slighter nature about 2 P.M. on the twenty-fourth. Each chill was succeeded by fever and sweat. On the twenty-fifth his pulse was 96, his respiration easy and rapid, his tongue more furred and dryer, his bowels costive. As soon as he was placed in bed I examined his belly with care; it was small and not distended. The veins were a little enlarged, and discharged their blood downward as usual. The liver dullness extended about an inch below the ribs in the right hypochondrium. Below the ensiform cartilage there was tympanitic clearness on percussion, and this extended downward into the usual region of clear percussion over the small intestines. To the left of this resonant epigastric space there was marked dullness, which could be traced down from the left curve of the ribs for about five inches, and thence along the border of the ribs toward the left side, where again was clear percussion. Thus, although the liver appeared enlarged, there

Digitized by Google

was a distinct band of clear percussion in the epigastric space, and as there was neither dropsy, jaundice, or want of bile in the stools, it was presumed that the dull percussion on the left must indicate a disease which could not be regarded as being connected with the liver.

As the case advanced, and the patient became emaciated, the left and middle part of the epigastric space exhibited at each inspiration a swelling which corresponded to the dullness on percussion above described. This prominence disappeared during expiration, and followed the motions of the diaphragm. It gave to eye and touch the impression of a circumscribed rounded tumor, lying between the liver and spleen, and having to its right side a clear percussion space, presumed to be due to the stomach, or, at all events, to indicate that to the right of this point lay the boundary of the enlarged liver. On the left side the usual percussion dullness marked the splenic region, below which the percussion was tympanitic.

The progress of the case was, from this time, a downward one. Without headache or local pains, or iliac gurgling, or tympanitis, or eruption, the case was plainly typhoidal, but not a typhoid fever. The bowels were costive throughout, and when moved, presented stools which were dark—or light colored at times—but not of typhoid aspect. The tongue was dry, dark, and coated, with a tendency to clean off and renew its epithelia from time to time.

The bronchial râles above alluded to were heard during his illness as they were in health, except that they became finer, especially at the back and lower half of the left lung, where the percussion was dull as compared with the same region on the right. This local dullness was only a comparative symptom, and had the part indicated alone been percussed, it would have been described as clear in tone.

After the thirteenth day these symptoms became more grave, and evening exacerbations were noticed, the pulse being 90 to 100 at the morning visit, (10 A.M.,) and 120 to 130 in the evening fever, which generally disappeared after 12 at night; both cheeks became red, and twice, I think, the fever was followed by some perspiration.

About the fourteenth day from the first chill delirium began to mark the height of the evening fever, and the patient at such time made violent efforts to leap out of bed.

This delirium was not seen in the daytime; for although the state of his mouth made thick his speech, when the words could be comprehended they were usually apt and correct.

On the fifteenth day the patient was worse; his pulse more rapid and more feeble. Emaciation increased, the tendons twitched, he plucked at the bedclothes, and lifted himself on his elbows, at the same time staring

Digitized by Google

about him. Meanwhile the face became pinched, cold local sweats broke from him, and, without much increase of tympanitis, without diarrhœa, and without convulsions, he died quietly on the evening of the eighteenth day from the time of the first chill.

But one point remains unnoticed. The urine examined before the fatal illness, and during it, exhibited no albumen at any time, and was never retained, or in any way the cause of annoyance.

On the last day of the illness the patient was seen by Dr. Da Costa, who agreed with me in regarding the case as a typhous condition, arising from some organic malady. We came to the conclusion that the tumor, which we could now feel and could limit by percussion, was in all probability omental. At this very time the chest percussion was emphatically clear, and even tympanitic, and the middle epigastric space was, as before, so distinctly tympanitic as to force us to note this clear spot as the right boundary of the tumor.

Post-mortem section by Dr. Kane, about twenty hours after death. Present, Dr. Da Costa and myself. Post-mortem rigor well marked. Body emaciated; no jaundice.

Abdomen.—Belly discolored. The locality of the swelling no longer prominent. On dividing the abdominal walls, the viscera were found to be singularly disarranged. The transverse colon was pushed downward and twice doubled in zigzag across the middle of the belly, as represented in the drawing made by Dr. Kane while the parts were undisturbed. The colon, which was dotted with dark-green oval spots, still lay above the small intestines which it had thrust down before it.

Fig. 11.

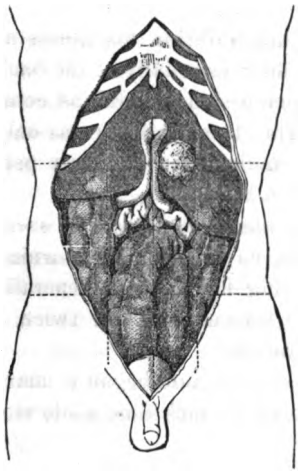

The cardiac end of the stomach was nearly in place, but the pylorus was pushed down so as to straighten out the small curvature of the stomach and place the larger part of the greater curvature in the left hypochondrium. The left end of the stomach lay therefore in the left hand V of the W formed by the dislocated colon; and had a plumb-line been dropped from the stomachal end of the œsophagus through the stomach, when the patient was erect, it must have fallen on or near the pyloric opening.

From the pylorus the duodenum turned abruptly up and to the right,

Digitized by Google

so that its first portion and a part of the jejunum lay in the epigastric region, within an inch or so of the end of the ensiform cartilage. This loop of intestine reposed in a deep furrow on the front surface of the liver. From this again the duodenum turned downward to end in the small intestines.

The liver, perhaps doubled in weight, descended on the right about one and a half inches below the ribs. In the epigastric region, across which it passed into the left hypochondrium, the organ was deeply indented, and from this notch ran backward a deep furrow in which lay the duodenum as above described; to the left of this furrow the liver descended below the ribs to some distance, and at this part was a large prominent encephaloid tumor about four inches in diameter.

On further inspection, four such masses were found in the liver, thus constituting the rarest of all the forms of hepatic cancer. The tissue of the liver was partially degenerated into fat, but in general the organ was normal. The gall-bladder was full, but not distended.

The spleen was small, and contained several small, soft, cancerous nodules. The pancreas and kidneys were healthy. The left supra-renal capsule had undergone degeneration, and was yellow without, and within full of a thin, brown, grumous matter, but not cancerous. The mesenteric glands near the liver were enlarged and cancerous, but elsewhere they were normal. The peritoneal cavity contained no fluid.

Thorax.—This cavity was observed by those present at the section to be singularly resonant on percussion. The heart was small and slightly affected with fatty metamorphosis. The valves closed perfectly; but one of the mitral curtains was irregularly thickened, and the ring from which spring the aortal valves was also a little more stiff and unyielding than usual.

The lungs were large. When removed they floated in water; wherever struck they emitted a clear, rather tympanitic sound. On incision they were found to be equally studded in every part with innumerable nodules of soft cancer of a yellowish-white tint, and varying from the size of a millet-seed to that of a walnut. Between these spots, which were in every half inch of the lung, or even nearer together, the lung tissue seemed healthy. More or less congestion existed between the cancer masses; but although this was more notable at the back and lower part of both lungs, neither in this nor in other situations was there any marked œdema of the pulmonary tissue.

So general was the distribution of the cancer, that it was impossible to say whether or not the lung was emphysematous. If it was so, the dilatations could not have been large. The pleural membrane was healthy, but some of the nodules raised its pulmonary layer into promi-

Digitized by Google

nences easily seen and felt before the lung tissue was incised. The blood was everywhere fluid and dark.

Remarks.—The case which I have reported is one of singular interest, and in some particulars will repay a comparison of symptoms with pathological appearances. The existence of a tumor in the abdomen was not suspected until the last illness. The only pain ever felt was in the left side, remote from the liver, and in despite of the great displacement of the viscera, the appetite and digestion remained good, and the fecal evacuations regular. There was no jaundice, or ascites, or œdema, and but a very slight enlargement of the abdominal cuticular veins. In despite of the utter absence of hepatic signs, or of symptoms of cancer of the liver, its presence might have been suspected after the existence of an abdominal tumor had been once ascertained, if it had not been for one circumstance. Whenever the belly was examined, a space of clear percussion was found in the middle epigastric space, so that it was supposed to mark the true limit of the dullness which existed over the tumor. As we have seen, this clear sound was owing to the duodenum and jejunum, which were drawn or forced up into the fissure formed on the right and left by the enlarged liver and covered in front by the anterior abdominal walls. It was physically necessary that this groove should be filled, and consequently the atmospheric pressure upon the more yielding portions of the belly seems to have driven into the void the intestines above referred to. Hence the clear sound and the error which, with the absence of pain, jaundice, and dropsy, induced us to refer the growth to other organs than the liver.

If the hepatic cancer had been more clearly expressed, it is probable that the general bronchitis might have been attributed to its correct cause. But of this even I am not sure; and I am certain that when a physician sees a general bronchitis with a clear and even percussion throughout both lungs, and with only occasional nocturnal dyspnœa, and when, moreover, a mitral murmur seems to explain this last symptom, under these circumstances, I say, few are likely to arrive at a correct diagnosis. The knowledge of the state of the liver was the only guide.

Dr. Walshe describes pulmonary cancer as thus characterized:—

Pain almost invariably present, and this due, at least such is his inference, to inflammation of the pleura. In my case there was no pleurisy and no pain, except temporarily, and late in the disease.

Dyspnœa is a very constant symptom. In this case it did occur at night, but was not very marked, and did not continuously affect the patient.

Cough was present in this as in all other cases of pulmonary cancer.

Digitized by Google

Unlike all cases of this kind, hitherto known to me, in this one the sputa was altogether uncharacteristic.

The decumbency in this as in most asthenic cases was dorsal during the last illness. Before this it was observed that the habit of health—sleeping on the right side—prevailed.

At page 348, Dr. Walshe recognizes the disseminated nodular form of cancer of the lung, even when the nodules are very numerous, as commonly giving rise to no symptoms, and as not usually altering the resonance of the chest.

This is also the case in some instances of acute tubercle, and in both diseases it is probably due to an emphysema developed *pari passu* with the constitutional and pulmonary malady.

Rupture of the Coronary Artery and Hemorrhage into the Pericardium.—DR. HARLAN, on exhibiting the heart, said:—

A sailor, twenty-two years of age, was admitted into the Pennsylvania Hospital on the second of December. He stated that he had been taken sick six or eight weeks ago at Havana, that no physician had seen him, but that his captain had pronounced the disease to be yellow fever. He never left his berth until the vessel came to port, when he was carried immediately to the hospital.

At the time of his admission he was much debilitated, complained of difficulty of breathing and a feeling of constriction across the chest; he had a frequent, feeble, and very irregular pulse; his bowels were costive, and his appetite poor. His lips were purple, and his skin was cold and damp. The area of dullness on percussion over the heart was much increased; the sounds of the organ were scarcely audible. There was dullness over the back of the chest, and egophony. His face was a little puffy, and there was some anasarca of the lower extremities.

In the course of a few days vomiting occurred, accompanied with epigastric tenderness and almost fatal prostration; it yielded temporarily to remedies, but recurred on several occasions, and each time left the patient more debilitated. The pericardial and pleural effusion continued to increase, and with it the dyspnœa and prostration. He died quite suddenly on the morning of December nineteenth, seventeen days after his admission into the hospital. A few minutes before death he took some wine from the nurse, who did not notice any change in his appearance.

Autopsy.—When the thorax was opened, the pericardium appeared to occupy nearly the whole of the left side, entirely concealing the left lung, which was compressed by it. The pleura contained a pint and a half of reddish fluid, but presented no signs of recent inflammation. The pericardium contained twenty ounces of a similar fluid and half a

Digitized by Google

pint of firmly coagulated blood. There was no rupture of any of the cavities, and the great vessels at their origin were sound. The pericardium was much thickened, and both its cardiac and reflected surfaces were nearly covered with an abundant deposit of coagulable lymph. The right side of the heart was attached to the pericardium by fibrous bands. At the base on the left side the marks of inflammation were most decided, the coating of lymph was thickest there, and the muscular tissue was softened; at one point there was a depression, presenting the appearance of a ragged ulceration and containing a piece of a clot. A probe passed gently into the coronary artery came out at this point, and, on cutting down upon it, the artery could be plainly seen to open directly into the pericardium.

So far as I have been able to learn, this case is unique. It is not a very uncommon thing to find fluid blood mingled with the pericardial effusion. In hemorrhagic states of the system there may be a passive hemorrhage from the pericardium, as there occasionally is from other serous surfaces. Lebert says that blood is sometimes found mingled with the hydrops pericardii in cases of general dropsy, especially of Bright's disease; and when inflammation attacks a newly organized false membrane, hemorrhage is said to result from the rupture of its tender vessels. In all these cases the blood is fluid and comparatively inconsiderable in amount, but a quantity of clotted blood must result from some decided organic lesion, and is an accident of much more rare occurrence. Under the head of "Anomalies of the Contents of the Pericardium," Rokitansky mentions "blood in a fluid or coagulated state," and says "that it is almost always an arterial extravasation, and has been deposited by the spontaneous rupture of the left ventricle or by a laceration of the origin of the aorta, occasionally as the termination of an aneurism." Lebert refers it to a rupture of one of the cavities of the heart, or of aneurism of the aorta, and mentions, as a very rare case, the rupture of an aneurism of the coronary artery. This is the only reference I can find to the coronary artery in connection with the presence of blood in the pericardium.

Though ulceration of the substance of the heart is considered an uncommon result of inflammation, it is well known to happen occasionally. Most cases of rupture of the cavities, according to Laennec, are the result of ulceration; and Hasse thinks that rupture of the heart is of a passive nature, and that, in many cases reported as spontaneous rupture, ulceration must have existed, though overlooked. Hope, Laennec, and Andral have all seen abscesses of the heart as the result of partial inflammation of its substance occurring in cases of pericarditis; and Hope says that ulcers are less rare than abscesses, though they generally com-

Digitized by Google

mence in the endocardium and extend outward. The appearances of the ulceration in this case were not very well marked; the edges were rugged and fused with the loose, shaggy deposits of lymph entangling pieces of clot; and if the progress of the ulcer had not been stopped before it reached the cavity, by death, it would very possibly have been overlooked, and the case reported as one of rupture from softening.

As the diagnosis of yellow fever has no other proof than the dictum of a sea-captain, the probability is that the heart was originally the seat of disease, and that the pathological changes were the result of an inflammation of two months' standing.

Typhoid Fever; Penetrating Ulcer.—DR. HARLAN next exhibited a penetrating ulcer of the intestine.

John Boyle, an Irish laborer, aged twenty-two, was admitted into the Pennsylvania Hospital, on the sixth of September last, for typhoid fever. There was nothing very remarkable about his case, except that the convalescence was unusually slow, and that he had several relapses without any assignable cause. He was treated with quinine and stimulants, and three weeks after admission was put upon the use of oil of turpentine, which was continued for about a month. His last relapse occurred in the latter part of October; since then he improved slowly until two weeks before death, when he was able to walk about the wards for a greater part of each day. His appetite was good, his tongue clean and moist, and his bowels were moved with remarkable regularity once a day, but there were always a dullness of intellect and an unnatural expression of countenance, which showed that all was not right; he always seemed like a sick man. On the evening of the sixteenth of December, when I made my visits to the wards, he was sitting as usual in his place, and said he felt pretty well. During the night he was attacked with pain in the abdomen, and the next morning I found him much prostrated, his pulse frequent and feeble, his abdomen slightly tympanitic and tender to the touch, his tongue brownish and perfectly dry, and his face and chest bathed in perspiration. On the morning of the eighteenth he was suddenly seized with vomiting, during which he died.

Autopsy ten hours after death. Lungs, heart, and kidneys healthy; liver slightly enlarged; spleen enlarged and softened; membranes of the brain congested—brain itself slightly so, but very firm. Peritoneum presented well-marked signs of recent and extensive inflammation. An accidental cut of the intestines prevented us from determining the existence of extravasation. Numerous ulcerations of Peyer's glands extending for four or five feet in close succession from the cæcum upward, many of them apparently undergoing the process of cicatrization. In

Digitized by Google

one ulcer, nearest the cæcum, there was a small oval perforation with smooth edges.

The point of interest in this case is the unusual length of time intervening between the commencement of the disease and death by perforation. Dr. Gerhard has never seen or heard of perforation after anything like so long a period, and the longest period that I can find, mentioned by Louis, is forty-two days. This man died three months and a half after he came to the hospital, most probably at least four months after the commencement of the disease.

DR. STILLÉ made some remarks with regard to the frequency with which the final perforation of the bowel was caused by imprudence in diet, and mentioned a case in which it had been brought about by the patient's eating a large quantity of ginger-bread, more than a month after the febrile symptoms had passed off.

DR. DA COSTA mentioned that a case had come under his notice, in which perforation had occurred after a lapse of seven months. The perforation followed the eating of a large quantity of chestnuts. The patient, a young man, had had a very severe attack of typhoid fever.

DR. LENOX HODGE exhibited an *Incised Wound of the Intestines*, taken from a patient who was brought to the Pennsylvania Hospital, December twenty-fourth, with a stab in the right inguinal region. About fourteen or sixteen inches of the small intestines, wounded in three places, protruded. These wounds were three-fourths of an inch in length, and partially closed by the everted mucous membrane. They were stitched with the continuous suture of silk, the intestine returned, and the external wound closed by the interrupted suture of lead, carried only through the skin. As soon as the gut was returned, the man, almost dead before, began to react. He lived for forty-two hours. There was a great effusion of fluid blood, at least three pints, in the peritoneal cavity.

Softening of the Right Side of the Brain; extensive Chronic Hydrocephalus on the Left Side.—DR. KELLER exhibited, through Dr. Packard, specimens of a cerebral lesion, and of atheromatous deposits in the arteries. Dr. S., fifty-one years of age, a bachelor from Germany, was, at six o'clock in the morning, at the beginning of February, seized with paralysis of the left arm and leg. He was a man of very regular habits, and of fanatical love for anything instructive; a great scholar in botany, geography, and languages, but deficient in those sciences which are not, for the most part, dependent on memory. The paralysis was soon relieved, and he was able, four weeks afterwards, to go out again and to use his arm tolerably well.

Digitized by Google

About the middle of March, in consequence of a fatiguing walk the previous evening at a late hour, and an attack of diarrhœa during the night, complete paralysis returned. The paralysis of the left arm and leg seemed to get somewhat better during the summer, but still the movements remained imperfect. As the weather got cooler the limbs contracted, and he was entirely unable to move in the least. In December his ideas became confused, and he died delirious, on the 26th of December, 1859, after eleven months' sickness.

Autopsy made by Dr. Packard twenty-four hours after death.—Body rigid. The bones of the cranium were thick and nowhere attached to the dura mater. A great deal of serum in the subarachnoid space and ventricles. Vessels of pia mater highly congested. Cerebral substance generally normal. Left ventricle very much enlarged, so as to extend over nearly the whole length of the cerebral hemisphere. Right ventricle of normal size, but in the corpus striatum of that side there was a cavity of the size of a marble, opening into the ventricle, and surrounded by a spot of softening of the cerebral substance about as large as an egg. Under the microscope, this softened brain-matter was found to present the pouching of the tubuli in a more marked degree than the adjacent portions did. It contained also numerous oil-drops, and a number of large, dark, conglomerate-looking corpuscles, such as are usually present in softened brain-substance. The basilar artery was completely blocked up with clots, as was also the right carotid. These vessels were atheromatous, and the basilar artery was aneurismally dilated. From their appearance, these clots seemed to have been formed some time previous to death. The heart was large and pale, and contained a very voluminous soft black clot, and some fluid blood. Under the microscope, it was seen to be very slightly fatty. Atheromatous patches in every stage of formation, and of every size, existed throughout the aorta, and in the iliacs as far as traced; all the arteries given off from the aorta presented the same change. At some of these patches in the aorta the internal coat was eroded. The valves of the heart were healthy, the bicuspid being, however, somewhat thickened. Lungs perfectly healthy, with very slight pleuritic adhesions at their apices. Liver very slightly fatty. Spleen and pancreas normal. Kidneys large and pale, and softer than usual, but without marked change. Supra-renal capsules separated from them by a large quantity of fat, and not satisfactorily examined. Intestines not examined; apparently normal.

Digitized by Google

WEDNESDAY EVENING, January 11th, 1860.

The President in the Chair.

Fused Kidneys.—DR. LENOX HODGE exhibited a large malformed kidney, consisting of two kidneys fused into one. It was taken from the body of a middle-aged man who died in the Pennsylvania Hospital, from traumatic meningitis.

The two kidneys were in reality perfectly normal, except that the pelves were directed more anteriorly than usual, and that their lower extremities were connected by a ribbon-like band passing across the vertebral column. There was no deviation from the usual position, as is so commonly the case.*

DR. DARRACH exhibited a tubercle the size of a marble, taken from the brain substance of a young girl who died of tubercular meningitis. Tubercles were found in the membranes of the brain and also in the lungs.

Universal Melanosis.—DR. GROSS, in exhibiting the specimens, said: The following case is one of unusual interest, from the almost universal diffusion of this morbid product. The number of similar instances upon record is very limited.

The patient, Elisha Chadick, aged fifty-eight, was a resident of Louisville; he was a stout, robust man, a pilot on the Ohio and Mississippi rivers, and first began to complain of indisposition in August, 1854. His attention was originally directed to the anus and rectum, in consequence of the existence of considerable pain and soreness, which induced him to believe that he was affected with internal hemorrhoids, an opinion somewhat strengthened by the fact that there was occasionally a slight discharge of blood. The symptoms steadily increasing, the general health at length gave way, and the man was obliged to take to his bed, which he never left until he died, a little upwards of a year from the commencement of his illness. The prominent symptoms, during the latter stages of his illness, were rapid emaciation and loss of strength, failure of appetite and sleep, an irritable state of the bladder, with a frequent desire to urinate, frequent discharges from the lower bowel of a

* See Dr. Morton's case, and Dr. Harris's remarks on it, in the Proceedings of this Society of May 12th, 1858.

Digitized by Google

mucous and bloody character, and considerable pulmonary and bronchial irritation, with occasional cough. The finger inserted into the rectum readily detected the presence of mechanical obstruction from some morbid growth, and bluish-looking tumors existed in the groin, and in the skin of different parts of the body.

The dissection was made by Professor T. G. Richardson and myself, nine hours after death. The body was excessively emaciated, and the hands, feet, and legs, were somewhat œdematous. The surface was studded with tubercles, upwards of fifty being counted on the abdomen, chest, and shoulders; a few also existed on the arms and legs, and one on the right temple. Ranging in size from a pea to a small hazel-nut, they were perfectly movable, of a flat, rounded, or spherical shape, and of a firm, gristly consistence. Most of them were situated in the subcutaneous cellular tissue, or in this tissue and in the substance of the skin. The largest, and apparently the oldest, were of a black color, the rest being whitish or grayish. The lymphatic ganglions of both groins were considerably enlarged, and of a black color; those on the right side being more deeply involved than the left. The axillary ganglions were similarly affected, only in a slighter degree.

The *omentum*, thickened and granulated, presented thousands of hard, black, shot-like tubercles, with here and there a whitish one, very vascular, and larger than the black.

The whole *peritoneal* surface, parietal as well as visceral, was studded with black tubercles, from the size of a small shot to that of an ordinary pea; very hard, flattened, and apparently developed in the subserous cellular substance, but projecting beyond the surrounding level. They were most abundant in the meso-rectum, on the ascending colon, and on the wall of the abdomen, opposite the liver. The diaphragmatic surface of the membrane, the stomach, and small intestines, were nearly free from disease. Upon laying open some of these tubercles, many of them were found to have a white central nucleus. No serous effusion existed in the peritoneal cavity.

The *liver* was of the normal size and weight, and, for the most part, of sound structure. A few small melanotic tubercles were seen upon its surface, just beneath its peritoneal investment. At the inferior border of the right lobe, by the side of the gall-bladder, were several black masses of a soft, pultaceous consistence, the largest being of the volume of a pullet's egg. Nearly a dozen small tumors, white and black, intermixed, and of scirrhous hardness, occupied the interior of the organ. The hepatic substance around these tumors did not appear to be materially affected.

The *gall-bladder* was somewhat larger than usual, and filled with vis-

Digitized by Google

cid, greenish bile. Upon its inner surface were a number of very small tubercles, seated in the submucous cellular tissue, and of a black color.

The *spleen* was of the natural volume and consistence, but its interior contained a broad lamellar body, of a whitish hue, and of a fibro-cartilaginous consistence.

The *pancreas* was considerably hypertrophied, and contained a large number of black tubercles, from the volume of a small shot to that of a small hickory-nut.

The *stomach*, which was of the natural size, contained a number of tubercles, all of small volume, hard, and more white than black. One or two of them were partially ulcerated. The pyloric and œsophageal extremities of the organ were healthy, as was also the *œsophagus* itself.

The *bowel* was carefully examined in its entire length. A few small black tubercles were found in the duodenum, and the upper portion of the jejunum. The ileum, ileo-cæcal valve and colon were sound, the latter containing healthy fæcal matter and some gas. The lower part of the rectum and anus were both much diseased, being of scirrhous hardness, melanotic, and ulcerated at the posterior surface. The anus was much contracted and very firm, the induration extending for a considerable distance around.

The *kidneys* were affected in different degrees. The left was one-third larger than natural, and rather distorted, numerous white and blackish tubercles being found both upon its surface and in its interior. The right organ was somewhat under the natural volume, and nearly sound, no cancerous deposits being discoverable. The ureters were healthy.

Both *supra-renal* capsules were deeply involved in the disease. The left was fully half as large as a sound adult kidney, very black, and much softened; the right was also much hypertrophied, black, and broken down.

The *urinary bladder*, containing about three ounces of turbid urine, was covered with small, black tubercles, lying in the subserous cellular and adipose tissues. Its inner surface was generally sound, but slightly fasciculated at the bas-fond, and presented five distinct characteristic tubercles, the largest about the size of a filbert. The walls of the organ were one-third of an inch in thickness, very hard, nodulated on the surface, and filled with white and blackish tubercles, the two substances being much blended. The superior extremity was more free from disease than the rest of the organ.

The *prostate gland*, very hard, and somewhat enlarged, was composed of a mixture of white and black substance, the greater amount of discoloration being in front. The organ was two inches and a quarter in

Digitized by Google

length, by two inches and an eighth in width, and one inch and an eighth in thickness.

The *seminal vesicles* had apparently undergone the fibrous degeneration, being very hard and dense, with hardly any remains of their natural cavity. They were free from melanotic deposits. The testicles were normal.

Finally, the *lymphatic ganglions* of the pelvis, especially those around the bladder, prostate gland, and rectum, were all in a state of enlargement, induration, and melanotic degeneration.

The *lungs* were deeply implicated in this remarkable disease. Black and white tubercles were numerously and extensively scattered over the outer surface of the right organ, which exhibited a linear, dark, mottled aspect, as is so often seen in health. The tubercles, which were situated in the subserous cellular substance, were hard and prominent, the largest being the size of a dime. The interior of the organ was crowded with similar bodies. The left lung, firmly and extensively attached to the ribs by ancient adhesions, contained tubercles similar to those in the right lung, but neither so large nor so numerous. Both costal *pleuræ* exhibited here and there, in their connecting tissues, small tubercles, both white and black. Their cavities, however, were free from serous effusion. The larynx, trachea, and bronchia were healthy.

The *bronchial* lymphatic ganglions were enlarged, indurated, and characteristically black.

The *heart*, which was of the normal bulk and weight, presented, both externally and internally, a number of black and white tubercles. The right auricle contained altogether about twenty of these bodies, some imbedded in its substance, others, and the largest, projecting from its surface. The smallest did not exceed the size of a mustard-seed. The greatest number were situated in the auricular appendage, in the pectiniform fibres. Most of them, especially the larger, were of a bluish color, a few only being white or grayish. Five similar bodies, some black and others white, were discovered in the right ventricle, among its fleshy columns, the largest being about the volume of a marrow-fat pea, and all very hard and dense. Five small, black tubercles also existed in the left ventricle, in and among the fleshy columns; and several were found in the left auricle, one externally and the other internally.

The *pericardium* was healthy, and no water was contained in its cavity.

The *aorta* was sound, except in its abdominal division, where there were distinct marks of earthy deposits and softening, with some degree of abnormal redness. The common iliac arteries were similarly affected, the left containing, in addition, a small melanotic spot, apparently situ-

Digitized by Google

ated in the subserous tissue. The vena cava presented nothing unusual.

The *thyroid gland*, considerably enlarged in bulk, and greatly indurated, contained a large amount of melanotic matter; the quantity being much greater on the right side than on the left, which was occupied with a great deal of white, crude substance.

The *brain* and spinal cord, eyes, bones, joints, and voluntary muscles were not examined, but there was no reason to believe, from anything that occurred during life, or during the progress of the dissection, that these several structures were at all implicated in the disease.

The peculiarities presented by this case are, first, the extensive distribution of the heterologous matter, constituting thus a kind of carcinomatous diathesis; secondly, the combination of melanosis with scirrhus; thirdly, the gradual wearing out of the system without any marked diagnostic symptoms as to the true nature of the disease, until the appearance of the bluish tubercles in the skin and groins; and, lastly, the fact that although there was the most complete disorganization of the supra-renal capsules, yet there was no bronzed appearance of the surface.

Fracture of the Spine.—DR. BRINTON directed the attention of the Society to a series of specimens removed from the body of a man who had recently died at the St. Joseph's Hospital, of this city. Some five months previous, the patient, a man about twenty-five years of age, had been accidentally struck on the back by a revolving fly-wheel. The result of this injury had been an impacted fracture of three dorsal vertebræ, and a luxation of the body of the sternum from the manubrium. Dr. Brinton exhibited casts of the parts, taken during life, and alluded to the extreme rarity of luxations occurring between the sternal bones. The further consideration of this injury, with a full history of the case and an account of the reputed parallel cases, he stated he would at some future time lay before the Society.

A discussion took place between several members of the Society, as to the amount, if any, of reparative process set up in the fractured vertebræ. The subject was finally referred to a committee.

Digitized by Google

WEDNESDAY EVENING, January 25th, 1860.

The President in the Chair.

Hypertrophy of the Prostate Gland.—This specimen was presented by DR. LENOX HODGE. The man from whom the specimen was taken was admitted into the hospital, for an acute attack of retention of urine. He was sixty-eight years of age; and, when received, was already in a low typhoid condition, from which he did not rally. He died on the sixth day. The urine always contained a large deposit of mucus and pus. A catheter was frequently passed into the bladder. By bearing in mind the probable enlargement of the middle lobe of the prostate, and the position of what was thought to be a false passage, this was readily effected. Upon the post-mortem examination it was found that the whole of the prostate gland was hypertrophied, especially the middle lobe, through the centre of which there was a false passage almost entering the bladder. The urethra, in the prostatic portion, was much dilated, and passed in front of and thus over, and also to the left of the middle lobe of the prostate. The walls of the bladder were hypertrophied and the ureters dilated.

Fibrous Tumor of the Left Labium.—DR. GROSS exhibited a large tumor, weighing upwards of three pounds, removed from the left labium of a colored woman twenty-six years of age. On section, a clear fluid oozed out. The appearance of the mass was that of a yellow substance resembling fat, intersected with large white bands. The swelling had been forming for upwards of two years and a half. It was the size of a child's head at full term, and occupied the left labium descending from between the vagina and the tuberosity of the ischium to nearly the middle of the thigh. It felt like a smooth, firm, and elastic body. The tumor was completely extirpated while the patient was under the influence of chloroform.

DR. HODGE mentioned a similar case which he had seen in the hospital, in which the tumor was pyriform, and attached by a pedicle to the left labium; it was even larger than the one exhibited by Dr. Gross. The diagnosis was a fibrous tumor; but the patient, a young married woman, refused to submit to an operation, and left the hospital.

Cancer of the Heart.—DR. GROSS presented a number of specimens of *encephaloid cancer* which had been taken after death from a child

Digitized by Google

six years of age, a patient of Dr. C. Osler, of this city. The only prominent symptoms in this case had been ascites, emaciation, and a tumor at the right side of the neck; no physical signs of disease of the heart were noticed. Post-mortem section, however, discovered masses of encephaloid tumors growing from the peritoneum epiploon mesenteric glands, pancreas, kidneys, and left auriculo-ventricular orifice. The stomach, supra-renal capsules, pleura, and liver were healthy; there was no hereditary predisposition to cancer.

Cancer of the Bladder.—DR. PACKARD exhibited a specimen of this affection removed from a patient of Dr. Dunton:—

Mrs. Young, aged forty-seven, American, housekeeper, had been sick four years, and had been complaining more or less for a year past. She has had occasional flooding, and pains in her back, a constant boring sensation in the uterus, and occasionally lancinating pains. The os uteri was tender on pressure; for some time past, bloody discharge came on irregularly. The bowels were constipated; the passages painful; the urine was free, somewhat frequent, occasionally bloody; general health tolerably good. The cervix uteri was hard and nodulated; the anterior lip elongated. No tumor was perceptible in the abdomen. No anodyne gave so much relief as meconate of morphia.

She finally became unable to pass water at all without the catheter. The patient was first seen in January, 1859; died, January 22, 1860.

Autopsy, made twenty-six hours after death.

Body pale; subcutaneous fat abundant.

Upon opening the abdomen, the bladder was found largely distended with blood-clots, and bound firmly to the anterior surface of the uterus. Its mucous membrane was studded with spots of cancerous deposit, of extremely variable size. Toward the left margin of the vesical triangle there was a small mass of villous cancer projecting up into the cavity of the organ. A small ulcer upon the surface of this mass had perhaps been the seat of the hemorrhage.

The uterus and ovaries were blended into a firm mass, two cysts posteriorly marking the respective sites of the ovaries. Between these two cysts, and bound somewhat firmly to the posterior surface of the uterus, ran the rectum, forming a double curve in front of the sacrum. The os uteri was very indistinct, the vagina shortened and much firmer in texture than normal.

The rectum seemed perfectly healthy; the small intestine was adherent at one point to the fundus of the uterus.

The ureters were very much distended with limpid urine, as if obstructed below. I was unable to detect any passage from them into the

Digitized by Google

bladder; their walls were thinned. The kidneys were atrophied, their calices and infundibula very largely distended, and their secreting structure greatly lessened in quantity. They were very pale—in fact, apparently almost bloodless.

The supra-renal capsules were the seat of a deposit, whitish, in distinct granules about as large as a pin's head, without any special microscopic characters.

The liver was healthy, but on its surface were half a dozen masses of cancerous deposit, of a clear white color, projecting somewhat. On the corresponding surface of the diaphragm were similar masses.

Pancreas, lungs, and spleen healthy.

Microscopic Examination.—All the cancerous deposits alluded to consisted of cells, generally ovoid, many of them pointed, of very various shapes and sizes, with large, nucleolated nuclei. Some of the cells contained two nuclei, some of the nuclei two or more nucleoli. Some of the cells were in a state of degeneration, having lost their contents, or at least having faded very much, and showing here and there a few small oil-drops.

FIG. 12.

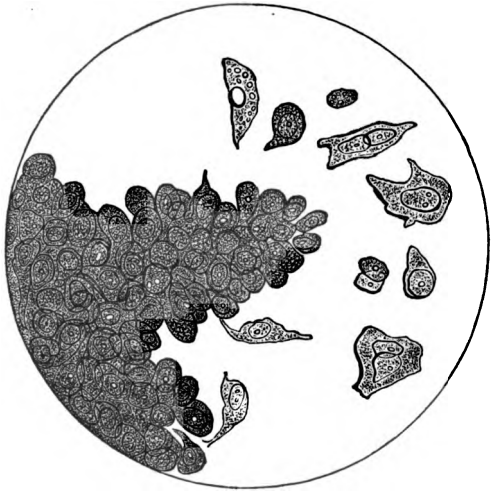

The fungous growth at the base of the bladder was seen, on letting the specimen lie in water, to be flocculent like the outer surface of the chorion. On examining these flocculi, they were found to consist of vessels with enormous numbers of cancer-cells, meshes of wavy and very fine fibres, and with projections very like the intestinal villi along their margins. These latter projections seemed to have a central stem, prob-

Digitized by Google

ably a loop of a capillary, around which were grouped the cells, generally attached by their smaller extremities, and strongly resembling tacks or iron-filings around the end of a magnet.

Such an arrangement as that just detailed is not mentioned, so far as I know, in any work on pathology. Wedl speaks of villous cancer, but describes the cells as lying parallel to the axes of the papillæ. Dr. Wilks, in his lectures on pathological anatomy, delivered at Guy's Hospital, London, and published in 1859, says that the villous character of a growth is secondary, and may be implanted either on an innocent or a cancerous tumor. He then goes on to describe a case of death from hematuria, in which what appeared like little tufts of moss were found growing from the mucous membrane of the bladder. When examined by the microscope, these "presented villous processes, and, what is very striking, as you may see in this drawing, which I made at the time, the surface is covered by columnar epithelium, long, battledore-shaped nucleated cells, very different from the ordinary epithelium of the bladder. Each villus, I should have said, contained loops of blood-vessels."

The drawing I have shown is in no way exaggerated.

The cyst corresponding to the left ovary being laid open, was found to contain about f℥ij of a reddish grumous liquid: abundant plates of cholesterine, granular cells, granules, and débris of organic matter, were detected in this liquid.

Digitized by Google

WEDNESDAY EVENING, February 8th, 1860.

The President in the Chair.

DR. DA COSTA presented the lungs of a woman who had died of phthisis. One lung contained many scattered tubercles in the lower lobe, and a very large cavity in the upper, sufficiently large indeed to have occasioned metallic phenomena during life. In the other lung there were only two or three very small tubercles.

DR. BRINTON exhibited a specimen of *extra-capsular impacted fracture* of the neck of the femur, occurring in a female aged eighty-four. This injury was the result of a fall on the hip, three weeks prior to the death of the patient. The prominent symptoms during life were shortening of the limb, eversion of the foot, and extreme rigidity. An examination of the specimen exhibited an irregular line of fracture extending obliquely across the bone, and splintering the great trochanter. The fractured extremity of the cervix was firmly impacted within the upper extremity of the shaft. No reparative action seemed to have been set up. Dr. Brinton made some remarks on the difficulty of diagnosis often met with in the occurrence of impacted fracture of this bone.

Wound of Left Ventricle of the Heart; Death thirty-six hours after Injury.—DR. LENOX HODGE said: On Wednesday afternoon, February first, H. W. was brought to the hospital, with a penetrating wound of the chest. It was said that he had been stabbed the evening before, and at the time had lost a large quantity of blood. At his admission he was cold, the pulse small and feeble, the respiration rapid, and his countenance expressive of great anxiety. The wound was situated between the fifth and sixth ribs, and a little to the left of the left nipple. It was an inch and a half in length; it penetrated forward, inward, and downward. Air and blood passed freely from and into the pleural cavity during respiration. There was no cough nor spitting of blood. The vesicular murmur could be heard, but the sound on percussion over the whole of the left side of the chest was dull, the action of the heart was feeble and irritable. The mind was perfectly clear. During the afternoon and evening the skin became warmer, but the other symptoms remained unchanged. About midnight, the pulse was still feeble, and he was unable to speak; then he became exceedingly restless, and continued to roll incessantly till morning. At 7.30 A.M. of Thursday, he was almost

Digitized by Google

pulseless and motionless, except his rapid breathing, and he died at 10 A.M. He lived, therefore, thirty-six hours after the reception of his injury, on Tuesday, at 10 P.M.

The post-mortem examination showed a wound situated as above stated, and passing forward, inward, and downward, through both surfaces of the pleura, the lower edge of the upper lobe of the lung, the pericardium, and into the left ventricle near the apex of the heart. The pleural cavity contained about 10 ounces of fluid blood, and some coagula. The pericardium was filled with about three ounces of bloody serum. The wound of the left ventricle was half an inch in length, and transverse to the external layer of muscular fibres. On the exterior surface of the heart the wound gaped about one-fourth of an inch, but within the sides were in contact. Upon opening the left ventricle, a little plug of lymph was seen among the columnæ carneæ over the wound, which, however, could not be found till a blunt probe was passed in from without. Only the lower corner of the wound, about one-eighth of an inch, entered the cavity of the ventricle. The pericardium was already injected, and covered with minute elevations.

Softening of the Fornix and Septum Lucidum; Fatty Degeneration of the Heart.—DR. KEATING said: I was called to attend Mr. H. D. B. on the twenty-eighth of December last. He was thirty-seven years old, and naturally of a strong constitution; had suffered on previous occasions from attacks of acute rheumatism, and was subject more or less to flying rheumatic pains, for which I had prescribed for him some weeks previous to his last illness.

Mr. B.'s health had been recently much impaired from mental distress consequent upon unsuccessful commercial operations, and he had been affected with general debility, which went on daily increasing. I had seen him on several occasions at my office, and prescribed for a hacking cough which had annoyed him considerably, and impaired his strength by the violence of the paroxysms, causing him constantly to void the contents of his stomach.

On the morning of the twenty-eighth, I found him suffering from general rheumatic pains, tongue coated, abdomen free from pain, and no fever. During the first two or three days he scarcely appeared ill, but was plunged into a profound melancholy.

On Saturday, the thirty-first, he seemed much relieved; the bowels had been freely opened, and although very much dejected, he was somewhat less gloomy than on previous visits.

On Monday, the second of January, he complained of a violent pain in the head, confined to the right frontal region, periodic in its character,

Digitized by Google

and so intense as to cause him to groan out with the agony he endured, and to entreat for remedies which would cause him to sleep. This frontal and facial pain, which seemed decidedly neuralgic in its nature, playing around the branches of the nerves of the forehead and face, originated at one time in the ear and in the eye of the right side, and always commenced about 7 P.M. and lasted till 4 A.M.; then came an interval of four or five hours with positive relief from suffering, but followed by excessive prostration. This periodical headache now seemed to be the prominent symptom in his case. For several days it baffled all attempts made to relieve it, and he was becoming rapidly exhausted from want of sleep and from the violence of the pain.

On Wednesday, the fourth instant, Dr. La Roche saw him with me; the intense headache was then somewhat relieved, but he complained of a severe pain down the spine, especially in the cervical region, and he described the pain at times as resembling electrical shocks. He was very restless; at one time getting up, anon lying down, and complaining of any sudden motion as aggravating the pain in the head, which was very much like an iron bar pressing upon his brain; tongue natural; no fever; pupils natural; respiration rather more frequent; action of heart more rapid, but weak, with a decided blowing sound during the second sound; secretions natural; great disinclination to talk; a general tremulousness of the muscles, and vision slightly impaired.

Thursday 5th.—The blister on the back of the neck, dressed with morphia, relieved all the spinal and frontal pain, and caused him to pass a comfortable night. Pupils more dilated, and do not respond to the light; countenance pale, sunken, and haggard; hands exceedingly tremulous; staggers in walking; complains of double vision; secretions natural; tongue slightly furred; pulse more frequent, rather weak, but no fever, and seems to depend upon excessive irritability of the heart. He seems very much dejected and apprehensive, and very feeble, the least movement increasing perceptibly the respiration and circulation. He still continues to rise every day and dress himself, and his appetite so far has been very good, seeming to enjoy all the food which is allowed him. During the evening of this day he was suddenly attacked with great restlessness and anxiety; his condition was so alarming as to cause his wife to send for Dr. Gerhard, who lived in his immediate vicinity. Dr. Gerhard, considering the attack as hysterical, prescribed an anodyne, which was attended with a happy result.

Friday, 6th.—Passed a sleepless night; does not complain of any particular pain, but seems much more depressed; speech is rather thick; forgets words; tremulousness of muscles of the whole body; is exceedingly restless, and has great difficulty in moving about, although he is

Digitized by Google

dressed and lies upon a lounge; tongue almost natural; pulse frequent, but not tense; breathing rapid; heart's action quick, but no force; face pale and haggard; conjunctivæ not the least injected; pupils dilated; double vision increased; has slight alienations of intellect, seeing strange figures near him, and discoursing on various subjects; bowels open by an enema; urine rather scanty, and contained a slight trace of albumen.

Saturday, 7th.—Tongue moist, slightly furred; pulse frequent; no fever; skin moist; spent a very restless night, constantly getting out of bed; pupils dilated; mind confused; some subsultus; double vision continues; complains that he is losing his mind; forgets words, and seems to have some difficulty in speaking; no paralysis of any portion of the body; fears that he is idiotic; has no particular pain; respiration frequent; his debility has increased; craves food, and takes it with pleasure.

9th, A.M.—This day he gradually grew worse; sleeplessness increased; incessant jactitation; double vision; pupils dilated; mind more and more confused; speech difficult; pulse frequent, but no heat of skin; face more haggard, with slight fever on the brow; tongue good; heart beats rapidly, but without force, and with distinct blowing sound; secretions generally natural; no costiveness; no paralysis; complains most of want of sleep, and excessive prostration; says the pain in the head is relieved; craves food, and enjoys it; continues to get up every day, dress himself, and to rest himself on the lounge in the back room; not much inclined to talk; remains in a partially comatose condition, but is easily roused, and, save for the loss of words and difficulty in speaking, seems quite intelligent.

His condition grew gradually worse, and he seemed to sink until Thursday, the twelfth, when his skin became hot and dry, and he had considerable fever; face flushed; pupils continue dilated; left eye a little more prominent; constant twitching of muscles; more comatose, and at times delirious; no paralysis; tongue more furred, and slightly red at edges; secretions almost natural. He now grew rapidly worse, and on Saturday, the fourteenth, presented all the symptoms of effusion having taken place on the brain; he became more comatose; great subsultus tendinum, threatening convulsions; could be roused, however, and gave some signs of intelligence until Monday night, up to which period he always arose to void his bowels, and always indicated his desire to pass water. He died on Tuesday, the seventeenth of January, at 3 P.M.

Autopsy, made by Dr. Packard, twenty-six hours after death.

The body was very muscular, and the subcutaneous fat abundant. The genital organs were extremely small.

On opening the *head*, the dura mater was found somewhat adherent to the skull-cap. In the subarachnoid space, at the upper surface of both

Digitized by Google

cerebral hemispheres, and at the outer surface of the left, were deposits of yellow lymph. The fissure of Sylvius, on each side, was obliterated by adhesions. Between the optic chiasm and the pituitary body, in front of the infundibulum, was a mass of tough lymph about the size of a large pea; the pituitary body was flattened down by its pressure.

The brain substance was somewhat congested; the anterior lobe of the left hemisphere was softened; the corpus callosum, fornix, and septum lucidum were softened to a very marked degree, the latter being partly broken down. Nothing abnormal was observed in the ventricles.

In front of the upper part of the cerebellum, just below the velum interpositum, and filling up the third ventricle to a considerable extent, was a mass of quite a firm substance, slightly lobulated, and crying under the knife. An artery which ran through this mass was found, upon microscopical examination, to be perfectly healthy.

The deposits now mentioned, being placed under the microscope, were found to be composed of lymph in various stages of organization, from mere fibrilation to completely formed fibrous tissue.

The *thorax* was next examined. Ossification had taken place in the costal cartilages. Both lungs were studded throughout with miliary tubercles; the right pleura was universally adherent. On the left side the fissure between the upper and lower lobes was complete, dividing the organ into two distinct portions. The heart was loaded with fat, and its muscular substance had undergone very marked fatty degeneration.

In the abdomen, the liver only was examined; it was somewhat fatty.

DR. HEWSON exhibited a fibrous tumor of the uterus, and tubercular ulcerations of the intestine, removed from the same patient.

DR. KEATING drew attention to the fact that, in cases of fibrous tumors, an icteroid tract was frequently present, which caused the case to be mistaken for cancer.

DR. LENOX HODGE stated that a similar observation had been made by Professor Hodge.

Digitized by Google

OCTOBER 28th, 1857.

DR. T. G. RICHARDSON exhibited the section of a bony tumor of the scrotum, and read the following history of the case, reported by Dr. John G. Kerr, late of Canton, China:—

The patient, a man twenty-eight years old, of sound constitution, and enjoying good health, was admitted into the Ophthalmic Hospital of Canton, China, in September, 1856.

Twenty months before his admission a tumor began to grow in his scrotum, which steadily increased until it had attained such a size as to be very inconvenient, and to interfere with his occupation, which was that of a laborer in the country. The tumor was about as large as an infant's head, and was so hard and dense as to feel like a mass of wood or stone inclosed within the skin. The integuments were healthy, and freely movable over all parts of the tumor.

The operation for its removal was performed by Dr. Geo. B. Newton, Assistant Surgeon of H. B. M. brig "Bittern."

The patient was placed under the influence of chloroform, and the tumor skillfully dissected away. The left testicle was carried down before the tumor, and was removed with it. Both testicles were healthy, with the exception of a slight hydrocele.

The weight of the tumor was five pounds. It was found to consist of numerous cartilaginous lobes of various sizes, densely compacted together with cellular tissue, in which large quantities of bone were deposited. When macerated and cleaned, it presented somewhat the appearance of a coral formation, springing from an irregular semicircular base. Numerous spiculæ of bone were scattered throughout the tumor where separate points of ossification had been established in the different lobules. So numerous were these spiculæ, that the knife could scarcely be thrust into the tumor without touching them.

A part of the bone has a compact outer plate, but the greater portion is spongy and cellular, and is composed of radiating spiculæ attached to a firmer base. The process of ossification was interrupted by the operation, and, as the tumor had not ceased growing, it is likely that the anomalous formation would have continued to enlarge indefinitely if it had not been removed.

Digitized by Google

FIG. 13 represents one-half of the bony deposit extracted from the mass by maceration. A microscopical examination of carefully prepared sections showed it to be true bone, with more or less perfectly formed corpuscles, canaliculi, and a considerable mass of granular matter.

FIG. 13.



No adequate cause could be discovered for the development of this tumor. The patient knew of no injury he had received in the parts. Not only was his general health good, but no alteration of the tissues of the scrotum had taken place.

Digitized by Google

NOVEMBER 25th, 1857.

Case of Fallopian Pregnancy, resulting in spontaneous rupture of the cyst within the first month of gestation, during a menstrual epoch, and terminating in death from internal hemorrhage.—DR. ROBERT P. HARRIS reported, through the Secretary, the following case, which had come under his observation:—

Mrs. S., aged twenty-seven, of medium height, full habit, and the mother of a child a year old, when apparently in the most perfect health, was suddenly seized with excruciating pain in the lower part of the abdomen, on the morning of the 24th of October, 1857, followed by extreme prostration. Her pulse became very rapid and feeble, extremities cold, and surface of the body very pale, indicating, that from some unknown cause, the patient was in all probability suffering under the effects of internal hemorrhage. Various restorative means were resorted to without avail; the pain gradually diminished, and finally ceased, the pulse became imperceptible, and the surface of the body cold, so that in a few hours it became apparent that the attack must necessarily prove fatal, which it did in twenty-one hours from its invasion.

Having diagnosed the case to be one of rupture of a Fallopian cyst, for reasons which will be hereafter given, I was extremely anxious to obtain permission to make a post-mortem examination, and thus satisfy myself of the correctness of my reasoning in the case. By refusing to write a certificate of death, on the ground of the uncertainty of its cause, after some hesitation, permission to make an autopsy was granted, and twenty-nine hours after death we entered upon the examination.

Autopsy.—Body well formed, inclining to *embonpoint;* skin remarkably white; abdomen distended and tympanitic. An incision through the linea alba showed an adipose deposit between the skin and fascia, of an inch to an inch and a half in thickness. Large and small intestine much distended with flatus, but otherwise healthy; other abdominal viscera in a healthy state. Upon elevating the intestines from the brim of the pelvis, its cavity and the lower back part of the cavity of the abdomen were found to be filled with black blood, in a partly fluid, partly coagulated state. After this was removed by the hand and sponge, to the amount of perhaps half a gallon, a small abnormal growth in the course of the right Fallopian tube arrested our attention, and caused us to dissect out and carefully remove the uterus with its appendages.

Digitized by Google

The uterus proved to be scarcely if at all enlarged beyond the size we usually find it in healthy women who have borne children. Its cavity contained a little mucus slightly tinged with blood, but no trace of a membrana decidua; the ovaries were healthy, of normal size, but very pale in color, and the left Fallopian tube presented nothing unusual, but in the right one, immediately above the ovary, was a tumor of an oval form, slightly flattened antero-posteriorly, about an inch and a quarter long, an inch in its vertical diameter, and of a reddish-blue color. Upon a close examination, a small opening of a little more than a line in diameter was detected at its upper surface, perforating the edge of the broad ligament. An incision made through the cortical portion, so as to divide the body to its centre, revealed a cavity containing a small diaphonous sac, within which was a human embryo of a pure-white color, and half an inch in length, looking a good deal like a common maggot.

Here then was clearly revealed the cause of death; and the supposition with regard to the nature of the attack proved to be correct. An ovum had become arrested in its progress from the ovary to the cavity of the uterus, had become partly developed in its abnormal situation, and when it had attained the age of three or four weeks had bursted, thereby making a direct communication between its blood-vessels and the cavity of the abdomen; and the patient had died of internal hemorrhage. This Fallopian cyst had no doubt much diminished in size between the moment of its rupture and the death of the patient, and the perforation consequently contracted, as it would naturally diminish somewhat after the force of the discharging current of blood began to decrease. This would account for the sudden prostration that took place at the commencement of the hemorrhage, as well as for the length of time that the patient lived after it became evident that her case was a hopeless one. The chief peculiarity of the case was the very early age in the development of the ovum at which the rupture took place, a shorter time after conception than in any instance of similar accident that I have met with in works upon extra-uterine pregnancy, or in the medical journals.

In determining the nature of the disease which had caused the death of the patient whose case is recorded in these lines, I was led to reason in this way. Here is a lady in full habit, whose health for some months past has been excellent, and the age of whose infant renders it highly probably that she may have again conceived, suddenly prostrated by an attack of disease the nature of which is to a certain extent obscure, but the prominent symptoms lead one to believe that she is bleeding to death internally, and the manner of the commencement of the attack, that the blood is escaping into the cavity of the abdomen low down, and

Digitized by Google

probably into the pelvis. Where does this bleeding proceed from? Can it be from a perforation of the intestine? No, for although for a considerable period before and after the birth of her infant she suffered with a constant diarrhœa, all trace of disease of the intestines must have for some time disappeared, for there have been no symptoms of any disorder of the alimentary canal for several months, and the patient has become quite fat. Besides, there has not, as in many cases of ulceration and consequent hemorrhage, been any escape of blood per rectum. Is the patient pregnant? She believes that she is not, because she had her menses upon her when the attack commenced. But this does not prove the non-existence of extra-uterine pregnancy, as many cases which have been recorded show that the menstrual function is frequently not affected by preternatural pregnancies. The os uteri when examined by the touch is very sensitive, which is often the case in disease of the uterine appendages, but is no positive indication of the existence of any lesion, because menstruation of itself sometimes increases the nervous sensibility of the uterus. The nature of the pain experienced, the suddenness of the attack, the situation of the pain, the evidence of a sudden and continued discharge of blood commencing directly after the pain was first felt, the absence of any previous symptoms of disease of the intestines or other abdominal viscera, the occurrence of the attack during a menstrual period when a determination of blood toward the pelvic viscera might favor such an attack, together with the fact that the symptoms of the case closely resembled those of many recorded cases of rupture of extra-uterine cysts, led me to the conclusion that the cause of hemorrhage was the rupture of an extra-uterine fecundated cyst. Having determined in my mind the nature of the disease, I was led to fix its probable seat in the Fallopian tube, from the frequency of tubal as compared with the other forms of preternatural pregnancy, and from the fact that cysts so seated are more apt to give way early than those in less constrained situations. The entire absence of any sensation in the pelvis previous to the rupture would favor the supposition of the fœtation being tubal, as ovarian pregnancy, from the greater sensitiveness of the organ involved, is apt to give rise to pain in the region of the ovary, and to a more early suspicion of the existence of disease. As there was no suppression of the menses in this case, there were no means by which the duration of the pregnancy could have been even suspected anterior to death, unless it could have been proven that impregnation had been impossible in this instance, until after the return of the menses.

Digitized by Google

INDEX.

Abdomen, fibrous tumor of, 48, 189; myeloid tumor of, 190.
Agnew, D. H., cancer of pancreas, 84; dilatation of meningeal artery, 88, 136.
Aorta, aneurism of, 40, 202; aneurism of, bursting into a bronchus, 63; bursting externally, 86; bursting into the pleura, 208.
Arthritis, chronic rheumatic, 15, 75.
Astragalus, discharge of, 74.

Bell, J. F., imperforate rectum, 89.
Black vomit, microscopic examinations of, 158.
Bladder, gangrene of, 6; hypertrophy of muscular coat of, 185; hernia and dilatation of, 186; cancer of, 199, 292; puncture of for supposed dropsical effusion, 273.
Bone, eburnation of, in chronic rheumatic arthritis, 15.
Brain, apoplexy of after trephining, 22; softening of convolutions of, 37; inflammation of membranes of, in a tuberculous patient, 68; abscess of, 100, 138; tubercles in, 143; inflammation of, in delirium tremens, 186; apoplexy of ventricles of, 196; apoplexy of, 222; softening of right side of, 284; fornix of, 296.
Breast, cancer of, 210; rapidly recurring, 228, 268, 269.
Brinton, John H., cases of chronic rheumatic arthritis, 75.

Calculus, urinary, 21; biliary, impacted in ducts, 26; vesical, mace-shaped, 27, 31; urinary, in a child, 87.
Cancer in a cicatrix, 82.
Cervical vertebræ, fracture of, 17.
Clavicle, intra-uterine fracture of, 212.
Cornea of an ox, hairy mole on, 26.
Cranium, fracture of, 214.
Cysts over nasal bones, 74.

Da Costa, J. M., cancer of pancreas, 8; observations on and collection of cases of, *id.* 109; apoplexy of lung, 19; wounds of heart, 172; observations on M. Groux's case, 203.
Darby, J. T., perforation of aortic valves, 96; cancer of bladder, 199; cancer of uterus, 200.
Darrach, J., hairy mole on cornea of an ox, 26; cases of chronic Bright's disease of kidney, 29; mace-shaped vesicle calculus, 31; gray hepatization of lung, 42; cancer of omentum, 43, 152; of right testicle, 45; malformation of heart, 53; encephaloid of kidney, 55; cancer of lung and mesenteric glands, 83; fibroid degeneration, 94.
Diabetes, examination of brain in, 71; connected with cirrhosis of liver, 72.

Fallopian case of pregnancy, 302.
Femur, deformity of neck of, simulating fracture, 18; head of, removed by excision, 27.
Forbes, W. S., urinary calculus, 21; aneurism of aorta, 63; subclavian aneurism, 177.

Gall-bladder, fistula of, 5.
Gangrene from arterial obstruction, 162; of groin, idiopathic, 164.
Gross, S. D., post-mortem softening of stomach, 12; fungus of testicle, 13; apoplexy of brain after trephining, 22; exostosis of scapula, 34; aneurism of arch of aorta, 40; fibrous tumor of abdomen, 48, 189; tubercle of kidney, 48, 136; cancer of omentum, 65; abscess of, 100; hypertrophy of bladder, 185; cancer of breast, 208; growths in larynx, 262; melanosis, 286; cancer of labium, 291.
Gross, S. W., cysts of thyroid gland, 106; cancer of breast, 228.

Digitized by Google

HALL, A. D., gangrene of bladder, 6; suppuration of kidney, 49; ulceration of larynx, 98; gangrene of spleen, 147; ossification of splenic artery, 157; cancer of pylorus, 169; pericarditis, 219.
Hammond, W. A., case of gunshot wound, 222.
Hand, cancer of, 198.
Harlan, G. C., rupture of spleen, 161; cases of wounds of liver, 224; cancer of mesentery, 271; rupture of coronary artery, 281; perforating ulcer of intestine, 283.
Harris, R. P., fatty degeneration of pancreas, 46; observations on single kidney, 79; cancer of uterus, 101; twisted umbilical cord, 183; Fallopian pregnancy, 302.
Hartshorne, H., gangrene, 162.
Heart, insufficiency of tricuspid valves, 52; malformation of, 53; perforation of aortic valves of, 96; wounds of, 172, 295; concentric hypertrophy of, 175, 214, 220; rupture of coronary artery, 281; cancer of, 291.
Heart-clots, 10.
Hernia, strangulated, 38; inguinal, 193.
Hewson, A., head of femur removed by excision, 27, 138; cancer in a cicatrix, 32; fatty degeneration of suprarenal capsules, 61; syphilitic retinitis, 70; serous apoplexy of retina, 92; cancer of liver, 156; idiopathic gangrene of groin, 164; strangulated hernia, 187.
Hodge, H. Lenox, wounds of intestine, 174; of heart, 295; hernia of bladder, 186; meningitis, 186; tubercle in liver, 140; cancer of hand, 198; fracture of skull, 214; gunshot wound of neck, 221; partial fractures of ulna, 232; fracture of cervix humeri, 267; ossific deposit in pleura, 267; cancer of breast, 268.
Humerus, fracture of anatomical neck of, 267.
Humphreys, G. H., aneurism of innominate artery, 42.
Hutchinson, J., astragalus discharged, 74; tubercle of kidney, 95, 231; abscess in liver, 139; abscess in brain, 138; thickening of peritoneum, 241.

ILEO-CŒCAL valve, cancerous stricture of, 22.
Innominate artery, aneurism of, 42.
Intestine, incised wounds of, 174; cystic growths on, 138; strangulation of, 237; chronic inflammation of, 243; perforating ulcer of, 283.

KANE, J. K., disease of heart, 214.
Keating, W. V., cancer of liver, etc., 11; fibrous tumor of uterus, 58; ulcer of stomach, 141; softening of brain, 296.
Keller W., cystic tumor of nates, 15; severance of cervix uteri during labor, 17, 235; stricture of ileo-cœcal valve, 22; intra-uterine fracture of clavicle, 212; tubercle of liver, 268; distension of bladder, 273; softening of brain, 284.
Kidneys, cancer of, 25, 55; chronic Bright's disease, 29; suppuration of, 49, 61; tubercle of, 48, 95, 136, 231; fibroid degeneration of, 62, 94; fusion of, 77, 286; observations on, 79; small, 201; waxy, 265.
King, W., cancer of supra-renal capsules, 153.

LABIUM, fibrous tumor of, 291.
La Roche, R., apoplexy and disease of heart, 222.
Larynx, syphilitic ulceration of, 98; pseudo-membranous inflammation of, in an adult, 195; growths in, 262.
Levick, J. J., concretions in lungs, 31.
Liver, fatty degeneration of, 3; commencing cirrhosis of, 45; cancer of, 11, 153, 156, 275; abscess of, discharging through lung, 56; cysts of, coughed up, 35; metastatic abscess of, 139; tubercle of, 140, 263; cases of wounds of, 224.
Livezey, E., myeloid tumor of abdomen, 190; scirrhus of rectum, 236.
Lung, apoplexy of, with disease of mitral valve, 19; tubercle of, simulating cancer, 24; concretions in, 31; gray hepatization, 42; tubercular disease, with paraplegia, 146; casts expectorated from, 239, 245; cancer of, 275.

MEIGS, J. F., chronic duodenitis, 243.
Melanosis, case of general, 286.
Meningeal artery, dilatation of, 88.
Mesenteric glands, tubercle of, 73; cancer of, 83, 93, 271.
Mitchell, S. W., fatty degeneration of liver, 3; mace-shaped vesical calculus, 27; softening of cerebral convolutions, 37; cancer of mesenteric gland, 93; cancer of liver and lungs, 275.
Morehouse, G. R., hepatic abscess discharging through the lung, 56; tubercle in mesenteric glands, 73.
Morton, T. G., fistula of gall-bladder, 5; fracture of cervical vertebræ, 17; enlarged vermiform appendix, 25; cancer of several organs, 25; stran-

Digitized by Google

gulated hernia, 38; fibroid degeneration of kidneys, 62; meningitis, 68; diabetes, 72; fusion of kidney, 77.
Moss, Wm., fibroid stricture of pylorus, 165.

NATES, cystic tumor of, 15.
Neck, gunshot wound of, 221.

OMENTUM, cancer of, 43, 152; colloid cancer of, 65; iron wires in, 170; hypertrophy of, mistaken for diseased testicle, 187.
Ovary, abscess of, communicating with colon, 67.

PACKARD, JOHN H., eburnation of bone, 15; biliary calculi, 26; sensitive tumor of urethra, 40; insufficiency of tricuspid valves, 52; mammary tumor, 68; aneurism of aorta, 86; tubercles in cerebellum, 143; microscopic examinations of black vomit, 158; of nerve in tetanus, 159; iron wires in omentum, 170; cysts on intestines, 138; tubercle of pineal gland, 211; on pyogenic or suppurative diathesis, 247; cancer of bladder, 292.
Pancreas, cancer of, 8, 84, 109; induration of, 34; fatty degeneration of, 46.
Peritoneum, thickening of, 241.
Pineal gland, etc., tubercle in, 211.
Pleura, calcareous deposits on, 210; ossific deposit in, 267, 274.
Prostate gland, hypertrophy of, 291.
Pyæmia, cases and observations on, 247.

RECTUM, imperforate, 89; stricture of, 180; scirrhus of, 236.
Reed, Th. B., waxy kidney, 265.
Retina, syphilitic inflammation of, 70; serous apoplexy of, 92.
Richardson, T. G., deformity of cervix femoris, simulating fracture, 18.

SCAPULA, exostosis of, 34.
Scrotum, bony tumor of, 10, 300.
Shoulder-joint, obscure injury of, 14.
Smith, Albert H., lesions in enteric fever, 145; paraplegia, 146; ulceration of trachea, 195; apoplexy of brain, 196; transposition of rectum, 180; pseudo-membranous laryngitis, 160; hypertrophy of heart, 175; stricture of viscera, 207; aneurism of aorta, 208.
Smith, F. G., cysts of liver, 35; strangulation of intestine, 237.
Spine, fracture of, 290.
Spleen, enlargement of, 45; gangrene of, 147; ossification of artery of, 157; rupture of, 161.
Sternum, congenital fissure of, 203.
Stillé, induration of pancreas, 34; cysts expectorated, 37; enlargement of spleen, 45; abscess of ovary, 67.
Stomach, perforating ulcer of, 141, 190; post-mortem softening of, 12; acute idiopathic inflammation of, 97; fibroid stricture of pylorus, 165; cancer of pylorus, 169.
Subclavian artery, aneurism of, injected with iron, 177.
Supra-renal capsules, fatty degeneration of, 61; cancer of, 153; melanosis of, 286.

TESTICLE, fungus of, 13; cancer of, 45.
Thyroid gland, cysts of, 106.
Trachea, ulceration of, 160.
Typhoid fever, symptoms of perforation of intestine in, without lesion, 145.

ULNA, partial fractures of, 232.
Umbilical cord, twist of, 183.
Urethra, sensitive tumor of, 40.
Uterus, fibrous tumor of, removed during labor, 58; cancer of fundus and body perforating rectum, 101; cancer of, 200; severance of cervix during labor, 17, 235.

VISCERA, transposition of, 207.

WOODWARD, J. J., encephaloid tumor of thigh, 8; calcareous deposits on pleura, microscopic examination of cancerous breast, 269.

Digitized by Google

ERRATA.

Page 41, *passim*, for *Vogel* read *Paget.*
Page 42, line 7 from bottom, for *with history attached* read *without history.*
Page 133, line 3 from bottom, omit the word *are* before *clay colored.*
Page 180, line 5 from top, for *cephalic* read *cardiac.*
Page 183, line 7 from bottom, for *important* read *dangerous.*
Page 265, line 4 from bottom, for *it contains* read *urine contains.*
Page 266, line 3 from bottom, for *cast-off lime* read *carbonate of lime.*
Page 283, *passim*, for *penetrating ulcer* read *perforating ulcer.*

Digitized by Google

Digitized by Google

Digitized by Google